

BHAGANDARA- MULTIPLE FISTULAS IN ANO- MANAGEMENT BY KSHARASUTRA- A CASE STUDY

HarshithaKumari¹, Rasmi Johnson²

¹M.D. PhD (Ayu Physician), ²M.S. (Ayu), Senior Physician,
AyurVAID Hospitals, Bengaluru, Karnataka, India

Email: drharshitharai@gmail.com

Published online: January, 2018

© International Ayurvedic Medical Journal, India 2018

ABSTRACT

Anorectal diseases cause great discomfort making one's life miserable. Among them, *Bhagandara* is considered under the *Ashtamahagada* (Eight grave disorders) by Acharyas of Ayurveda. Fistula in ano at modern parlance is a common anorectal condition prevalent in the populations worldwide. Treatment for fistula is a big challenge in front of the medical as well as surgical world. *AcharyaCharaka* mentions the line of treatment for *Bhagandara* as *Virechana* (Therapeutic purgation) followed by *Paatana* (Excision) or if *Pakwa* (matured state), *Bhedana* by *Ksharasutra* application. *Ksharasutra* therapy is a radical cure in the treatment of *Bhagandara* without complications and recurrence. It is a simple, safe and sure shot treatment for anal fistula. *ApamargaKsharasutra* is well proven device in the management of fistula in ano.

Keywords: Fistula, Ayurveda, Ksharasutra, Bhagandara

INTRODUCTION

Anorectal diseases cause great discomfort making one's life miserable. *Arsha* (Piles), *Bhagandara* (Fistula in ano) and *Parikartika* (Fissure in ano) are the common anorectal diseases suffered by the population globally. Among them *Bhagandara* is considered under the *Ashtamahagada* (Eight grave disorders) by Acharyas of Ayurveda¹.

Bhagandara (fistula-in-ano) is one of the oldest diseases known to the medical science. The word *Bhagandara* is the combination of "*Bhaga*" and "*Darana*"². *Bhaga* word includes all the structures around the *Guda* (ano-rectal region) including *Yoni*

(vagina) in case of females and *Basti* (urinary bladder). The word *Daarana* means tear of surface associated with pain. When a *VedanaayuktaShopha* (painful swelling) is formed in *Gudapradesha* within the vicinity of two *angula* which becomes *Pakwa* and causes *Daarana* in *Bhaga*, *Guda* and *Vastipradesha*, then it is called as *Bhagandara*³.

Fistula in ano at modern parlance is a common anorectal condition prevalent in the populations worldwide and its prevalence is second highest after haemorrhoids⁴. A fistula in ano is a chronic abnormal communication, usually lined to some degree by

granulation tissue, which runs outwards from the anorectal lumen (the internal opening) to an external opening on the skin of the perineum or buttock (or rarely, in women, to the vagina)⁵. It is classified as "simple" or "complex". Simple fistula include low transsphincteric and intersphincteric fistulas that cross <30% of the external sphincter.⁶ The term complex fistula refers to any one of these conditions, that is, the track crosses >30% to 50% of the external sphincter, anterior in females, multiple tracks, recurrent, or the patient has preexisting incontinence, local irradiation, or Crohn's disease.⁷

There is no clear cut reference for the incidence and prevalence of Fistula in ano in our country. As per the data from AyurVAID hospital, Ramamurthy nagar, Bengaluru, 9% of patients who came to hospital in 2013-2014 had ano rectal diseases and among them 20% of the cases were *Bhagandara* (fistula in ano).

Treatment for Fistula is a big challenge in front of the medical as well as surgical world. Fistulotomy is suboptimal for deep trans-sphincteric or suprasphincteric fistulas because of the increased likelihood of fecal incontinence. Studies have shown a 36% to 50% incidence of fecal incontinence with stand-alone seton drainage. The end rectal/anal sliding advancement flap procedure is invasive and difficult to perform posteriorly. It may also lead to anal sepsis.⁸ Due to the involvement of the anal sphincter; the treatment of complex fistula poses a high risk for impairment of continence.⁹ Hence the problem still remains and is managed by specialized proctologists and general surgeons at different renowned medical centers incorporating new techniques to bring about complete treatment without complications.

A comprehensive approach through Ayurveda has been extended with definite and a positive outcome in treating *Bhagandara*. *Acharya Charaka* mentions the line of treatment for *Bhagandara* as *Virechana* (Therapeutic purgation) followed by *Paatana* (Excision) or if in *Pakwa* state, *Bhedana* by *Ksharasutra* application.¹⁰ *Ksharasutra* is one of the chief modality under *Kshaara karma* while *Shastra karma* and *Agni karma* are the subsidiary treatments.

The cases which are associated with vitiation of *Tridosha* and those which are due to *Abhigata* (External injury) are considered *Asadhya*.¹¹

The existing data on *Ksharasutra* reveals minimal loss of sphincter muscle and low reoccurrence rate by this modality of treatment¹². *Ksharasutra* has been proven as an effective and as a first choice of treatment. It is becoming universally acceptable day by day. The Indian Council of Medical Research (ICMR) has validated and is also under active consideration of the WHO for its globalisation¹³. This type of therapy is being considered as a minimal invasive Para surgical measure at global level.

CASE HISTORY

This is a case of 36 year old male, complaining of multiple boils near anus with on and off pus discharge from the boils since 15 yrs, condition aggravated since 1 month. History of fistulotomy was done twice in 1995 (18 yrs back) and 1998 (15 yrs back).

Per rectal examination revealed a complex fistula with external openings at 11'o clock, 12'o clock, 4'o clock, 5'o clock and 6'o clock position with internal openings in the anus. [Fig 1]

Sonofistulogram report before treatment- [Fig 2] showed evidence of two fistulous tracts, one tract located along the posterior aspect of the anal canal, with its internal opening around 6'o clock position in the middle third of the canal. From the intersphincteric phase it is extending into the deep post anal space and is bifurcating.

One branch is extending antero laterally to the left towards the external opening in the left gluteal region and another branch is extending anterolateral to the right towards the external opening in the right gluteal region.

Tract two is located along the anterior aspect of the anal canal. Its internal opening is around 12'o clock position in the lower third of the anal canal. From the intersphincteric phase it is passing through the superficial bundle of external sphincter in 12'o clock direction towards the external opening in the perineum. There is a caudal extension in the

intersphincteric space which is passing through the subcutaneous bundle of external sphincter in 12'o clock position.

Bhagandara mentioned in Ayurveda is compared to Fistula in ano. *Ksharasutra* is ultimate treatment for the cure of *Bhagandara*.

Preparation of Ksharasutra: *Ksharasutra* was prepared by standard method and guide lines laid down by ICMR, using *ApamargaKshara* (*Achyranthesaspera* Linn.), latex of *Snuhi* (*Euphorbia nerifolia*L.), *Haridra* (*Curcuma longa*Linn.) powder and Barbour thread No. 20.

Procedure: Patient was made to lie down in lithotomy position. Under aseptic precautions, after MAD, probing was done and *Ksharasutra* was tied in all the 5 fistula tracts one by one with moderate tightening. *Jatyadighrita* 5ml was pushed per rectally. Patient tolerated the procedure well. There was no bleeding per rectum. Dressing was done with *Jatyadighrita*. Thread change and dressing was done once a week till wound healed, i.e., 8 weeks.

Patient was prescribed with internal medications for 8 weeks like *Varanadikashaya* 15ml+ *Kaishoraguggulu* 1 Tablet two times before food, Tablet *Triphalaguggulu* and *GandhakaRasayana* 1 each three times daily after food, Tablet *Anuloma* 2 at bed time, *Guggulupanchphalachoorna* 1tsp with buttermilk morning and night after food. Externally *Jatyadighrita* was used for application on the perianal region. Sitz bath was advised once in 4hrs.

After 8 weeks patient underwent *Virechana karma* where *Snehapanawas* done with *Guggulutiktakaghrita* for 5 days in the form of *Arohanakrama* and *Virechana* with *Avipatthichoorna* 40gms.

Result: Patient had no pain, boils and pus discharge when examined after 8 weeks of *Ksharasutra*. Patient underwent 9 *Virechana Vegas* without complications.

Sonofistulogram report after 100 days of *Ksharasutra*- [Fig 3]

Fistulous tracts appeared obliterated. Part of the obliterated fistulous tract seen along the 5,7 and 12'o clock positions. Internal and external sphincter ap-

peared normal. No evidence of intersphincteric fluid collection, no evidence of para anal fluid collection, no evidence of para rectal fluid collection.

There is no report of incontinence or recurrence till date.

DISCUSSION

Ideal surgical treatment for anal fistula should aim to eradicate sepsis and promote healing of the tract, whilst preserving the sphincters and the mechanism of continence. However, the risk of potential damage to the anal sphincters and subsequent poor functional outcome remains in a large proportion of patients with high fistulae when the tract crosses more than 30%-50% of the external sphincter, and with recurrent or complex fistulae with multiple extensions or separate tracts.¹⁴

Virechana is the initial line of treatment mentioned by *Acharyas* for treating *Bhagandara*. In this case patient came with *Pakwa* state of the condition wherein he could not wait for the process of *Virechana*. Patient needed immediate *Bhedana* of tracked by *Ksharasutra* treatment. This gradually heals the fistulous tract with the integrity of sphincters with the anal canal. *Ksharasutra* is a scientifically validated treatment in the management of *Bhagandara*. Later, once the tracts got obliterated due to *Kshara*, *Virechana karma* was planned to remove the vitiated *Dosha* from the body and prevent the recurrence of the disease.

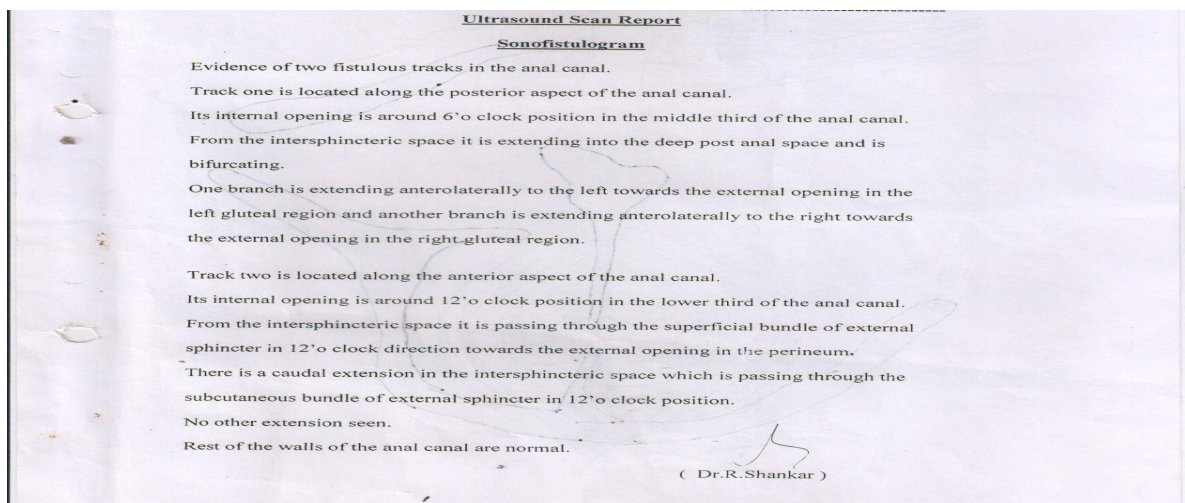
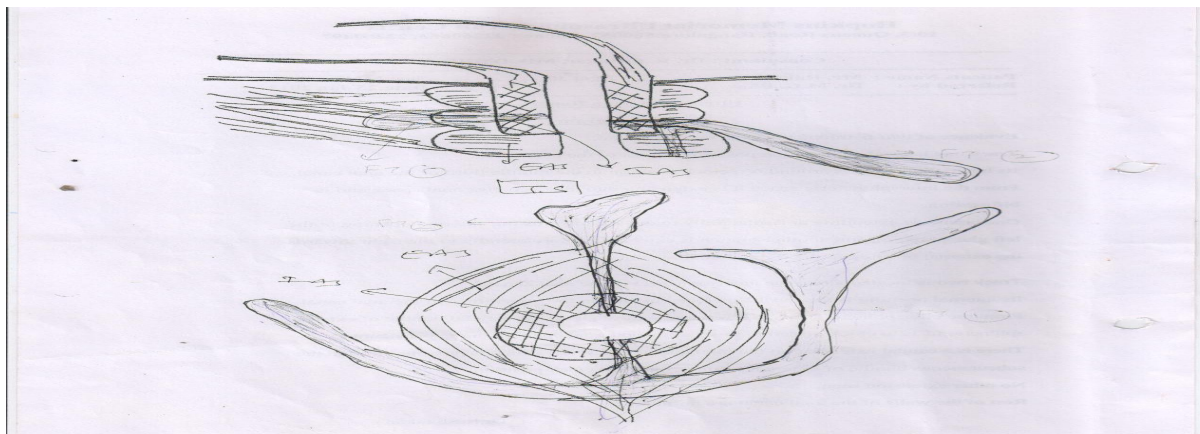
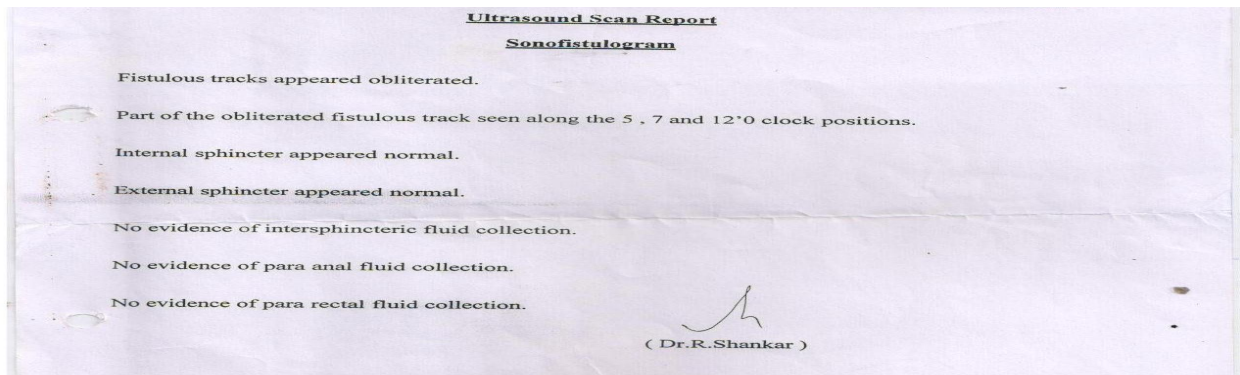
The adjuvant drugs were prescribed to achieve better outcome of the surgical management. *Triphala Guggulu* helps in the postoperative wound healing¹⁵. *GandhakaRasayanawas* found equally effective in preventing the secondary infection as the chances of secondary infection is high because there is presence of discharge from the tract till the thread is in situ. *AvagaahaSweda* (Sitz Bath) promoted relaxation of bladder sphincters in case of retention of urine and helped to pass the urine easily, particularly in painful situation.

CONCLUSION

Features of *Bhagandara* are at par with Fistula in ano explained in text books of surgery. Cases of fistula have been raised in few decades. Incidence of complex fistula with multiple tracts is rare comparatively and is complicated to give cure. *Ksharasutra* therapy is a radical cure in the treatment of *Bhagandara* without complications and recurrence. *Ksharasutra* therapy can be done in a small setup with a minimal equipment and instruments and moreover the patients remain ambulatory during the whole course of treatment, is an additional advantage in comparison to conventional therapy for fistula in ano. It is a simple, safe and sure shot treatment for anal fistula. *ApamargaKsharasutra* is a reliable therapy in the management of fistula in ano and has been standardized by the CCRAS.

REFERENCES

1. Acharya Sushruta, Sushruta Samhita; Dalhana, Nibandasangraha commentary; Edited by Jadavji Trikamji Acharya and Naarayan Ram Acharya; Chowkhambha Surabhaarati Prakaashana, Varanasi, 1st edition; Reprint 2008; Sutrasthana 33/4, pp.144.
2. Vaman Shivram Apte, Sanskrit Hindi Kosha; ISBN (Hardbound): 8120820983, 9788120820982, Year of Pub.: 2015, Edition: 12th reprint.
3. Acharya Sushruta, Sushruta Samhita; Dalhana, Nibandasangraha commentary; Edited by Jadavji Trikamji Acharya and Naarayan Ram Acharya; Chowkhambha Surabhaarati Prakaashana, Varanasi, 1st edition; Reprint 2008; Nidaanastana 4/3, pp. 280
4. Lobo SJ, Bhuyan C, Gupta SK, Dudhamal TS. A comparative clinical study of SnuhiKsheera Sutra, TilanalaKshara Sutra and Apamarga Kshara Sutra in Bhagandara (Fistula in Ano). Ayu. 2012 Jan; 33(1):85-91. doi: 10.4103/0974-8520.100319.
5. Bailey & Love's Short Practice of Surgery Edited by Norman S. Williams, Christopher J.K. Bulstrode, P. Ronan O'connell, Hodder Arnold publications UK, Twenty Fifth edition 2008, pp 1262
6. Dis Colon Rectum 2011; 54: 1465–1474.
7. ISRN Surgery Volume 2011 (2011), Article ID 636952, 5 pages
8. Williams, J. G., Farrands, P. A., Williams, A. B., Taylor, B. A., Lunniss, P. J., Sagar, P. M., Varma, J. S. and George, B. D. (2007), The Treatment of Anal Fistula: ACPGBI Position Statement. Colorectal Disease, 9: 18–50. doi: 10.1111/j.1463-1318.2007.01372.x
9. ISRN Surgery Volume 2011 (2011), Article ID 636952.
10. Acharya Agnivesha, Chakrapani, Ayurveda deepika commentary; Edited by Jadavji Trikamji Acharya; Chowkhambha Surabhaarati Prakaashana, Varanasi, 8th edition; 2004; Chikitsastana 12/97, pp. 313.
11. Acharya Sushruta, Sushruta Samhita; Dalhana, Nibandasangraha commentary; Edited by Jadavji Trikamji Acharya and Naarayan Ram Acharya; Chowkhambha Surabhaarati Prakaashana, Varanasi, 1st edition; Reprint 2008; Nidaanastana 4/13, pp. 287.
12. Dr. Hemanta Kumar Panigrahi, Mr. Rakesh Rani, Dr. M.M. Padhi, and Dr. (Prof) G.S. Lavekar, Clinical Evaluation of Kshara sutra Therapy in the management of Bhagandara (Fistula- in- Ano)- A prospective study AncSci Life. 2009 Jan-Mar; 28(3): 29–35.
13. Dwivedi Amarprakash P. ADR Ksharasutra kit: A breakthrough in the standardization of Ksharasutra. Int. J. Res. Ayurveda Pharm. 2013; 4(2):304-306.
14. <http://pib.nic.in/newsite/erelease>
15. Modern management of anal fistula World J Gastroenterol. Jan 7, 2015; 21(1): 12–20.



Source of Support: Nil

Conflict Of Interest: None Declared

How to cite this URL: Harshitha Kumari, Rasmi Johnson: Bhagandara-Multiple Fistula In Ano- Management By Ksharasutra. International Ayurvedic Medical Journal {online} 2018 {cited January, 2018} Available from: http://www.iamj.in/posts/images/upload/957_961.pdf