

SYMPTOMATIC RELIEF AND IMPROVED QUALITY OF LIFE IN A PATIENT WITH MITRAL VALVE PROLAPSE AND SEVERE MITRAL REGURGITATION FOLLOWING AYURVEDIC INTERVENTION- A CASE REPORT

¹K Nimisha Narendran, ²Mini V G

¹MD Scholar, Department of Kayachikitsa, Thiruvananthapuram

²MD (Ay). Professor, Dept. of Kayachikitsa Govt. Ayurveda College, Kannur

Corresponding Author: niminaren15@gmail.com

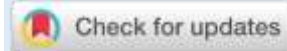
<https://doi.org/10.46607/iamj12p8032024>

(Published Online: March 2024)

Open Access

© International Ayurvedic Medical Journal, India 2024

Article Received: 08/02/2023 - Peer Reviewed: 05/03/2024 - Accepted for Publication: 20/03/2024.



ABSTRACT

Mitral Valve Prolapse (MVP) relates to unique mechanical abnormalities in the mitral valve apparatus and adjacent myocardium. MVP is a relatively common finding in the general population, and it is associated with ventricular tachycardia and sudden cardiac death. In severe cases, surgical intervention such as mitral valve replacement or repair is deemed appropriate. However, in this case report, we present a patient with MVP who experienced remarkable alleviation of symptoms and improved quality of life after undergoing Ayurvedic intervention. In the context of MVP, Ayurveda considers *Vata Pradhana Tridoshas* a potential underlying cause leading to structural and functional abnormalities in the heart. The intervention here typically involves the *Vatavyadhi Chikitsa Sutra*, *Swasam Chikitsa* and *Rasayana* to restore the *Amsa-amsa Dosha Avastha* imbalance. The treatment is tailored to the patient's *Prakriti* and manifested *Dosha-Dhatu* malfunctioning. This study highlights the potential benefits of Ayurvedic intervention in managing symptoms and enhancing the quality of life in patients with MVP with severe mitral regurgitation.

Key words: Mitral Valve Prolapse, Mitral Regurgitation, Ayurveda intervention, *Hrdroga Chikitsa*, quality of life (QOL)

INTRODUCTION

MVP is a relatively common cardiac valvular disorder, affecting about 1-3% of the population. Characteristics include superior displacement of mitral valve leaflet(s) during systole by at least 2 mm, myxomatous degeneration, and thickening of the leaflets. Clinical consequences of MVP include mitral regurgitation (MR), left ventricular (LV) dysfunction/congestive heart failure, infective endocarditis, atrial fibrillation, thromboembolism, and ventricular arrhythmias/sudden cardiac death.¹ MVP was found to be the third most common cause of sudden death (incidence, 12%), behind arrhythmogenic right ventricular cardiomyopathy (24%), and coronary artery disease (20%).¹

In Ayurveda, the term “*Hridroga*” is used to refer to diseases or disorders of structural and functional entity pertaining to the heart. *Hridaya* is derived from the *Prasada Pakam* (nutritive portion) of *Sonita* and *Kapha* and is a *Matruja Bhava* (derived from maternal tissues). According to *Brihatrayees*, any condition that produces disturbances in the *Hridaya* is called ‘*Hridroga*’. In general, improper food and regimens i.e *Virudha Ahara* and *Vihara* (incompatible combinations of diet and lifestyle), *Rasa* and *Rakta Dhatu Dushti* (vitiation of *Rasa* and *Rakta dhatu*), *Agnimandya* (vitiation of Biofire) and *Agantu* (external) factors are the causative factors for initiation of a pathology deviating the normal physiology.

The first most common symptoms evident are fatigue, shortness of breath and palpitations later produces chest pain. From Ayurveda point of view, *Vyana Vata* which controls the movements of the heart is primarily deranged. Considering the anatomy of the heart, pericardium can be attributed to the *medas*. *Mamsa dhatu* encompasses the musculature of the body including myocardium and endocardium from *Rasa* and *Rakta Dhatu*. Also, any of the eight basic elements *Rasa*, *Rakta*, *Mamsa*, *Ojas*, *Prana Vayu*, *Vyana-Vayu*, *Sadhaka Pitta* and *Avalambaka Kapha* when affected can disturb the function of the *Hridaya* and cause *Hridroga*. In a bird’s eye view, retention of vitiated *Rasa-Rakta* and their circulation in the endocardium may gradually develop valvular inflammation which in due course makes changes in the structural entities

embodied within the heart. If this state continues for a prolonged period, it further vitiates the adjacent dhatus i.e *Mamsa* and *Medas* (tissues derived from muscles and fat) exclusive in *Hridaya*. Due to *mamsa dushti*, valves become degenerated, valvular disorders manifest and regurgitation occurs. Treatment mainly aims at correcting the *Agnimandhya* by *Ama Pachana*, *Agni Deepanam* and *Vatanulomana*, correction of improper *Dhatu Parinama* (transformation of *Dhatus*) and correction of *Vyana Vata Dushti*. Considering the patients’ age, comorbidities and duly considering *Hridaya* as *Sadhyo Pranahara Marma* (takes away life abruptly), the administration of proper *Shodhana* (purificatory procedures) and *Panchakarma* procedures needs proper monitoring in an In-patient facility. Here in this case the patient approached the *Hridayam* (Cardiology) special OPD of the *Kayachikitsa* department, and treatment was advised on an OPD basis with regular follow-ups and monitoring of the symptoms.

5.a. CASE PRESENTATION

72-year-old male patient with no known comorbidities was apparently alright performing his daily activities until 2 years ago when he noticed palpitations insidious in onset, regular, daily, exertional, reduced on taking rest. No prominent neck veins, post palpitational diuresis/syncope initially. No associated chest pain, breathlessness and fatigue- when the symptoms started.

The patient presented with the following complaints with duration-

Table 1-Breathlessness and chest pain as presented by the patient.

After 3-4 months, he experienced giddiness at late night (dizzy spells) when he woke up to urinate and fell unconscious for a few seconds. He was taken to hospital the next day morning and an ECG was taken which revealed marked changes. A cardiac echo was done suggesting valvular heart disease. He was put on medications and advised to undergo valvuloplasty in a year.

5.b. PAST HISTORY- No known comorbidities. There is no history of fever with migratory large joint pain.

5.c. FAMILY HISTORY- Contributory since his mother passed away at the age of 35 years due to valvular heart disease.

5.d. Table 2: Personal history

6.a Table 3: Physical examination

6.b Table 4: Cardiovascular examination

7.a. DIAGNOSTIC TESTING: Transthoracic echocardiography (TTE), 2D echocardiography

8. PROGNOSIS (STAGING)-

Mitral valves prolapse is usually benign, but severe myxomatous degeneration of the valve can lead to MR. Carpentier's classification for mitral regurgitation- this classification provides an important categorization of mitral regurgitation, based on the etiology/mechanism of MV disease.²

9.a. Ayurvedic understanding of MVP

Table 5: Dasa Vidha and Astha Sthana Pareeksha

9.b. Flow chart 1: Nidana and Samprapti

9.c. SAMPRAPTI VIGHATANA-

The Samprapti justifies the role of Vata Shamana by means of Vatanulomama, Agni Deepanam, Amapachanam, Srotoshodhanam, Balyam and Rasayanam for the management of this condition.

9.d. AYURVEDA DIAGNOSIS-

This entity finds a close approximation with Vata Pradhana Tridoshaja Hridroga since there is a chronic degeneration of the valve apparatus caused by the Tridosha Dushti. The Kshaya Avastha i.e valve incompetence or valve prolapse is due to the virtue of aggravated Vata Dosha persisting within the heart.

9.e. Table 6: Therapeutic intervention

The treatments of internal medicine and external therapies need the fair assessment of all vitals, examination findings, ECG monitoring along with Ayurveda assessment of the prevailing status of Agni, Koshta and Srothas of the patient.

10. FOLLOW-UP AND OUTCOMES:

figure 1 & 2

The initial echocardiograph conducted on September 24, 2021, revealed several abnormalities. The report indicated mild left ventricular systolic dysfunction, thickening of both the anterior mitral leaflet (AML)

and posterior mitral leaflet (PML), with the PML prolapse being more prominent than the AML. Further findings included the presence of a ruptured chordae, mitral annular calcification, and severe mitral regurgitation with an anteriorly directed jet. Following a period of 12 months, after the intervention, a repeat echocardiography was performed on September 3, 2022. The results of this examination showed no definite regional wall motion abnormality, indicating an improvement in the patient's cardiac function. The left ventricular systolic function was reported to be satisfactory, although the PML remained thickened, it was noted to be prolapsed. Initially, the patient had been advised to undergo valvuloplasty, however, due to the positive changes observed after the intervention, valvuloplasty denied. Importantly, the patient experienced significant improvement in symptoms, and an overall enhancement in their quality of life was noticed. Overall, the intervention implemented in this case led to positive outcomes, including an improvement in left ventricular function and symptomatic relief for the patient. The findings suggest that the intervention was successful in managing the cardiac abnormalities present and resulted in a notable enhancement in the patient's well-being.

DISCUSSION

In Ayurveda, Hridroga is regarded as a disorder characterized by the impairment of structural and functions of the heart and its associated vessels. Prolonged exposure to causative factors leads to the accumulation of Ama in the subtle channels-Sookshma Srothas, resulting in the obstruction of these channels, particularly those leading to the heart. This obstruction manifests as a disorder in the form of incompetent valves. The condition is further aggravated by influential factors such as age and family history. To disrupt the progression of such a condition, prolonged administration of medicines is necessary, accompanied by diligent monitoring of symptoms. To assess the effectiveness of the treatment, both a pretreatment and post-treatment 2D echo were conducted. Though the echo tests revealed subtle dimensional changes, the noteworthy improvement lay in its significant alleviation of

symptoms. Breathlessness improved from NYHA 4 to 1 and angina got nearly nil. Furthermore, following the initial purification—*Shodhana* procedure, *Rasayana* and *Brimhana* treatments are administered. These measures aim to reinforce the prevention of further valve prolapse and enhance the strength of the incompetent valves. It is important to recognize that this treatment approach combines Ayurvedic principles with meticulous observation, systemic examination, and care, emphasizing the restoration of optimal heart functions and alleviation of distressing symptoms.

CONCLUSION

This case report of Ayurvedic management of MVP with severe mitral regurgitation has demonstrated its potential to reduce symptoms, as evidenced by the improvements in symptoms. However, it is important to acknowledge the limitations and scope of the Ayurvedic treatment for heart diseases. Severe cases of mitral valve prolapse with significant regurgitation may still require medical or surgical interventions for optimal outcomes. Furthermore, while individual cases may showcase symptomatic relief and improved QOL, the

effectiveness of Ayurvedic management may vary among individuals. It is crucial to have a personalized approach and work with qualified Ayurvedic practitioners who can tailor the treatment plan as per patient's condition.

REFERENCES

1. Miller, M.A. *et al.* (2018) 'Arrhythmic mitral valve prolapses', *Journal of the American College of Cardiology*, 72(23), pp. 2904–2914. doi: 10.1016/j.jacc.2018.09.048.
2. Grayburn, P.A. and Thomas, J.D. (2021) 'Basic principles of the echocardiographic evaluation of mitral regurgitation', *JACC: Cardiovascular Imaging*, 14(4), pp. 843–853. doi: 10.1016/j.jcmg.2020.06.049.

Source of Support: Nil

Conflict of Interest: None Declared

How to cite this URL: K Nimisha Narendran & mini-V G: Symptomatic relief and improved Quality of Life in a patient with Mitral Valve Prolapse and Severe Mitral Regurgitation following Ayurvedic intervention- A case report. *International Ayurvedic Medical Journal* {online} 2024 {cited March 2024} Available from: http://www.iamj.in/posts/images/upload/265_268.pdf