

ANALYSIS OF *UDAK VAHA SROTO VIDDA LAKSHAN* WITH SPECIAL REFERENCE TO *KLOMA* & ACUTE PANCREATITIS DUE TO BLUNT ABDOMINAL INJURY

Piyush Verma

(MD-Rachana Sharir Scholar), Himaliya Ayurvedic Medical College & Hospital, Dehradun, Uttarkhand, India

Email: drpiyush623@gmail.com

Published online: July, 2018

© International Ayurvedic Medical Journal, India 2018

ABSTRACT

Kloma is a controversial subject in Ayurveda and it has been referred to as the *moola* (base) of *udak vaha srotas*. *Acharyas* has described the *viddha lakshana* (traumatic effects) of these vital organs, in which the traumatic effect of *udakvaha srotas* is *pipasa* (thirst) and *maran* (death). In modern era if we compare the traumatic effects of *udak vaha srotas* to Acute Pancreatitis due to trauma / injury to pancreas, then both the symptoms of *udak vaha sroto viddha* comes under this Pancreatic trauma causing Acute Pancreatitis.

Keywords: *Udak vaha Srotas, Kloma, Pancreas, kosta*

INTRODUCTION

There are eleven pairs of *Srotas* mentioned in *Susruta Samhita*^{1,2,3} in which *Udak vaha Srotas* is one of them. *Srotas* has been called the structure or channels which are different from *Sira* and *Dhamini* and having a *Moola* (initial origin) and dispersing in body, doing functions of transport of vital elements^{1,2,3}. *Acharya Susruta* has mentioned *Udak vaha Srotas* at second number next to *Prana Waha* having *Moolas* namely- *Talu* and *Kloma*^{1,2,3}. Both *Talu* and *Kloma* are controversial subjects in Ayurveda. *Acharya Charaka* has also mentioned *Talu* and *Kloma* as *Udak vaha Srotas Moola*⁴. Although in *Susruta Samhita*, *Kloma* has not been mentioned in *Kostha* but in *Charaka Samhita*⁵ and *Astanga Hridaya*⁶ has mentioned *Kloma* in *Kosthaanga*.

Kloma is a *Avyava*^{7,8} that lies superior to *nabhi* (navel) and situated in *Amashaya*⁹ has been related to many structures by different authors in ayurvedic texts such as *Gala* (throat), *Kanthnadi* (trachea), *Apstambha* (bronchus), *dakshina fuffusa* (right lung), *Pittashaya* (gall bladder), *Agniyashaya* (pancreas)¹⁰ etc. *Acharya Susruta* has mentioned about *Kloma* that it is situated in the right side of *Hridaya* (heart) with *Yakrit* (liver) and on the other hand that is on left side of *Hridaya- Fuffusa* (lungs) and *Pleeha* (spleen) are there¹¹. He has also mentioned name of *Kloma* in context to *Sandhis* (joints) as the number of *Sandhis* related to *Hridaya* (heart) & *Kloma* to be 18 in number and the type of *Sandhi* is *Mandala* which is related to *Kantha* (neck), *Hridaya* (heart) & *Kloma*¹². In modern anatomy it is evident that liver

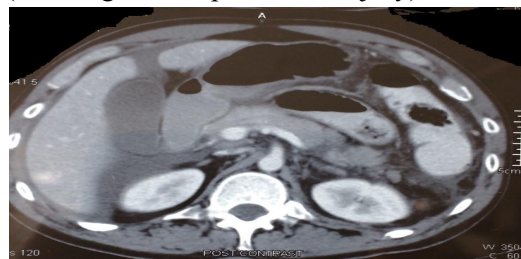
and head of pancreas is on right side with respect to heart. This Pancreas is an elongated J-shaped organ in abdominal cavity which is a accessory digestive gland, lies retroperitoneally, overlying & transversely crossing the bodies of the L1 and L2 vertebra (at the level of the transpyloric plane) on the posterior abdominal wall. It lies posterior to the stomach between the duodenum on the right side and the spleen on the left side. The transverse mesocolon attaches to its anterior margin. In adults, the pancreas is about 15-20 cms long, 1.0-1.5 cms thick and weighs approximately 90-100 g. The main duct of Wirsung traverses the entire length of the gland. The superior pancreaticoduodenal artery from the superior mesenteric artery runs in the concave contour of the second part of the duodenum to supply the head of the pancreas. The pancreatic branches of the splenic artery supply the neck, body and tail of pancreas. The body and neck of the pancreas drain into the splenic vein, whereas the head drains into the superior mesenteric and portal veins. The lymphatic drainage of the pancreas is via the splenic, celiac and superior mesenteric lymph nodes^{13,14}. The proximity of many larger vessels such as inferior vena cava (IVC), portal vein and abdominal aorta makes the pancreas difficult to manage because of risk of exsanguinating hemorrhage, which is a frequent death in patients with pancreatic injury.

1. Exocrine-pancreatic juice from the acinar cells that enters the duodenum through the main accessory pancreatic duct.
2. Endocrine-insulin and glucagon secretions from islets of Langerhans.

Acharya Susruta has mentioned *Udak vaha Sroto viddha* symptoms as *Pipasa* (thirst) and *Maran* (death)¹. There are several type of abdominal injuries causing fatal outcomes. One of them is Pancreatic Injury. Symptoms mimicking the *Udak vaha Sroto viddha Lakshan* are present in Pancreatic Injury. The pancreas is relatively uncommon organ to be injured in trauma, occurring in less than 2% of blunt trauma cases, and this injury is associated with considerably high morbidity and mortality in cases of

delayed diagnosis, incorrect classification, or delays in treatment. Mortality of pancreatic injury ranges from 9% to 34% however, only 5% of the pancreatic injuries are directly related to fatal outcome. Injuries to the pancreas most commonly result from penetrating trauma caused by gunshot or stab wounds and occur in approximately 20%-30% of all patients with penetrating trauma. The penetrating injury caused by firearms results in highest frequency of pancreatic trauma. The relatively protected retroperitoneal location of the pancreas protects it from most instances of blunt abdominal trauma. Blunt trauma to the pancreas is, in most instances caused by a sudden localized force to the upper abdomen that compresses the pancreas against the vertebral column (eg., steering wheel injury in a motor vehicle accident in adults and from bicycle handlebar injury or direct blow from a kick or fall in children). Blunt pancreatic injury is more common in children and young adults because they have a thinner or absent mantle of protective fat, which surrounds in older adults¹⁵.

Following is a CT abdomen image showing pancreatic transaction due to a blunt abdominal trauma. CT image shows transaction of body of pancreas (AAST-grade IV pancreatic injury).



DISCUSSION

Patients with pancreatic trauma present usually with features of Acute Pancreatitis. Patient experiences abdominal distension due to collections and severe pain which radiates to back. Pancreatitis due to Pancreatic injury like other causes of Acute Pancreatitis also has significant third space fluid loss, due to which patient feels dehydrated and lots of fluid correction has to be done to improve hydration status. Abdominal distension progressively increases as

pancreatic collection accumulates with respiratory distress due to Pleural Effusion. Untreated and misdiagnosed cases as said earlier carries high mortality risks and can also results in death. In Ayurvedic texts the *Udak vaha Sroto viddha Lakshan* (symptoms) which is *Pipasa* (thirst) and *Maran* (death) also occurs in cases of pancreatic injury. Although in modern era as life support systems have become advanced the death or mortality rate is significantly reduced which would be high in classic times but the symptom of thirst frequently occurs in these kinds of patients. As authors describe *Talu* as an area near buccal cavity, the second *Moola* lie *Kloma* has greater resemblance with pancreas in terms of its inflammatory sequel due to injury.

CONCLUSION

Symptoms of *Udak vaha Sroto viddha Lakshana* (*Pipasa & Maran*) resemble to the clinical features of Acute Pancreatitis caused due to trauma to pancreas. Thus *Kloma* can be compared to pancreas.

REFERENCES

1. Ambika Dutt Shastri, *Ayurved-tatwa-sandipika* commentary on *Susruta Samhita* part 1- *Shaarir Sthan*, *Chaukhamba Sanskrit Sansthan*, Varanasi; chapter 9: page 96-97.
2. Dr. Kewal Krishna Thakral, *Susruta Samhita* with commentary of Dalhan and Gayadas part 2, *Chaukhamba Orientalia* Varanasi; *Shaarir sthan*; chapter 9: page 136-139.
3. Ghanekar Bhaskar Govind, *Ayurvedarahasyadipika* Hindi *Vyakhaya Samullisita* on *Susruta Samhita-Sharir Sthan*; Meharchand Lakshmandas Publications, reprint december 2013; chapter 9: page 240-241.
4. Pandit Kashi Nath Shastri, Dr. Gorakhnath Chaturvedi, introduction by Vaidya Samrat Sri Satya Narayan Shastri, *Vidyotini tika*, Chaukhamba Bharti academy Varanasi, *Caraka Samhita- Viman Sthan*; chapter 5: page 706-715.
5. Pandit Kashi Nath Shastri, Dr. Gorakhnath Chaturvedi, introduction by Vaidya Samrat Sri Satya Narayan Shastri, *Vidyotini tika*, Chaukhamba Bharti academy Varanasi, *Caraka Samhita, Shaarir sthan*; chapter 7: page 913.
6. Kaviraj Attridev Gupta, *Vidyotini* hindi commentary, *Astanga Hridayam*, edition 2012, *Shaarir sthan*; chapter 3: page 251.
7. Agnivesh, Caraka, Drudbala; *Caraka Samhita*; commentary of Charapanidutta-*Ayurveddipika*; edited by Yadavji Tikramjee Acharya; Chaukhamba Subharti Prakashan, Varansi-2011; page 358.
8. Gaurav Soni; A conceptual Study on *Rachnatamaka* position of *Avyava* (organs) as per ayurvedic texts; *International Journal of Ayurveda & Alternative Medicine*, Vol- 3, issue-3, may-june-2015; page 154-158.
9. Susruta, *Susruta Samhita*, commentary of Dalhana-*Nibandhasangraha*, commentary of Gayadas-*Nyayachandrika*; edited by Yadavji Tikramjee Acharya; Chaukhamba Subharti Prakashan, Varanasi-2011; page 374.
10. Vilas M. Nanal; *The Organ Kloma*; *Ancient Science of Life*; vol IX, no-2, October-1989; page 61-65.
11. Susruta, *Susruta Samhita*, commentary of Dalhana-*Nibandhasangraha*, commentary of Gayadas-*Nyayachandrika*; edited by Yadavji Tikramjee Acharya; Chaukhamba Subharti Prakashan, Varanasi-2011; page 261.
12. Ambika Dutt Shastri, *Ayurved-tatwa-sandipika* commentary on *Susruta Samhita* part 1- *Shaarir Sthan*, *Chaukhamba Sanskrit Sansthan*, Varanasi; chapter 5 : page 61-62.
13. Keith L Moore, Authur F, Dalley, Anne M. R Agur; *Moore Clinically Oriented Anatomy*; seventh edition; Wolters Kluwer (india), New Delhi; page 265-268.
14. Richard L. Drake, A. Wayne Vogt, Adam W. M. Mitchell, *Gray's Anatomy for Students*; second edition (international); Elsevier Publications; page 320-322.
15. Uma Debi, Ravinder Kaur, Kaushal Kishore Prasad, Saroj Kant Sinha, Anindita Sinha, Kartar Singh; *Panceatic Trauma: A Consice Review*; *World Journal of Gastroenterology*; December 21 2013, vol- 19, issue- 47; page 9003-9011.

Source of Support: Nil

Conflict Of Interest: None Declared

How to cite this URL: Piyush Verma: Analysis Of Udak Vaha Sroto Viddha Lakshan With Special Reference To Kloma & Acute Pancreatitis Due To Blunt Abdominal Injury. *International Ayurvedic Medical Journal* {online} 2018 {cited July, 2018} Available from: http://www.iamj.in/posts/images/upload/1238_1240.pdf