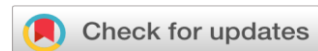

**MANAGEMENT OF PARIKARTIKA W.S.R. TO FISSURE IN ANO BY APPLICATION OF KALANUSARYADI TAILA PICHU -A CASE STUDY****Pandey Nilima¹, Singh Balendra², Nirmal Satrupa³, Bara Sunidhi⁴**¹ PG Scholar Shalya Tantra Department, Govt. Ayurveda College Raipur C.G., India² Professor and HOD, Shalya Tantra Department, Govt. Ayurveda College Raipur C.G., India.³ Lecturer Shalya Tantra Department, Govt. Ayurveda College Raipur C.G., India.⁴ PG Scholar Shalya Tantra Department, Govt. Ayurveda College Raipur C.G., India**Corresponding Author:** pandeynilima91@gmail.com<https://doi.org/10.46607/iamj14p8062024>**(Published Online: September 2024)****Open Access**

© International Ayurvedic Medical Journal, India 2024

Article Received: 20/08/2024 - **Peer Reviewed:** 17/09/2024 - **Accepted for Publication:** 24/09/2024.**ABSTRACT**

Ayurveda is a natural science which not only cures disease but also prevents disease. *Ayurveda* is a beautiful path to lead a disease-free life. Nowadays due to sedentary lifestyle many diseases affect mankind, among them *Parikartika* is the most common one. In *Ayurveda Aushadhachikitsa* of *Parikartika* includes *Deepniya*, *Pachniya*, *Ropaniya*, *Vatanulomak*, *Virechaka Aushadha* and local therapies include *Matrabasti*, *Snehabasti*, *Pichudharan*, *Tail Puran*, *Lepa*, *Madhura Kashaya Dravya Siddha Basti*. *Pichudharana* works on the basis of cellular absorption and is an easier method for adoption. **CONCLUSION** : A case with the features of *Parikartika* was selected from OPD, Govt Ayurveda College and Hospital, Raipur, C.G. for case study and *Kalanusaryadi Taila Pichudharan* was done for 1 month. Assessment was done based on features like pain, burning sensation, bleeding, sphincter tone. Significant improvement was observed after treatment.

Keywords: *Parikartika*, *Kalanusaryadi Taila*, , Fissure in ano.

INTRODUCTION

Parikartika is described by *Acharya Charaka* in *Siddhi Sthana* chapter 7 in *Virechan Vyapad* ¹ *Acharya Sushruta* has described it in *Bastivyapad* ² and *Acharya Kashyap* has described *Parikartika* in *Khilsthan* in the complication of *Garbhini*. ³ *Parikartika* is made up of two words *Pari* and *Kartika*. *Pari* is used as a prefix meaning all around and *Kartika* derived from *Sanskrit* word *Krita* meaning *Kartanam* or cutting pain. Thus *Parikartika* means cutting sensation or pain all around the anus region. ⁴ According to modern science fissure in ano is described as a longitudinal tear in the thin, moist passage of hard stools during a bowel movement. Anal fissures typically cause pain and bleeding with bowel movement especially a fresh streak of blood along with the stool is typically found in fissure in ano. One can experience spasm in the ring of muscle at the end of anus (anal sphincter) .⁵ For acute fissures, conservative treatments include oral medications for pain relief, laxatives, and analgesic ointments. For chronic fissures, procedures such as anal dilatation, posterior or lateral sphincterectomy, fissurectomy, excision of anal ulcers, or anal advancement flaps can be performed. *Piccha Basti*, combined with *Yasthimadhu*, black sesame pastes, honey, and *Ghrita*, alleviates *Parikartika*. Numerous techniques have been explored, but there is always a need for cost-effective and patient-friendly options for managing anal fissures. *Pichu* is safe, ideal, convenient, and cost-effective, as described in

Charaka Siddhi Sthana, Chapter 5. *Pichu* is a thick swab or cotton pad soaked in medicated ghee or oil, placed at the treatment site. It stays in place longer, ensuring better absorption and effectiveness of the medication.

CASE REPORT

A 42-year-old female, housewife presented with complaints of severe pain in the anal region during and after defecation associated with burning sensation, constipation, stools, streaked with blood since a week at *Shalya Tantra* OPD, Govt *Ayurveda* College Raipur C.G. for better management. The patient had a history of constipation and is not a known case of Diabetes Mellitus, Hypertension or underwent any surgery. Patient consent was taken.

On physical examination pulse -78/min, Blood pressure -120/80 mmHg. All the laboratory investigations done were within normal limits.

Systemic examination was done and clinically no abnormalities were detected.

Local Examination

Inspection- Acute on chronic Fissure in ano at 6 o'clock position

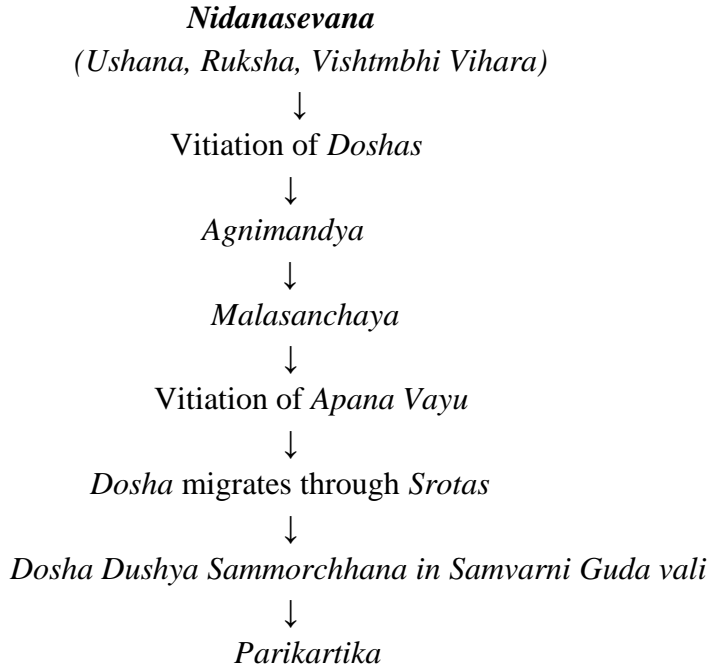
Palpation- Tenderness present over the fissure area.

Nidana

Ahara- *Ruksha Ahara*, *Katu Pradhana Ahara Sevana*.

Vihara- Prolong standing

Samprapti Chakra



Diagnosis: *Parikartika* (Acute Fissure in Ano)

Materials And Methods

Kalanusaryadi Taila preparation

Moorchita Tila Taila cooked with *Kalanusaryadi Kashaya* and *Kalka* on mild flame untill the *Paka Lakshana* was obtained.

Treatment was planned as:

Sthanika Chikitsa and Pathya

Sthanik Chikitsa: *Kalanusaryadi Taila Pichu* twice daily for 1 month.

Pathya : Green leafy vegetables like Spinach rich fibrous diet, guavava, papaya, beet roots, almond, cashewnuts , *Takra*. Old *Rakta Shali*, *Shasti rice* , *Yava*, *Kulatha*, *Moong Dal* also advised.

Assessment Criteria

1 Pain

Pain on Vas- As the sufferer himself expressed the pain in his own terms, this was graded , starting from mild to severe as per the Visual Analogue Scale (VAS).

Symptoms	Grade
No pain/ Absence of pain	0
Mild (Pain detected between 1 to 3 marks on scale- pain that can be easily ignored, pain at the time of defecation.)	1
Moderate (Pain detected between 4 to 6 marks on scale- pain that cannot be ignored and persists upto 2 hrs.)	2
Severe (Pain detected between 7 to 10 marks on scale- pain that cannot be ignored interferes with daily routine, needs treatment , time to time hot sitz bath, continuous pain which remains for whole day after defecation).	3

2. Constipation

No Constipation (passing normal stool daily)	0
Mild (passing hard stool daily)	1
Moderate (passing hard stool once in 2 days)	2
Severe (passing hard stool once in more than 3 days)	3

3. Bleeding

No bleeding	0
Mild (blood streak with defecation)	1
Moderate (drop wise bleeding during defecation)	2
Severe (drop wise bleeding during and after defecation)	3

4. Sphincter tone

No spasm	0
Mild (anal verge constricted)	1
Moderate (anal verge constricted with bleeding during separation of buttock .)	2
Severe (anal verge constricted with bleeding during separation of buttock and patient unable to pass stool due to fear of pain.)	3

The following observations were obtained by application of *Kalanusaryadi Taila Pichu and Panchsakara churna 5 gm orally at night with lukewarm water.*

Day	Pain	Bleeding	Constipation	Sphincter tone
1	3	1	2	3
7	2	0	1	2
14	1	0	0	1
21	0	0	0	0
28	0	0	0	0

OBSERVATIONS AND RESULTS

Clinical examination of the patient revealed regression of symptoms with treatment day by day. On 14 th day there was mild pain with the absence of bleeding and no constipation .On the last day of treatment patient had no symptoms.

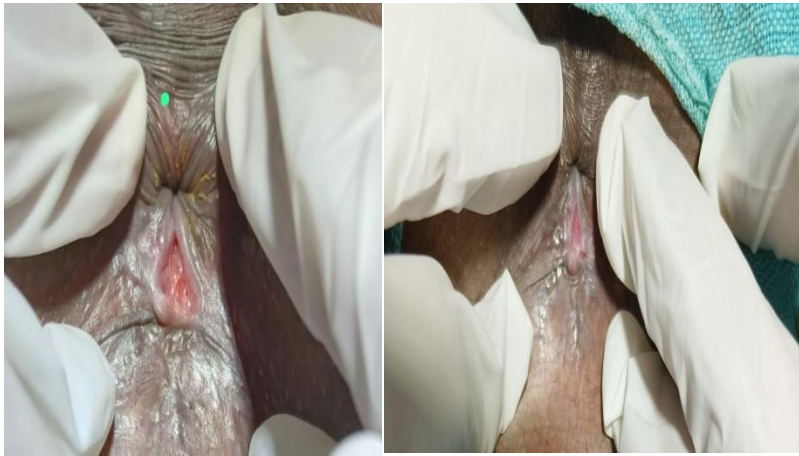
DISCUSSION

Patient got relieved from the symptoms of fissure in ano with *Kalanusaryadi Taila Pichu*.

Probable mode of action

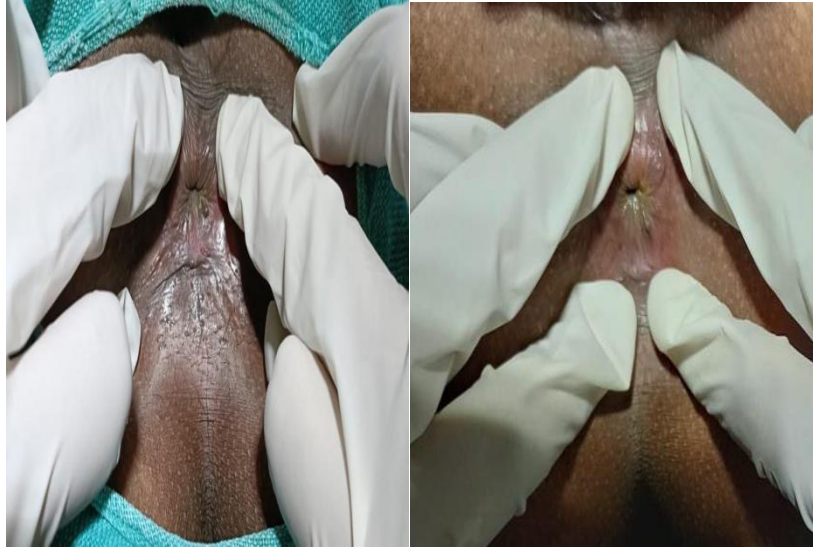S. NO.	Drug name	Botanical name	Useful Part	Properties
1	Tagar	Valeriana Wallichii	Root	Vedanasthapaka, Vranaropaka
2.	Agaru	Aquillaria Agallocha	Stem	Vedanasthapaka, Shothara
3.	Ela	Elataria Cardamomum	Seeds	Arshoghana, Vatanulomaka, Dahaprashmana, Vedanashamaka
4.	Jati	Jasminum Officinale	Leaves	Vransodhana, Vranaropaka
5.	Chandan	Santalum Album	Stem	Shothahara, Dahashamaka
6.	Padmakastha	Prunus Cerasoides	Bark	Vedanasthapana
7.	Manahsheela	Realgar	Shuddha	Vranasodhana, Vranaropana
8.	Daruharidra	Berberis Aristata	Root	Vedanasthapaka, Vranshodhaks, Vranaropaka
9.	Giloy	Tinospora Cordifolia	Stem	Vedanasthapaka
10.	Sasyaka	Blue vitriol (CuSO4)	Shuddha	Vranashodhaka, Vranaropaka
11.	Tila Taila	Sesamum Indicum	Seed Oil	Vedanasthapana, Vranashodhana, Vranaropana

Kalanusaryadi taila has good Vranropak and Vedanashamak properties . *Kalanusaryadi taila* has been mentioned in *Sushrutchikitsa 2/68*. *Kalanusaryadi Taila* has Vednashamak, Vranshodak and Vranropak properties which will help in rapid healing of Vran and also help to relief the pain in fissure in ano.



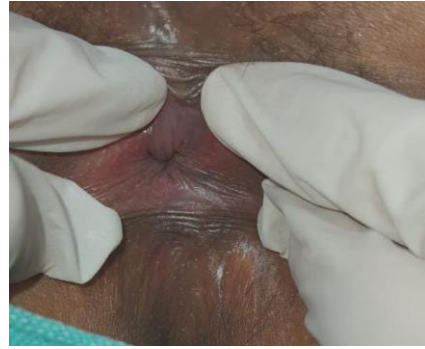1st day

7th day



14 th day

21 st day



28 th day

REFERENCES

1. Shastri Kasinatha Charak Samhita, Siddhi sthana,Chaukambha Bharati Academy Varanasi reprint edition 2012-page no.1028.
2. Shastri Ambikadutta Sushruta Samhita, Chikitsa sthana, Chaukambha Sanskrit Sansthan Varanasi reprint edition 2012-page no194.
3. Sharma Hemaraja Kashyapa Samhita, Khil sthana, Chaukambha Sanskrit Sansthan Varanasi reprint edition 2022-page no.455.
4. Sabdarthchintamanikosa, part 3, page no.64.
5. Das S, A Concise Textbook of Surgery Published by Dr. S. Das. 13 Old Mayors Court, Kolkatta,reprint edition 2016, page no.1083.
6. Das S, A Concise Textbook of Surgery Published by Dr. S. Das. 13 Old Mayors Court, Kolkatta,reprint edition 2016, page no.1083.
7. Shastri Ambikadutta Sushruta Samhita, chikitsa sthana,Chaukambha Sanskrit Sansthan Varanasi reprint edition 2018 page no 187.

Source of Support: Nil

Conflict of Interest: None Declared

How to cite this URL: Pandey Nilima et al: Management of parikartika w.s.r. to fissure in ano by application of kalanusaryadi taila pichu -a case study. International Ayurvedic Medical Journal {online} 2024 {cited September 2024} Available from: http://www.iamj.in/posts/images/upload/589_594.pdf