

**AYURVEDIC MANAGEMENT OF ORAL HERPES W.S.R. TO PITHAJA MUKHA-PAKA - A SINGLE CASE REPORT**

[Premcy C. R](#)<sup>1</sup>, [Ahalya S](#)<sup>2</sup>, [S M Pasha](#)<sup>3</sup>

<sup>1</sup>PG scholar, Dept. of PG Studies in Shalaky Tantra, G.A.M.C, Bengaluru, Karnataka, India

<sup>2</sup>Principal, G.A.M.C, Bengaluru, Karnataka, India

<sup>3</sup>H.O.D. & Associate professor, Dept. of PG Studies in Shalaky Tantra, G.A.M.C, Bengaluru, Karnataka, India

Corresponding Author: [premcy85@gmail.com](mailto:premcy85@gmail.com)

<https://doi.org/10.46607/iamj2609032021>

(Published online: March 2021)

Open Access

© International Ayurvedic Medical Journal, India 2021

Article Received: 19/02/2021 - Peer Reviewed: 26/02/2021 - Accepted for Publication: 04/03/2021

**ABSTRACT**

**Introduction:** Herpes simplex is a viral infection caused by the herpes simplex virus. Oral herpes causes the group of blisters called cold sores or fever blisters over the face or mouth. These are having severe burning sensation which causes the dysphagia and difficulty in speaking. It is associated with fever. There will be ulcer formation by the rupture of blisters. Oral herpes can be correlated to *Pithaja mukhapaka*. This is a case report of 41 years old male who complained of severe burning ulcers on hard palate since 1 month. **Materials and Methods:** The subject who approached *Shalaky Tantra* OPD of GAMC, with symptoms of burning ulcers over the palate was thoroughly examined and treatment was planned based on *Chikitsa sutra* of *Pithaja mukhapaka*. **Result:** The subject had shown good improvement both subjectively and objectively. **Discussion:** *Pithaja mukhapaka* is a *Sarvasara Mukharoga* with *Daha, Oshayuktha Vrana*. There for the treatment is focused on pacifying *Pitha*.

**Keywords:** *Pithaja mukhapaka*, herpes simplex, *Guluchyadi kashayam*.

**INTRODUCTION**

Herpes simplex viruses are the members of Herpes Viridae family. Among them the Herpes simplex is a viral infection caused by the herpes simplex virus. Infections are categorized based on the part of the body infected.<sup>1</sup> Oral herpes involves the region of face or

mouth. It causes the formation of group of blisters often called as cold sores or fever blisters. These causes sore throat. There will be formation of ulcers by the rupture of blisters. It will cause severe burning sensation, dysphagia and difficulty in speaking. Genital

herpes, often simply known as herpes, may have minimal symptoms or form blisters that break open and result in small ulcers<sup>2</sup>. Before the appearance of blisters, there will be tingling or shooting pain. Based on the symptoms mentioned in *ayurvedic* classics, Oral herpes can be correlated to *Pithaja Mukhapaka* which is a *Sarvasra mukharoga*.

### Materials and Methods

**Case Report:** basic information of the patient, Age: 41 years, Sex: male, Religion: Hindu, Occupation: clerk

Chief complaints: 2 ulcers in the right side of hard palate associated with severe burning sensation for 1 month. He was suffering from fever during the first week. History of present illness: The patient complaint of ulcers in the right side of hard palate for one month. He was suffering from fever during the first week. After that he started burning pain in the palate. While observing the painful area of palate he noticed hyperemia which turns into painful blisters within two days. After two days the blisters breaks opened and turned to ulcers. The ulcers were associated with severe burning sensation. The burning sensation was increased during speaking and swallowing. On consulting a general physician, he was diagnosed to have Oral Herpes Simplex and underwent treatment for the same. But he didn't get any relief. Past history: nothing significant, Family history: nothing significant, Personal history: bowel –regular, Appetite-good, Micturition- 5-6 times/day, Sleep –good, Examination: nadi- 78/min, Mutra -5-6 times/day, Mala –regular, Jihwa –Liptha, Shabda –Prakrutha, Sparsha – Ushna, Druk –Prakrutha, Akruthi –Madhyama, Prakruthi – Pitha Kapha, Vitals – normal, B.P - 124/80mm of H g., RS – on auscultation no murmur sound detected, CVS-NAD, CNS-NAD

Oral examination: as shown in table.1.

Investigations: shown in table number 2.

**Treatment:** Patient was given treatment for a period of 30 days. He had undergone *Sadyo Virechana* with *Avipathi churna* 30gm along with 20 ml of *Draksha Kashayam* as *Virechanopaga*, Further patient was administered orally with *Guduchyadi kashyam* 15ml (BD), *Shankha bhasma* (1pinch) BD, *Laghu suthasekar ras* (2 bd) as *Shamana aushadha*.

**Result:** After, a treatment period of 30 days patient was relieved from symptoms. As shown in the table

no: 3. There is relief from ulcer as shown in the Figure 1.a) before and b) after treatment.

### DISCUSSION

Here oral herpes is correlated with *Mukhapaka*. *Shodhana* followed by *Shamana* line of treatment are adopted here. *Shodhana* in the form of *Sadyo Virechana* with *Avipathi Churna* and *Draksha Kashaya* was given for *Pitha Virechana* on the first day. *Virechana* was given to reduce the speed of *Sara Guna* of *Pitha* by expelling the *Bahu Pitha Dosh*. After *sadyo virechana*, burning sensation during speaking was slightly reduced. After of *Shodhana*, *Oushadhis* like *Guluchyadi Kashaya*, *Shankha Bhasma* and *Lagusoortha Shekhara Rasa* were given for the *Shamana* of remaining *Pitha Doshas*. In classics *Pitha Raktha Hara* line of treatment are mentioned for *Pithaja Mukhapaka*. Here *Guluchyadi kashaya* is *Raktha Pithahara* and *Dahagna* in action. *Laghu soortha shekhara Rasa* is *Pithahara* and *Kleda Hara*. *Shankha Bhasma* is *Pitha Hara* and *Dahagna* in action. After 30 days, during follow up period burning sensation, hyperemia and both ulcers were absent.

### Probable Mode of Action:

- Virechana:** *Sadyo virechana* with *Avipathi churna*<sup>3</sup> (30gm) and *Draksha kashaya* as *Sahapana* was given. Which expels the *Bahu Pitha dosha*, thus in turns reduces the symptoms.
- Guduchyadi kashayam**<sup>4</sup>: It consist of *Guduchi*, *Padmaka*, *Arishtaka*, *Dhanyaka*, *Raktha chandana*, which are having *Pitha Raktha hara*, *Jwara hara*, *Dahagna* and *Agnikruth* action.
- Shanka Bhasma**<sup>5</sup>: having *Pitha hara* action, it reduces *Daha* or burning sensation.
- Laghu Susthashekar Ras**: It acts on *Pithaja mukapaka* by its *Kleda hara*, *Pitha hara* property. The patient was advised to follow proper *Pathya* during the treatment period.

### CONCLUSION

Thus, by following *Ayurvedic* treatment protocol and following *Pathya* and avoiding *Katu*, *Amla*, *lavana rasa* there was a certain amount of improvement for the patient's condition. Thus, *Ayurvedic* treatment is cost effective and doesn't have any side effects.

## REFERENCES

1. [https://en.wikipedia.org/wiki/Herpes\\_simplex\\_virus](https://en.wikipedia.org/wiki/Herpes_simplex_virus)
2. Traci C Johnson. Web MD Medical Reference. Aug 28,2020. <https://www.webmd.com/genital-herpes/pain-management-herpes#1>
3. K V Krishna Vaidyan. S Gopala Pilla. Sahasra yogam. Sujana Priya Vyakyanam. Churna kalpana. shloka no:73. Vidyarambham Publishers.Alapuzha.2011.jul.30<sup>th</sup> edition. pp:165
4. Vagbhata. Ashtanga Hrdaya English translation by R. Vaidyanath. Publisher Chaukambha Orientalia Varanasi. Vol-1 First Edition. 2007(16/15).pp:202.
5. Sadananda Sharma. Rasa Tarangini. English translation by Ravindra angadi. Chaukambha publishing house. Varanasi. First edition 2015. pp:194

**Table: 1**

Sl.no:	Structures	Findings
1.	Lips	NAD
2.	Gums	NAD
3.	Teeth	NAD
4.	Hard Palate	Ulcer a) Number:2 b) Size: 1cm in diameter, raised edges, centrally depressed c) Color: pallor d) Surrounding area: Hyperaemic e) Pain: Burning
5.	Soft Pallate	Hyperaemic
6.	Tongue	Coated
7.	Buccal Mucosa	NAD

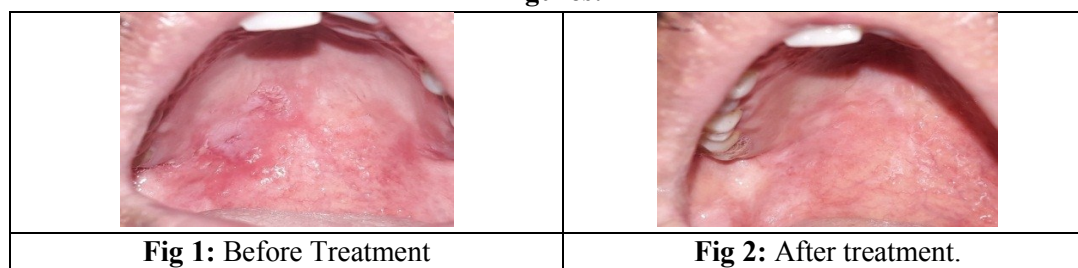
**Table 2**

Sl.no;	Investigations	Readings
1.	Acute phase serum HSV	Positive

**Table 3:**

Sl.no:	Symptoms	BT	AT
1.	Ulcer	Present	Absent
2.	Burning sensation	Present	Absent
3.	Fever	Present	Absent
4.	Hyperaemia	Present	Absent

**Figures:**



**Source of Support: Nil**

**Conflict of Interest: None Declared**

How to cite this URL: Premcy C. R. et al: Ayurvedic Management Of Oral Herpes W.S.R. To Pithaja Mukha-Paka - A Single Case Report. International Ayurvedic Medical Journal {online} 2021 {cited March, 2021} Available from: [http://www.iamj.in/posts/images/upload/674\\_676.pdf](http://www.iamj.in/posts/images/upload/674_676.pdf)