

PANEEYA KSHARA IN GALLBLADDER POLYP – A CASE STUDYNagaratna¹, Srinivas Masalekar²¹P.G. Scholar Dept. of Shalya Tantra Govt. Ayurvedic Medical College and Hospital, Bengaluru, Karnataka, India²Associate Professor Dept. of Shalya Tantra Govt. Ayurvedic Medical College and Hospital, Bengaluru, Karnataka, IndiaCorresponding Author: nagaratnay@gmail.com<https://doi.org/10.46607/iamj4008122020>

(Published online: December 2020)

Open Access

© International Ayurvedic Medical Journal, India 2020

Article Received: 10/11/2020 - Peer Reviewed: 16/11/2020 - Accepted for Publication: 22/11/2020

**ABSTRACT**

Gall bladder polyps are growths or lesion resembling growths in the wall of the Gall bladder. Most small Polyps (less than 1 cm) are not cancerous but the most dreaded complication of the Gall bladder Polyp is Adenocarcinoma¹. Direct reference of Gall bladder polyp is not available in *Ayurveda*. The disease can be correlated to *Pit-tashoshaja shola*. In this case study, a 25-year-old female diagnosed with Gall bladder Polyp was administered *Paaneeya Kshara* for 28 days. Assessment was done for pain and size of Polyp. Significant improvement was observed after treatment.

Keywords: Gallbladder Polyp, *Paneeya Kshara*.**INTRODUCTION**

Direct reference of Gall bladder polyp is not available in *Ayurveda*. The disease can be correlated to *Pit-tashoshaja shola*. In this case study, a 25-year-old female diagnosed with Gall bladder Polyp was administered *Paaneeya Kshara* for 28 days. Assessment was done for pain and size of Polyp. Significant improve-

ment was observed after treatment. Gall bladder Polyps are growth or lesion resembling growths (polypoid lesions) in the wall of the Gallbladder. True polyps are abnormal accumulations of mucus membrane tissue that would normally be shed by the body. Polypoid lesion of the gallbladder affects approxi-

mately 5% of the adult population. The causes are uncertain, but there is a definite correlation with increasing age and the presence of gallstones (cholelithiasis). Most affected individuals do not have symptoms. Gallbladder polyps are usually found incidentally when examining the abdomen by Ultrasound for other conditions, usually abdominal pain. Gall bladder Polyps (less than 1cm) are not cancerous but the most dreaded complication of the Gallbladder polyp is Adenocarcinoma¹. Cholesterolosis is characterized by an outgrowth of the mucosal lining of the gallbladder into fingerlike projections due to the excessive accumulation of cholesterol and triglycerides within macrophages in the epithelial lining. These cholesterol polyps account for most benign gall bladder polyps. Diagnosis is typically by Ultrasound or CT imaging. Most polyps are benign and do not need to be removed. Surgical removal of the gallbladder (cholecystectomy) is recommended when a gallbladder polyp larger than 1cm is found, even if the person has no symptoms clearly related to the polyp. Laparoscopic surgery is an option for small or solitary polyps². Direct reference of Gallbladder polyp is not available in *Ayurveda*. The disease can be correlated to *Pittashoshaja shola*. *Vaidya Kashinath Shashtri* the author of *Rasa Tarangini* quotes under the context of *Narikela Lavana Guna Karma* that, *Vata prakopa* in the *Pittashaya* leads to the *Shoshana* of *Pitta Dosha* present in the *Pittashaya* which later leads to *Shoola*³. This shows the excessive accumulation of cholesterol and triglycerides which later leads to the finger like projection named as Polyp.

Case Report:

A 25-year-old female married presented with complaints of pain abdomen and irregular menstruation for 2 months, so she consulted nearby hospital and there they advised for Ultrasonography of abdomen and pelvis. Reports revealed that the presence of Gallblad-

der polyp and posterior wall intramural uterine fibroid. So, she consulted *Shalya Tantra* OPD of SJIIM hospital, GAMC Bengaluru. Interrogation revealed that the patient had taken ANALGESICS but did not get any relief and approached for better management. Patient is not a known case of Diabetic mellitus and Hypertension or underwent any surgery. On physical examination pulse rate was 76/min, regular with normal volume. Blood pressure was 120/80 mmHg.

Systemic examination- Cardiovascular system- S₁ S₂ heard, no added sounds., Central nervous system- conscious, oriented, Respiratory system- bilateral air entry clear, Per abdomen- soft, non-tender.

Local examination- Inspection-oral cavity- hygiene is good, no dental caries, Shape of abdomen – flat, Shape of umbilicus- inverted, Palpation-superficial- no tenderness, Deep- no tenderness, no organomegaly, Percussion – tympanic note, Auscultation – 3 peristalsis/min

Investigations - Hb%- 14.6 gm %; ESR- 34mm/hr; RBS- 96mg/dl; CT- 2'4''; BT- 4'2''; HIV- NR; HbsAG – Negative.

Abdomino – pelvic sonography (22/10/2019) Gall bladder – 2.5mm nonmobile hyperechoic foci noted suggests Polyp., Posterior wall intramural uterine fibroid.

Nidana: *Ahara – Ruksha Ahara, Mamsa Sevana, Vihara – Avyayama, Manasika – Chinta, Krodha*

Samprapti- *Vata Prakopa* in the *Pittashaya* leads to the *shoshana* of *Pitta Dosha* present in the *Pittashaya* which later leads to *Shoola*⁶.

Diagnosis: Gall bladder polyp

Treatment Given: Patient is advised to take the combination of 2grams each of *Narikela Lavana*, *Nava-sadara* and *Yava Kshara* orally with *Jala (Water)* once daily in empty stomach in the morning, every day for 28 days.

Criteria for Assessment-

1. Visual analogue scale was used to get an assessment of pain relief after each sitting. Visual analogue scale noted as,

0-----1-----2-----3-----4-----5-----6-----7-----8-----9-----10

0-no pain, 1-3 is mild pain, 4-7 moderate pain, 8-10 severe pain.

Observation and Result-**2. Pain**

BT	AT
3	0

Clinical examination of the patient revealed regression of symptoms in 28 days.

3. Size of the polyp

BT	AT
2.5mm	Nil

DISCUSSION

Discussion is the important part of any research work. It provides a platform for re-examining the whole work, which is a key part of any scientific and methodological research work, even in classics, this has been highlighted and accepted in the name of *Vimarsha* i.e. discussion before coming to any conclusion. The reference of *Pittashoshaja Shula* is dealt in *Rasa Tarangini*. Under the context of *Narikela Lavana Guna Karma*, *Rasa Tarangini Kaara* quotes, *Vata prakopa* in the *Pittashaya* causes the *Shoshana* of *Pitta Dosha* in the *Pittashaya* which later leads to the manifestation of *Shula*. By considering Gall bladder polyp as *Pittashoshaja Shola*, the present study is carried out to know the efficacy of *Paneeya Kshara* in Gallbladder polyp, *Pittashoshaja shoola* is said to be *Tridoshaja Vyadhi*, still *Vata* and *Kapha* plays a major role in the formation of the poly. *Ruksha Guna* of *Apaana Vata* and *Ushna Guna* of *Pitta* hardens the *Kapha* which acts as nidus, upon which aggregation of *Dosha* takes place and finally results in *Pittashoshaja Shula*. *Kshra* is a remedy formed by process of *Bhasmikanana*, filtration, evaporation termed as *Sanskaras*. During the process of drying it undergo *kala*, *vata* and *Atapa Sanskara*. Which makes the drug dry and same *Gun*s of *Vata*. During *Bhasmikanana* process it undergo *Agnisanskara* which make the drug *Kaphagna* and *Vatagna*. Afterwards it gets settled with water for whole night here *Jala* and *Prithivimahabhuta* will act, build capacity to break. Further, the more it again undergoes *Agnisanskara*. During the whole process *Rasa*, *Veerya*, *Vipaka* of *Dravya* all changes and a new formulation i.e. *Kshara* is obtained. Which is of *Lavana Rasa*, *Ushna Veerya*, it dissolves the polyp. *Narikela Lavana* is said to be *Pa-*

chaka, *Amla Pitta Hara*, *Pittashamaka*, *Pittashoshaja Shoola Hara*. Here, *Narikela Lavana* contains albumin, globulin, amino acids and acetic acids. Hence it dissolves the polyp. *Navasadara* is said to be *Tridoshagna*, *Sukshma*, *Jataragni Deepaka*, *Pitta Saaraka*. It acts as expectorant. *Yava kshara* is said to be *Ruksha*, *Kapha Pittashamaka*, *Shoolahara*, *Medohara*, *Ag-nivardhaka* and *Gulma Hara*. It is useful in dyspepsia, abdominal pain, vomiting and obesity. It has diuretic property.

CONCLUSION

The combination of *Narikela Lavana*, *Navasadara Yuktha Yava Kshara* shown significant result in both subjective and objective parameter. The preparation of *Narikela Lavana*, *Navasadara Yuktha Yava Kshara* is simple, palatable, easy for administration, free from side effects and therapeutic efficacy is good. So, it can be adopted as a remedy for treatment of Gallbladder polyp.

REFERENCES

1. A concise textbook of Surgery, by Somen Das, 9th Edition, Published by Dr. S. Das 13, Old Mayors Court, Kolkata – 700005 India, The biliary system – 37th chapter, Page no.879-880.
2. <https://en.m.wikipedia.org/wiki>
3. *Rasa Tarangini* by Vaidya Sadanand Sharma, Prasadini Vyakhya by Shree Haridatta shashtri, edited by Vaidya Kashinath shashtri, Published by Chaukamba Sanskrith Sansthan Varanasi, Reprint – 2000, 14th Chapter – *Narikela Lavana Guna karma*, Verse-349,350.
4. SRB'S manual of surgery, by sriram bhat M, 6th edition, published by Jaypee brothers' medical

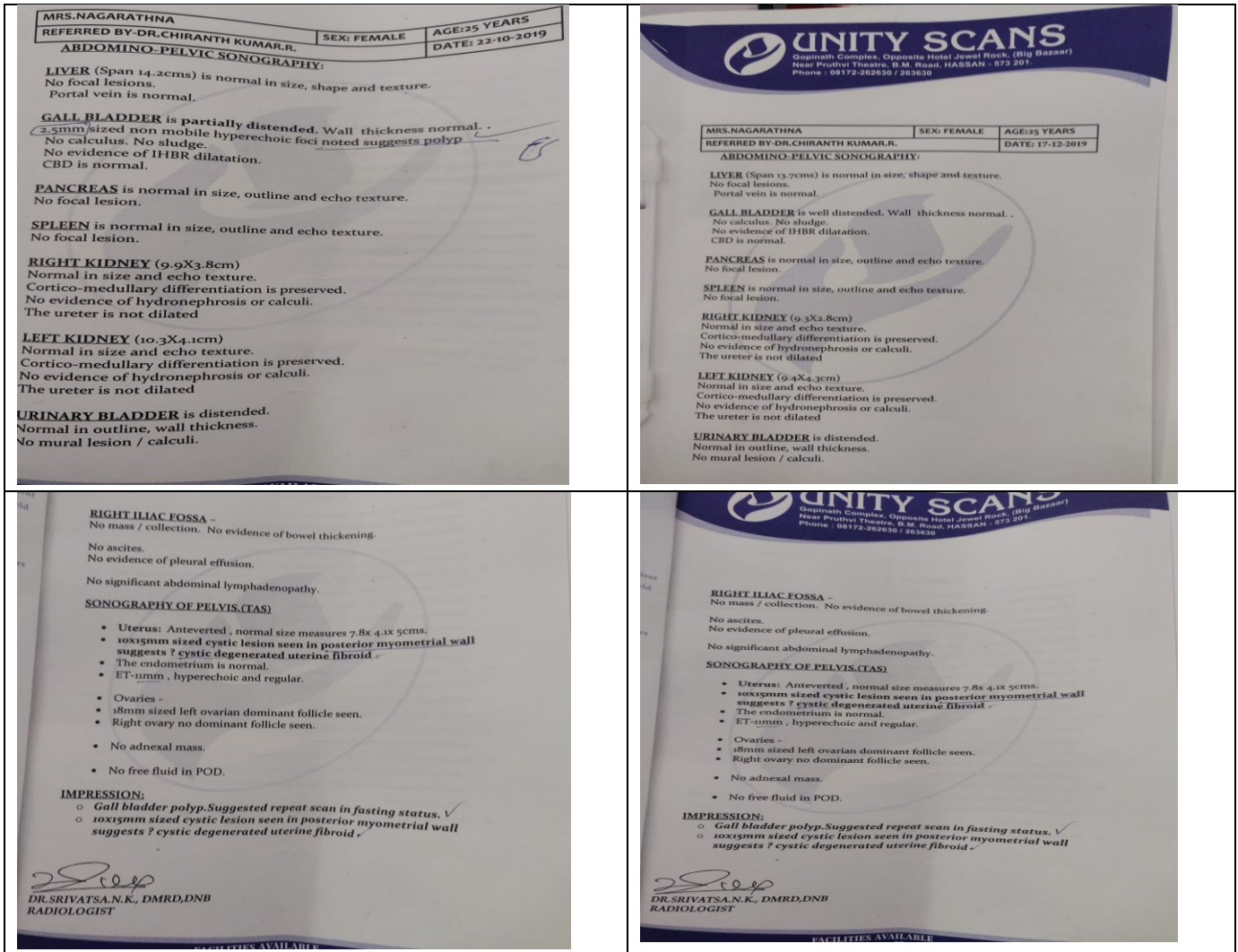
publishers(p) Ltd, Gall bladder – 12th chapter, page no. 650-651

5. Bailey and Loves, “the gall bladder and bile ducts”, short practice of surgery, 27th edition,

Hodder Arnald publications, part 2, chapter 67 – gall bladder and bile ducts, Pg- 1201.

Photographs:

Before and After treatment Ultrasound reports



Source of Support: Nil

Conflict of Interest: None Declared

How to cite this URL: Nagaratna & Srinivas Masalekar: Paneeya Kshara In Gallbladder Polyp – A Case Study. International Ayurvedic Medical Journal {online} 2020 {cited December, 2020} Available from: http://www.iamj.in/posts/images/upload/5427_5430.pdf