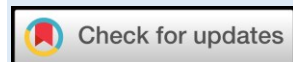

CLINICAL ASSESSMENT OF JALOUKAVCHARAN (LEECH THERAPY) IN MANAGEMENT OF SIRAKOUTILYAJANYA SHOTHA – A CASE REPORT**Sandhya S. Mane**

¹Assistant Professor, Kaychikitsa Dept.
Sai Ayurveda College, Hospital & Research Centre, Sasure-Vairag. Taluka-Barshi, Dist.-Solapur,
Maharashtra, India

Email: dr.sandhyamane957@gmail.com<https://doi.org/10.46607/iamj08062020>**(Published online: June 2020)****Open Access**

© International Ayurvedic Medical Journal, India 2020

Article Received: 30/05/2020 - **Peer Reviewed:** 01/06/2020 - **Accepted for Publication:** 08/06/2020**ABSTRACT**

Varicose veins are common disease in present era. This is mainly a lifestyle disorder. The common site of varicosity is lower limbs. The common cause of varicose veins is incompetency of perforating valves of veins of lower limbs. The predisposing factors of varicose veins are prolonging standing and increased abdominal pressure like pregnancy, abdominal tumors. A condition, in which a vein becomes dilated, elongated and tortuous, this is said to be “*Varicose Vein*”. The superficial perforating as well as the deep veins are involved in varicose veins. The contemporary treatment for varicose veins includes ligation, ligation with stripping surgical treatments. But these treatments can cause reoccurrence of this disease. Varicose vein has been described in *Ayurveda* texts. It was first described by *Acharya Sushruta* in *Sushruta samhita*. He has mentioned it as *siragranthi*. In *Ayurveda*, Varicosity is mainly *Vatajavyadhi*. *Pitta and Rakt* are also involved in this condition. In many *Ayurvedic grantha Raktamokshan* (bloodletting) by *Siravedha* (venesection) and *Jaloukavacharan* (leech therapy), *Veshtana* (wrapping of cloth or crepe bandaging), various shaman procedures like *Abhyang*, *Swedana* and herbs like *Guggulu*, *Guduchi*, *Musta*, *kanchnar* are available. Which can help in reducing symptoms and cure Varicose vein. We hereby report a case of a 35-year-old female with complaints of pain and swelling in the left lower limb from calf to the dorsum of the foot and anterior aspect of lower leg with wound and discoloration. She was treated with inter-

nal medication, external treatments and *Jalouavacharana*. During the treatment all the signs and symptoms of varicosity reduced to a very high extend.

Keywords: Varicose vein, *Sirakoutilya*, *Siravikruti*, *Jalaukavcharna*.

INTRODUCTION

In *Ayurveda* literature the Varicose vein has no its separate elaborative identity as a disease but considered as a *Siravikruti* (Venous disorders) and named as 'Sirakoutilya' or 'Kutilsira disease'. 'Siragranthi' mentioned by *Aacharya like Charak, Sushruta, Vagbhata* etc. In *Ayurveda* it is considered as 'Krichh sadhya vyadhi' (curable with difficulty) in early stage and *asadhya* in late stages affecting the vital parts of the body. *Acharya Sushruta* and *Vagbhata* mentioned *Jalaukavcharna* (leech therapy) in the treatment of all venous diseases.

Panchkarma is a *shodhana* treatment in *Ayurveda* which helps in eliminating toxins includes five basic processes. *Raktamokshana* is one out of them which is a mainstay of treatment for *Raktapradoshaja vikara*. Leech therapy comes under the *Raktmokshana* treatment. It is safe, painless and highly effective. *Raktmokshana* is the refinement of blood so helpful in treating many skin and vascular diseases.

The varicose vein is a disease in which veins are dilated, tortuous, elongated. The primary causes of varicose veins are the incompetency of the valves and the weakness in walls of the veins. This is an acute stage due to clogging of blood preventing the flow of venous back to heart. When it becomes chronic it causes venous flow insufficiency. The secondary causes are obstruction of venous out flow due to pregnancy, ascites, iliac vein thrombosis etc. The common risk factors of varicose veins include older age, obesity, major surgeries, hormonal replacement therapy etc. Women are affected more than men (10:1). The persons involved in the prolonged standing jobs e.g. Policeman, conductor, etc. often suffer from varicose veins. The common symptoms include heaviness in the legs, muscle cramps, itching around the swollen vein and pain felt in the whole leg or in the lower part of the leg.

Particularly in modern science the treatment of varicose veins is limb bandaging, surgical treatment (stripping of Sphenous vein), Sclerotherapy etc. but no medicinal treatment is available. *Ayurvedic* treatment is one of best for management of Varicose vein. The present case study has focus on effectiveness of *Panchkarma (Raktamokshana)* combined with *Shamana* therapy.

Case Report

History of Present Illness:

A 35-year-old female patient visited in OPD on 04/04/2019. She was presented to us for treatment of varicosities involving both legs. She had complaints of swelling over the left foot with wound, unable to walk properly. Pigmentation was also present on left foot over dorsal site since 7 years. Before seven years patient was alright then suddenly she had a complaint of pain in both legs at calf muscle region and muscle cramps in both legs during her gestational period (at 8th months). The symptoms of varicosities like pain in both legs and muscle cramps appears during each pregnancy and disappears after delivery only there is swelling over left leg and varicosities over both legs, Then she took the treatment from a local doctor but had no any relief she continuously taking symptomatic treatment for pain and swelling for some years . After some days her condition got worsened and she was unable to bear weight on the legs then she visited Private Hospital, Solapur. There she was advised to go for Colour Doppler study of both legs. The colour doppler diagnosed varicosities in left leg. She was treated symptomatically for 20 days but she did not get relief.

Past History:

Medical: H/O Dengue fever before 6 months (NS1 Antigen test-Positive on 3/10/18)

Surgical: H/O Family planning surgery before 2 years.

H/O Blood Transfusion: At the time of dengue fever.

Marital History: G3 P A L D

Family History: NAD

Medication History:

1) Tab. Deflan (500 mg) × BD

2) Tab. Paracip (650 mg) × BD

} For 9 months

O/E	S/E
GC: Fair, Afebrile	RS: AEBE, Clear
Pulse: 76/min	CVS: S1S2NAD
BP :120/84 mm of hg	CNS: Conscious, Oriented

P/A: Mild Gaseous Distention Urine and Stool: Passed.

On examination:

Sr.No.	Signs & Symptoms	Present/Absent
1)	Tenderness over left foot	Present
2)	Odema & Pigmentation	Present
3)	Sever aching pain (aggravated on standing for long time)	Present
4)	Radiating pain to other part	Absent
6)	Pain on dorsiflexion of foot	Present

Investigation: On Admission- All investigations were normal except 25-OH Vitamin D total which was **7.15 ng/ml (low)**. **USG Colour Doppler of B/L Lower Limb(A+V) done on 14/03/2014 shows:**

- Subcutaneous edema noted over left lower leg.
- Few dilated tortuous varicosities along posteromedial aspect of left leg with few incompetent perforators

Nidan Panchak:

Hetu:

- 1) *Aaharaj:* Dudhi, Vatana, Udid, Idali-dosa, Excessive Spicy-Sour-Salty Food.

- 2) *Viharaj:* Atiaayas, Atichankramana, Pregnancy, Ativyayam, Ratroujagarana

Poorvaroopa:

- Pain in both legs,
- Muscle cramps in both legs at calf region

Roopa:

- Swelling over left foot
- Ulceration with discharge and pigmentation over left foot fail to heal

Samprapti: (Ref.- *Sushruta Nidansthana Adhyaya 11 Shlok no.8-9*)

Hetusevan (Excessive exercise, Pregnancy)

Vatadosha Prakopa Veins of lower extremities affected due to *Vatadosha*

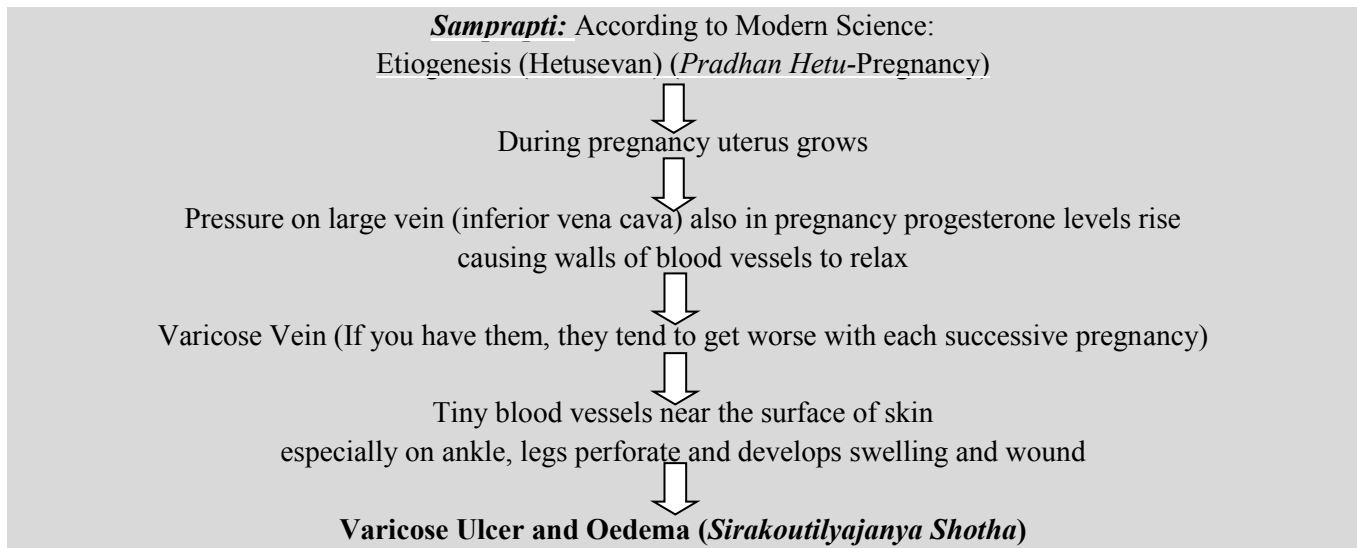
which in turn compresses, and dries up the veins and produce *granthi*

Veins become visible just beneath the skin surface and filled with abnormal gathering of blood

Develops *Sirakoutilya* (Varicose veins)

Tiny blood vessels near the surface of skin especially on ankle, legs perforate and develops swelling and wound

Sirakoutilyajanya Shothha



Materials and Methods:

- ❑ **Type of Study:** A Case Study.
- ❑ **Duration:** 1month
- ❑ **Follow Up:** After every 7days.

- ❑ **Study Center:** OPD& IPD Dept. Of Kayachikitsa, Sai Ayurveda College and Hospital Vairag, Solpaur
- ❑ **Criteria for assessment:** The total duration of treatment was 1 month. Patient was assessed weekly on the basis of visual analogue scale.

Treatment

1)	<i>Mustadi Kwatha</i>	20 ml × BD	Vyankali
2)	<i>Kaishor Guggulu</i>	500mg × BD With Ushnodaka	Vyankali
3)	<i>Sarivadi tail</i>	<i>Sarvang Abhyangarth</i>	Twice a day (<i>Pratah-Sayam</i>)
4)	<i>Jaloukavacharana Karma</i>	started on April 2019 and repeated weekly.	For 4 weeks

	Pathya	Apathya
Aaharaja	<i>Yavanna, Vari, Nachani, Aardrak, Jangal Mamsa, Koshna Jal.</i>	<i>Dadhi, Matsya, Dugdha, Masha.</i>
Viharaj	<i>Aalpa Vyayam.</i>	<i>Ratrajagarana, Divaswapana, Vegadharan.</i>

Results: The clinical features of varicose veins (varicosities) were improved at the end of 4th week. With a follow up for a period of 3 months, the patient had shown almost no signs of recurrence.

Symptoms	Before Treatment	After Treatment
Pain	Frequent pain	No pain
Heaviness over leg	Present	Absent
Thickened trophic skin	Thick skin with blackish discoloration	Thickening of skin reduced, Blackish discolouration disappears.

Oedema over left foot:

Measuring points	Before Treatment {04/04/2019}	Mid treatment {20/04/2019}	After Treatment {06 / 05 / 2019}
At Metatarsals	30.2 cm	29.3 cm	27.6 cm
Mid foot	37.0 cm	35.8 cm	34.4 cm
Ankle	31.1 cm	29.0 cm	29.0 cm

DISCUSSION

Patient had complaints of swelling over the left foot with wound, unable to walk properly due to pain. Pigmentation (Local skin changes) was also present on left foot over dorsal site since 7 years. So, the treatment was planned based on Ayurvedic principle of management of *Vrana*, *Shotha* and *Vatarakta*. *Raktamokshan* by *Jaloukavcharana* is the choice of treatment prescribed by the classic for *siragranthi* (Varicose vein). *Shamana aushadhi* and *Jaloukavcharana* have shown remarkable healing response in this patient.

Probable Mode of Action-

1. *Mustadi Kwatha*: (Ref. *Charak Samhita Chi. 7th / 65*).

Most of ingredients used in *Mustadi Kwatha* are *Tikta-kasaya rasatmka*, *Ushnaviryatmka*, *Tridosashmaka*, *Dipaniya* and *Dahanashamak* properties. This is an infallible remedy for the *kushta* (Skin disease). Acharya Charaka also mention that it is useful in treating *shotha* (oedema)

Due to above properties it reduces the pressure effects, inflammation and maintains normal tone of venous wall and improve their function.

2. *Kaishor Guggulu* (Ref.- Krishnan. K.V, 2006)

Kaishor Guggulu have *guduchi* which comes in traditional rejuvenator Ayurvedic plant category. 'Sira' and 'Snayu' are the bi product (*updhātu*) of *rakta* (blood). 'Kaishor Guggulu' has 'Raktaprasadnya' character. Hence, it facilitates formation of Healthy Newer tissues and also strengthens the blood vessels, thus corrects venous valvular dysfunction. Further, once *Rakta* is purified, its bi product (*updhātu*) i.e. *Sira* (veins) also gets pacified, thus may corrects venous valvular dysfunction when used internally along with the adjuvant treatment.

3. *Sarivadi Tail* - (Ref. *Charak Samhita chi.29/91-97*)

Sarivadi tail is an ayurvedic formulation described in *Charak Samhita Vatshonita Chikitsa*. This is a polyherbal medicine also known as *Madhuparnyadi tail*. Most of the ingredients used in *Sarivadi taila shothahara* (anti-inflammatory) and *ropaka* (wound healing), which are important requirements of healing of a wound. It also Improves blood circulation, cor-

rects skin discoloration and pacifies venous valve dysfunction. Thus, it breaks pathogenesis of varicosity at cellular level and helps in wound healing.

4. The *Jaloukavcharna*

The accumulation of *rakta* and vitiation of *Vata* in *Siras* leads to dilatation of the veins and tortuosity. This causes local congestion in that area causing *Shoola* and *Shotha*.

Repeated bloodletting by *Jaloukavcharana* brings down the local *Shotha* by relieving the local congestion (which contains metabolic toxins, debris of the dead tissues) by removing vitiated blood first. Healthy and nourishing blood is supplied to that tissue where the stasis is cleared off. This promotes the regaining the health of surrounding tissue as well as the vessel wall.

Acharyas. Thus, by removing the stagnant vitiated blood by *Jaloukavcharana* reduces the localised intravascular pressure and volume hence relieving *Shoola*.⁽³⁾

Vaivarnya (discolouration) occurs due to stasis of blood in the veins. This leads to haemolysis of blood, leading to the deposition of haemosiderin pigment in the skin which manifests as the blackish discolouration noted in patients of varicose veins. By *Jaloukavcharana* the *dushtarakta* is drained out, since there is no further stasis of blood, there is no subsequent haemolysis, thereby, reducing *Vaivarnya* and restoring normal pigmentation of skin.⁽³⁾

For *Sirakoutilyajanya Shotha* (Varicose vein) is non-invasive, safe alternative healing with no side effects. Once the leeches attach themselves to the skin of the patient and start sucking blood, the saliva enters the puncture site along with enzymes and chemical compounds which are responsible for the progress of cure and treatment. The leech's saliva which includes hiru-din a anticoagulant protein. Because of anti coagulating agents the blood becomes thinner, allowing it to flow freely through the vessels. Another compound that prevents coagulation is calin. This works as an anticoagulant by binding itself to collagen. It is also an effective inhibitor of platelet aggregation caused by collagen. The saliva of leech also contains factor Xa

inhibitor which blocks the action of the coagulation factor Xa.

Clot dissolving effect of leeches' leech's saliva also has a thrombolytic effect, which can also dissolve clots of blood that have formed.

Anti inflammatory effect of leeches Bdelins is a compound in the leech's saliva that acts as an anti-inflammatory agent by inhibiting Trypsin as well as Plasmin.⁽⁵⁾

Vasodilating effects of leeches There are 3 compounds in the leech saliva that act as vasodilator agents and they are the histamine like substances, acetylcholine and carboxypeptidase -A inhibitors. All these acts to widen the vessels thus causing flow of blood of the site.⁽⁵⁾

Bacteriostatic and Anaesthetic effect of leeches the saliva of leeches contains anaesthetic substances which relieve pain on the site and inhibit the growth of bacteria.

There were no adverse events throughout the management. The mode of treatment was found to be cost effective, safe and easy to implement. So *jaloaukavcharna* is safe and effective method in management of varicose veins than modern treatments.⁽⁵⁾

CONCLUSION

The clinical features of oedema due to varicose veins were improved at the end of second week and almost totally relieved after completion of one-month treatment. Present study shows *Jaloaukavcharana* as a

promising treatment for varicose veins and for complications developed due to varicose vein.

REFERENCES

1. Sharma Sangita, Sethi G.R. (2005 standard treatment guideline, B. I. Publications Pvt. Ltd. New Delhi 2nd edition pp387)
2. Braunwald et.al. (2003), Harrison's Principles of Internal Medicine.MC Graw-Hill Medical Publishing Division; U. S. A.p Vol.1. Ch.248.
3. Shastri A.D. (2007) Kaviraja Ambikadatta Shastri Hindi Commentary (Reprint) on Sushruta Samhita with Ayurveda Tattva Sandipika; Chaukhamba Sanskrit Sansthan; Varanasi 2009; Vol.-2, Sutrasthana. Chapter. -11, Page No.-539-540.
4. Tripathi R. D. (1995); Ashtanga Samgraha; Chaukhamba Sanskrit Series; Varanasi. Uttar Tantra Ch.34.
5. http://www.leechestherapy.com/venous_disease_php. 27/05/2019 (8.30 pm)
6. S Das: A Manual on Clinical Surgery, Publisher Dr. S. Das, 6th edition, reprinted, 2007, Chapter 7, pp -478, pg- 73 2.
7. Acharya Susrutha: - Susrutha Samhita with Nibandhasangraha Commentary of Dalhanacharya and Nyayachandrika Panchika of Gayadasa edited by Yadavji Trikamji, Published by Chaukamba Orientalia, Varanasi 2012, Chapter-11, Verse-8, pp-824, pg 311
8. Acharya Vaidya Harisastri Paradakara, (2011) Ashtanga Hridaya,with commentaries of Sarvanga Sundari of Arunadutta and Ayurveda Rasayana of Hemadri, 10th edn, Varanasi, Chikitsa Sthanam Chp:8/158, Pp-654., Chp.:22/35, and 22/41-44, Pp-731.
9. K. V Krishnan Vaidyan and S. Gopalapilla, (2006) Sahasrayogam, 26th edn, Malayalam, Vidyarambham publishers, kashaya prakarana Pp-40-291.

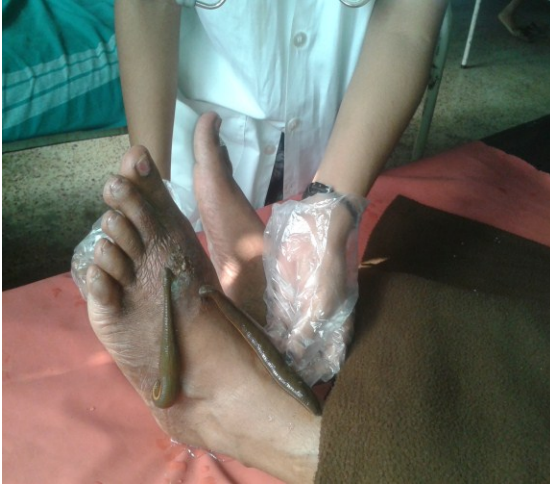

Fig. 1 During Treatment

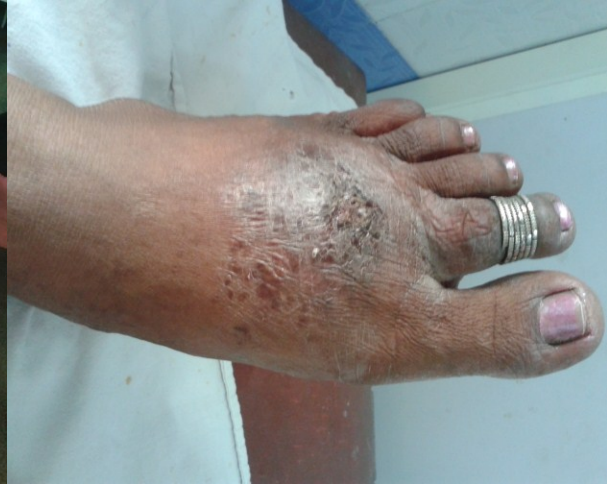

Fig. 2 After Treatment

Source of Support: Nil

Conflict of Interest: None Declared

How to cite this URL: Sandhya S. Mane: Clinical Assessment Of Jalaukavcharan (Leech Therapy) In Management Of Sirakoutilyajanya Shotha – A Case Report. International Ayurvedic Medical Journal {online} 2020 {cited June, 2020} Available from: http://www.iamj.in/posts/images/upload/3820_3826.pdf