



## MANAGEMENT OF COMPLICATED CASE OF BHAGANDARA ( FISTULA IN ANO ) WITH KSHARA SUTRA: A CASE STUDY

Renuka Talwade<sup>1</sup>, Ashok G Naikar<sup>2</sup>, Savita<sup>3</sup>

<sup>1</sup>PG Scholar, Dept of Shalya tantra N K Jabashetty Ayurvedic Medical College and Hospital Bidar ,Karnataka , India.

<sup>2</sup>Associate Professor, Dept of Shalya tantra N K Jabashetty Ayurvedic Medical College and Hospital Bidar ,Karnataka , India.

<sup>3</sup>PG Scholar, Dept of Shalya tantra N K Jabashetty Ayurvedic Medical College and Hospital Bidar, Karnataka, India.

Corresponding Author:[renukatalwade@gmail.com](mailto:renukatalwade@gmail.com)

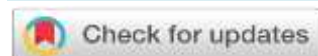<https://doi.org/10.46607/iamj4210122022>

(Published Online: December 2022)

Open Access

© International Ayurvedic Medical Journal, India 2022

Article Received:18/11/2022 - Peer Reviewed: 04/12/2022 - Accepted for Publication: 17/12/2022



### ABSTRACT

*Bhagandara* is a common disease occurring in the ano-rectal region. The word *Bhagandara* is composed of 2 words *Bhaga* and *Darana*. This causes pain and discomfort in the anal region. which hampers the daily routine work. The wound is located in the anal region which is more prone to infection, and it takes a long time to heal. In Ayurveda, *Bhagandara* is considered one of the *Ashta mahagada*<sup>1</sup> (8 major diseases) due to more recurrence rate. *Bhagandara* is treated by different modalities in modern science but today no single modalities have proven to be complete for fistula, *Ksharasutra* therapy is the unique specialized parasurgical procedure that is used in fistula in ano. The present study was undertaken to assess the complicated case of *Bhagandara* treated by *Ksharasutra*. A case was taken from OPD of NKJAMC attached teaching, shreesiddharoodha charitable hospital, Bidar, age 41 yrs. .male patient presenting with pain, swelling, and discharge from the anal region was examined in Shalya OPD treated with *Kshara sutra* considering it an ideal procedure in the treatment of *Bhagandara* as it cuts and cures the unhealthy tissue present inside the fistulous tract.

**Keywords:** Bhagandara, Fistula in ano, kshara sutra, Mahagada.

## INTRODUCTION

*Bhagandara* can be correlated with fistula in ano, *Bhagandara* means which causes splitting or discontinuity in the region of Bhaga, Guda, Basti region<sup>2</sup>. It is one among the *Ashtamahagada*, in modern fistula word is derived from a latin word, it means a tract or pipe or flute. It is an abnormal communication between the anal canal and rectum with exterior(perianal skin) is called fistula in ano. It usually results from an anorectal abscess that burst spontaneously or opened adequately<sup>3</sup>. *Kshara sutra* is a medicated thread, which is prepared by a repeated coating of various medicinal plants over the thread. The procedure of applying *Kshara sutra* is very easy, in most cases it was done under local anesthesia and only a few cases require spinal anesthesia. Changing of the *Kshara sutra* was done by railroad method i.e the new medicated *Kshara sutra* was tied to the end of the previous *Kshara sutra*, this sutra is cut and pulled out through a fistulous opening, and the new one placed in position.

## CASE REPORT

Gender – male

Age – 41 yrs.

•

Occupation –labour

Date of admission –31/05/22

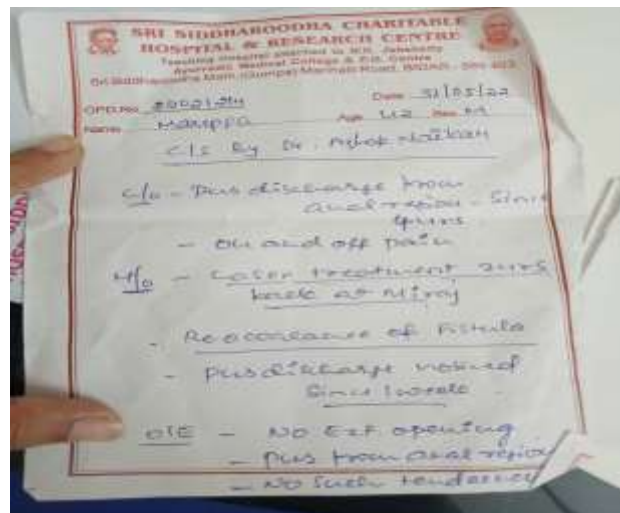Date of recovery- 1/07/22


Chief complaints and duration – patient complaints of pain, swelling, and pus discharge from the anal region for one and half years.

H/O Present illness-41 yrs. male patient present with complaints of painful swelling with pus discharge from the anal region for one and a half years. H/O laser treatment, 02 yrs. back at Miraj. presently on examination pus discharge from the anal region. No external opening.

H/O past illness- no previous history of any other sever illness

- General examination :
- General condition: moderate
- CVS- S1 S2 Heard
- Pulse -72/min, BP-120/80mmhg
- RS- B/L Air entry is clear
- Digestive system- Appetite-normal, Bowel-normal
- Uro genital system -NAD





On local examination:

In the lithotomy position of the patient, findings were observed, the patient has pus discharge from the anal region, and the abscess was noted in the Intersphincteric region predominantly on the right side extending into the posterior Intersphincteric region. The main tract is traversing through the external sphincter at 6 O clock position with an Intersphincteric abscess and internal opening at 8 and 5 O clock positions, probing was done from the external opening to find the internal opening. On probing 6 cm tract was found in the anal canal. Finally, the diagnosis was confirmed based on MRI and CBC investigation as a complicated case of fistula in ano.

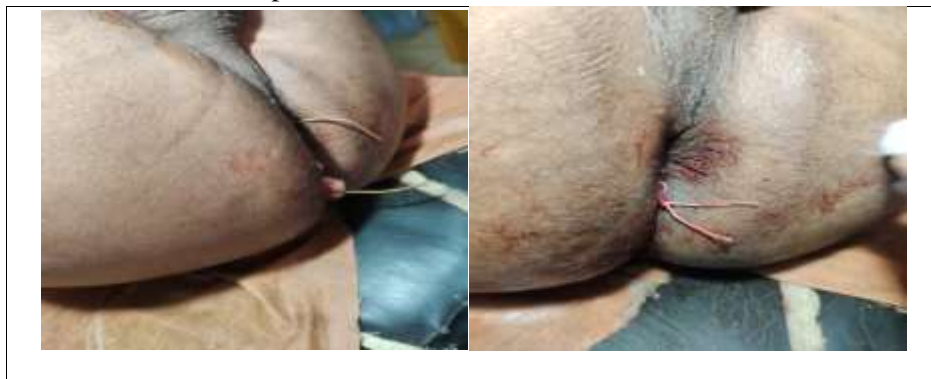**PRE –OPERATIVE**

The patient is advised to do routine investigations like CBP, CT BT, RBS, HIV, and HBSAg, complete urine examination was done, and all reports are nor-

mal. Then patient consent was taken and posted for the *Kshara sutra* application. *Kshara sutra* prepared with *Apamarga* as per standard protocol was used. Before application of the *Kshara sutra*, the patient was advised to part preparation. followed by Inj T.T0.5 ml and plain 2% Xylocaine test dose were given.

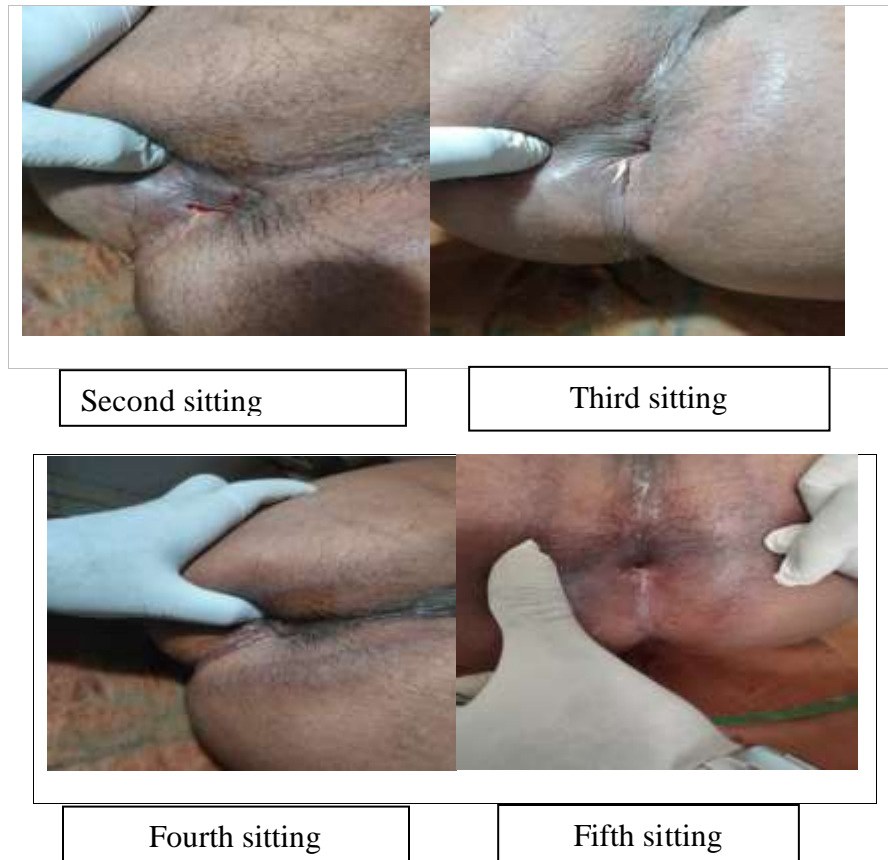
**OPERATIVE PROCEDURE**

The patient was taken into lithotomy position on the operation table after proper painting and draping, Inj 2% xylocaine was infiltrated nearby the anal canal. Extension of the tract was done by probing. the probe was removed through the external opening at 7 O clock position. *Kshara sutra* was tied covering the entire underlying track for cutting and healing. All aseptic precautions were maintained. and haemostasis is achieved.



Probing

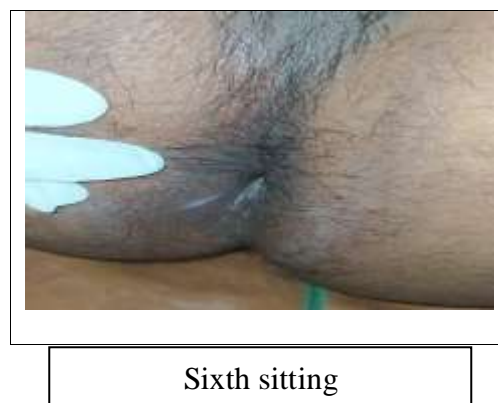
Primary threading



#### POST OPERATIVE

*Kshara sutra* changed every week promoting healing and reducing pain and inflammation. *TriphalaguguluGandhakarasyana*, *Sapthavimsatiguggulu*, BD, *Dasamoolarishta* 3tsp BD, were prescribed.

After complete healing of the track



#### FOLLOW UP

Asked patient for changing *Kshara sutra* every 7<sup>th</sup> day till cutting of the tract. A hot sitz bath with *Triphalachurna* is advised. after 6 sittings track was totally cut out and healing was achieved simultaneously.

#### OBSERVATION:

The initial length of the track was 6cm. which got cut through in a 1-month and 7days. After cutting through of track patient was followed up for one month weekly. No signs and symptoms of recurrence were observed.

## CONCLUSION

Now a days *Kshara sutra* is the first line of treatment for the fistula in ano, especially in recurrence and complicated fistula. *Kshara* is having the *Chedana*, *Bhedana*, *Lekhana* also *Tridoshaghna* properties<sup>4</sup>. *Kshara sutra* therapy helps in removing unhealthy granulation tissue and formation of healthy granulation tissue, it also removes fibrous tissue and helps in the healing of the tract. Moreover, it is an affordable and cost-effective method with admirable results.

## REFERENCES

1. Shastri kavirajAmbikadatta, sushrutasamhita, Ayurveda Tatvasandeeepika, Hindi commentary, 1997<sup>th</sup> edition,

reedition 2010, Varanasi, Chaukhamba Sanskrit samsthana, sutrasthana, page no 163.

2. Shastri kavirajAmbikadatta, sushrutasamhita, Ayurveda Tatvasandeeepika, 2016 edition, Varanashi, Chaukhamba Sanskrit samsthana, Nidanasthana, 4/4, page no 317.
3. Dr. Das. S.A concise textbook of surgery, Publisher Dr. Das. S. 7<sup>th</sup> edition Reprint ed. Chapter11, 2021; P - 1071.
4. Shastri kavirajambikadatta, Sushruta Samhita , Ayurveda TatvaSandeeepika, 2016 edition , Varanasi , Chaukhamba Sanskrit samsthanasutrasthana, 11/3, P-45.

**Source of Support: Nil**

**Conflict of Interest: None Declared**

How to cite this URL: Renuka Talwade et al: Management of Complicated Case of Bhagandara (Fistula in Ano) With Kshara Sutra: A Case Study. International Ayurvedic Medical Journal {online} 2022 {cited December 2022} Available from: [http://www.iamj.in/posts/images/upload/3510\\_3514.pdf](http://www.iamj.in/posts/images/upload/3510_3514.pdf)