



## AN ANATOMICAL VARIATION OF THE PERONEUS QUARTUS MUSCLE: A CASE STUDY

Tamanna Gumber<sup>1</sup>, Vikash Bhatnagar<sup>2</sup>, Sandeep Madhukar Lahange, Shailza Bhatnagar<sup>3</sup>, Anita Bochalya, Bhumika Rudani, Anjali Sharma<sup>4</sup>

MD Scholar<sup>1</sup>, Professor<sup>2</sup>, Associate Professor<sup>3</sup>, MD Scholar<sup>4</sup>. PG Department of Rachana Sharir, National Institute of Ayurveda, deemed to be University (*De-novo*), Jaipur Rajasthan

Corresponding Author: [tamannagumber@yahoo.in](mailto:tamannagumber@yahoo.in)

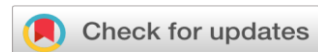<https://doi.org/10.46607/iamj2511122023>

(Published Online: December 2023)

### Open Access

© International Ayurvedic Medical Journal, India 2023

Article Received: 13/11/2023 - Peer Reviewed: 30/11/2023 - Accepted for Publication: 13/12/2023.



## ABSTRACT

The peroneus quartus (PQ), an extraneous accessory muscle of the ankle, is found in the lateral compartment of the leg. It is the most frequent source of genesis and its insertion is along the peroneus brevis muscle into the calcaneo retrotrochlear prominence. We noticed a peculiar variation of the muscle that arises from the lateral surface of the fibula in between the two peroneal muscles. A lateral malleolus that was protruding from the skin was crammed with tendons. The muscle was discovered to be attached to the peroneal trochlea.

The peroneus quartus is found with a frequency varying from 10 to 21.7% of observed individuals. It is rarely involved in pathologic processes of the foot and ankle. Only a few reports exist in the literature involving peroneus quartus in a “retro malleolar conflict” (lateral ankle stenosis), sometimes in association with longitudinal attrition and tears of the peroneus brevis. The presence of this muscle in individuals can complain of ankle pain with throbbing and tingling sensation along with swelling. It could include the ankle weakness along with ankle instability.<sup>1</sup>

**Keywords:** lateral compartment of leg, peroneus brevis, peroneus longus

## INTRODUCTION

A lateral compartment muscle of the leg called the PQ is an auxiliary peroneal muscle. Hecker, who published it in 1923, was one of the first writers to do so. Its emergence has likely been caused by the evolution of upright posture in man. It helps with lateral stabilization of the ankle as well as eversion of the foot and pronation of the foot against the ground.

Anatomical experts are interested in this muscle from a clinical standpoint.<sup>2</sup> The lateral compartment of the leg is made up of two muscles: the peroneus longus and peroneus brevis. This compartment continues as the superior peroneal tunnel, which is covered by the superior peroneal retinaculum. The base of this tunnel is formed by the posterior intermuscular septum of the leg and the retro malleolar groove of the fibula. The primary components of this tunnel are the tendons of the peroneus longus and brevis. When additional PQ fibers or tendons are present, the tunnel becomes crowded, and the superior peroneal retinaculum may rip. Additionally linked to PQ include ankle pain, subluxation, tenosynovitis of the peroneal tendons, symptomatic hypertrophy of the retro trochlear eminence, and peroneal tears. We have only ever seen one case of this auxiliary muscle, which has an unusual origin between the two peroneal muscles of the lateral compartment and an unusual insertion at the peroneal eminence.

### Material and method

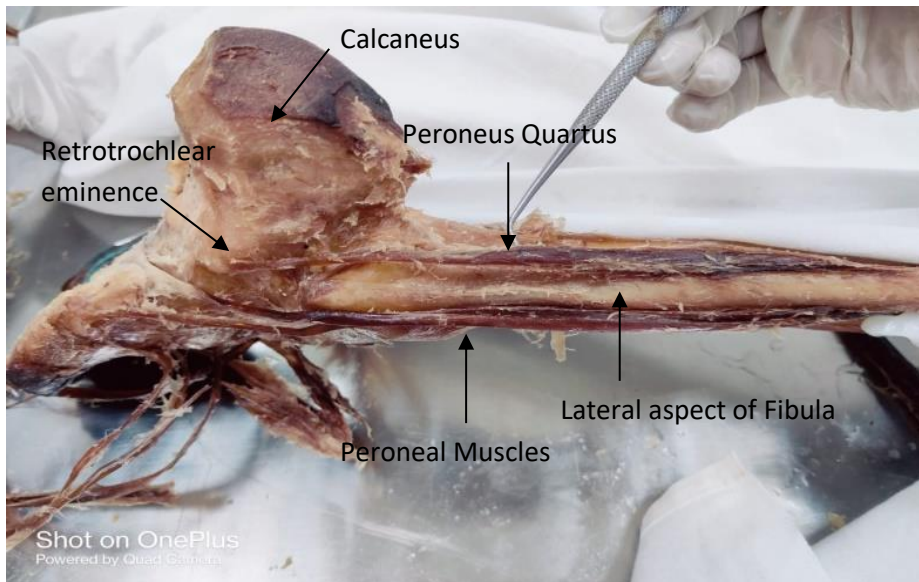
A rare case of peroneus quartus muscle in right lower limb was observed during routine dissection class for undergraduate scholars<sup>3</sup>. This dissection was done on the cadaver of 84 years old male in the department of

Rachana Sharir, National institute of Ayurveda (Deemed to be University) Jaipur.

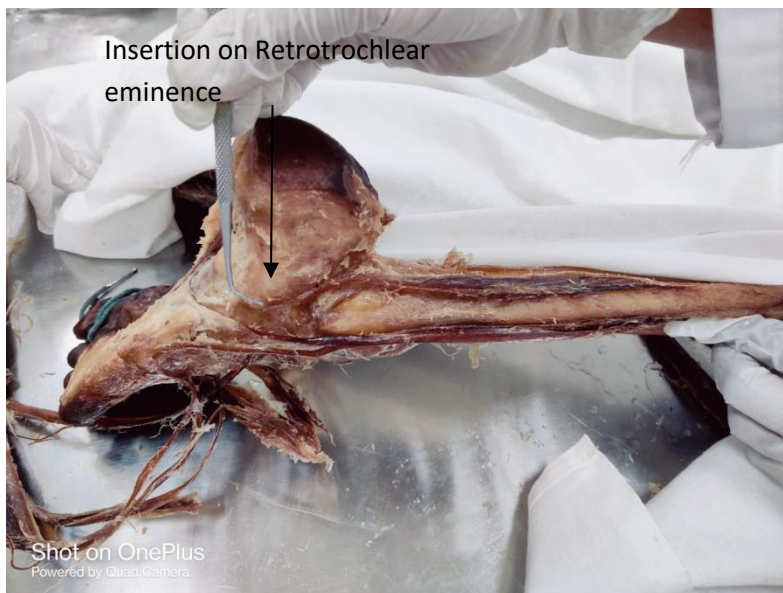### Case report:

In one of the ten cadaveric limbs that we dissected for study; we were able to locate the peroneus Quartus muscle in one cadaver. The right leg of a male cadaver that was about 84 years old was isolated and dissected. During the present dissection study, while doing a dissection of the lateral compartment of the leg, we found fibers of the peroneus longus muscle originating from the head of the fibula and Upper one-third, and posterior half of the middle one-third of the lateral surface of the shaft of the fibula and peroneus brevis originating from Anterior half of the middle one-third and whole of the lower one-third of the lateral surface of the shaft of fibula. While separating the fibers of these muscles we came across some fibers of peroneus quartus (Fig.no 01) muscle which were originating from lower lateral aspect of fibula adjacent to the peroneus brevis muscle, which inserted into the retrotrochlear eminence on lateral aspect of calcaneus.

The slip of the peroneus quartus muscle (Fig.no 02) with measured belly length of 10.5 cm breadth 1.2 cm and length of tendon part 6.4 cm long has been noted. Muscle tendon distinctly passed in the retro malleolar groove and got inserted on to the raised eminence on the lateral aspect of the calcaneum just behind the peroneal trochlea. This first metatarsal's lateral aspect was connected to the main tendon of the Peroneus longus, which crossed the cuboid bone's plantar surface.



**Fig.no 01** shows the assessor fibres of peroneus quartus muscle on lower lateral aspect of shaft of fibula (Right)



**Fig.no 02** Shows the insertion of assessor fibres of peroneus quartus muscle at retrotrochlear eminence on lateral aspect of calcaneus.

## DISCUSSION

During present dissection study while doing dissection of lateral compartment of leg we found fibers of peroneus longus muscle originating from Head of the fibula and Upper one-third, and posterior half of the middle one-third of the lateral surface of the shaft of the fibula and peroneus brevis originating from Anterior half of the middle one-third and whole of the

lower one-third of the lateral surface of the shaft of fibula<sup>4</sup>. While separating the fibers of these muscles we came across some fibers of peroneus quartus muscle which originating from lower lateral aspect of fibula adjacent to the peroneus brevis muscle, which inserting into the retrotrochlear eminence on lateral aspect of calcaneus.

The lateral compartment of the leg contains the peroneus quartus muscle, an auxiliary muscle. In the

peroneal compartment, this auxiliary muscle has been given several names, including Peroneus digitiquinti by Testut, Peroneus digitiquintus by Otto, Peroneus calcaneum externum by Hecker, and Peroneus quartus by Otto. The peroneus quartus muscle, which has its origin from the lateral aspect of the leg and its insertion on the lateral side of the foot, has simplified this terminology, though. Hecker noticed that 13% of the overall population had the muscle. However, Sobel et al. discovered a 21.7% incidence among the cases they had seen. In contrast to this, Zammit and Singh's cadaveric and MRI investigation of the muscle revealed an incidence of 6.6%.<sup>5</sup>

According to Sobel et al., in 63% of cases, the peroneus quartus muscle originates from the peroneus brevis itself in the distal portion of the leg. According to observations made by Biligili et al., the peroneus brevis is the muscle's primary origin in the majority of cases. Additionally, they discovered that the peroneus quartus was present in cases where the peroneus brevis was less developed. So, the presence of this muscle sometimes leads to ankle pain or ankle instability which makes it difficult in diagnosis or is rather confused with the flexor retinaculum deformity. So, the sole purpose of this muscle is not just a variation it is something about which a surgeon, a radiologist and anatomist should be aware about for the proper diagnosis. As there are two tendons found in peroneal region but the presence of this should not be confused with something else. There is no such functional activity of this muscle, but the structural presence could help in either grafting of some muscle tear or in the reconstruction of any muscle in body.

#### ACKNOWLEDGMENTS

Department of Sharir Rachana, National Institute of Ayurveda, deemed university, faculty and PG Students assisted with the leg dissections and measurements and my Supervisor Dr. Vikash Bhatnagar Professor, National Institute of Ayurveda Deemed University, Jaipur for his continuous support and expertise guidance.

#### CONCLUSION

Recent times have seen a dearth of research on the origin, makeup, and significance of this muscle, particularly in relation to our ethnic group, making it difficult to compare and contrast the results of this muscle. Additionally, we think that surgeons, orthopedic doctors, and radiologists need to be aware of these muscle variations because they may be associated with pathologies like peroneus tendonitis and tendon dislocations, which are alarmingly on the rise. Additionally, peroneus tendon tears are fairly typical, particularly peroneus brevis tendon tears (PBT) in lateral ankle-inversion injuries that result in persistent ankle instability<sup>6</sup>. Also, in a patient with repeated peroneal tendon dislocations, this peroneus quartus tendon can be used to repair the retro malleolar groove, which stabilizes the peroneal tendons.<sup>7</sup>

#### REFERENCES

1. Accessory Peroneal Muscle: A Case Report of an Anomalous Symptomatic Peroneus Quartus Muscle <https://scholars.okstate.edu/en/publications/accessory-peroneal-muscle-a-case-report-of-an-anomalous-symptomat>
2. A Critical Review Study on History of Indian Anatomy World journal of pharmaceutical and medical research ISSN 2455-3301 08/06/2017
3. A Critical Review Study on Dissection Techniques in Ancient Indian Anatomy in Context to Its Clinical Significance World journal of pharmaceutical and medical research (WJPMR), ISSN 2455-3301 2017,3(9),01/10/2017Pg 371-375
4. BD Chaurasia/ BD Chaurasia Human Anatomy Regional and Applied Dissection Volume 2/ Chapter 9/CBS Publishers & distributors/Eighth Edition/B D Chaurasia's Human Anatomy Regional & Applied Dissection & Clinical Volume 2.pdf
5. Peroneus Quartus Muscle: Revisited <https://www.jmaacms.com/doi/JOMA/pdf/10.5005/jp-journals-10070-0023>
6. L Moore, Arthur F Dalley, Anne M.R. Agur /Clinically Oriented Anatomy/Eighth Edition by Keith/Wolter Kluwer
7. The peroneus quartus muscle <https://boneandjoint.org.uk/Article/10.1302/0301-620X.85B8.13532/pdf>

Source of Support: Nil

Conflict of Interest: None Declared

How to cite this URL: Tamanna Gumber et al: An Anatomical Variation of the Peroneus Quartus Muscle: A Case Study. International Ayurvedic Medical Journal {online} 2023 {cited December 2023} Available from: [http://www.iamj.in/posts/images/upload/3122\\_3125.pdf](http://www.iamj.in/posts/images/upload/3122_3125.pdf)