

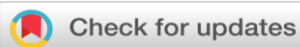EFFECT OF CHEMICAL CAUTERIZATION IN ANAL FISTULA BY FILLING LIQUID ARAGWADHA KSHARA -A CASE REPORT**Athira. K¹, C. Raghunathan Nair², Deepthi C.V.³**¹MS Final year PG Scholar,²Professor & HOD,³Professor

Department of Salyatantra

Sree Narayana Institute of Ayurvedic Studies and Research, Pangode, Puthur, Kollam

Corresponding Author: athirasudhakaran2789435@gmail.com<https://doi.org/10.46607/iamj4413012025>**(Published Online: January 2025)****Open Access**

© International Ayurvedic Medical Journal, India 2025

Article Received: 08/12/2024 - **Peer Reviewed:** 29/12/2024 - **Accepted for Publication:** 09/01/2025.**ABSTRACT**

Anal fistula (*Bhagandara*) is one of the most common anorectal diseases. It's complicated pathogenesis has been considered a clinical challenge for surgeons. In classics, *Ksharasutra prayoga* is mentioned for treating *Nadi vrana* and *Bhagandara*. Most of the patients find it inconvenient as it needs weekly follow-ups. Considering this, an alternative method was selected. This study modified the conventional method by filling liquid *Kshara* into the fistulous track in a single sitting. The case study was conducted on a male patient aged 51 years to assess the effect of chemical cauterization in the management of Anal fistula, and assessment was done based on pain, tenderness and discharge. The patient was assessed every day after *Kshara* filling for 1 week. Follow-up was done once a week for 1 month, then once in 2 weeks for 2 months. All the symptoms showed highly significant results. *Kshara* is highly caustic and can perform *Chedhana*, *Bhedana* and *Lekhana Karma*. If we make use of these actions of *Kshara* in Low anal fistula, it may decrease the duration of treatment as well as recurrence.

Keywords: Anal fistula, *Aragwadha Kshara*, *Bhagandara*

INTRODUCTION

In the present era, where improper dietary habits, inadequate sleep, a sedentary lifestyle and high-stress levels are common, there has been a notable increase in the occurrence of anorectal diseases. The anal fistula is one among them. It is chronic abnormal communication, usually lined to some degree by granulation tissue. It runs outwards from the anorectal lumen to an external opening on the skin of the perineum or buttock.¹ Anal fistula can be correlated to *Bhagandara*, which is considered a *Krichrasadhya Vyadhi* due to its complexities and high recurrence rate. For decades, Ayurveda para-surgical management has gained a proven upper hand in the management of *Bhagandara* by applying the classical management modalities of *Bhagandara* and *Nadivrana Chikitsa*.²

Acharyas has mentioned various treatment options such as *Shastrakarma*, *Agnikarma*, *Ksharakarma*, and *Ksharasutra*. Among these, *Ksharasutra* is now considered the gold standard of treatment. However, many patients find it inconvenient as it needs weekly follow-ups. Hence, the scope of advanced management techniques that imbibe classical concepts with clinical efficacy is essential. Thus, a novel method involving chemical cauterization by filling liquid *Kshara* into the fistulous tract was selected. *Kshara* has *Krimighna*, *Dushta mamsa satana*, *Tridoshaghna*, *Shoshana*, *Shodhana* as well as *Ropana gunas*.³ These properties of *Kshara* help in the expulsion of unhealthy tissues from the track through debridement and draining of pus. Its alkaline nature allows it to neutralize acidic conditions and creates a cleaner environment conducive to healing.

PATIENT INFORMATION

A 51-year-old male patient visited our Shalyatantra OPD with complaints of pimple-like lesion in the perianal region associated with pain and soiling of underclothes due to foul-smelling discharge. On anorectal examination, the external opening was seen at a 1 o'clock position approximately 1 cm from the anal verge. During the digital rectal examination, the internal opening was felt at noon. The MRI-perianal fistulogram was done to confirm the diagnosis. As per the MRI report, a curvilinear track is seen arising from the

anterior midline (12'o clock position) of the anal canal, 0.7cm above the level of the anal verge. The track is directed anteriorly and then vertically downwards to the left-sided external opening. Tract measures a length of 2.7cm and a diameter of 6mm. Hence, based on clinical findings and MRI-fistulogram, this case was diagnosed as *Riju Bhagandara* (Intersphincteric Low anal fistula). The patient was treated by filling liquid *Aragwadha Kshara* into the fistulous track.

THERAPEUTIC INTERVENTION

Pre-operative procedure

The procedure of the *Kshara* application was explained to the patient, and prior consent was obtained. A sodium phosphate enema was given 2 hours prior to the procedure. A tetanus toxoid injection and a local anaesthetic (2 % lignocaine) test dose were given. The patient was made to lie in a lithotomic position.

Operative procedure

Under aseptic precautions, the perianal region was painted with betadine solution, and draping was done. Local anaesthesia (2% lignocaine) was administered. A suitable probe was inserted into the external opening and directed to emerge from the anal orifice through the internal opening. The track length was noted, and the patency of the track was checked.

A slit proctoscope was used, and the anal canal and rectum were packed with gauze to prevent direct contact of *Kshara* with the normal mucosa. Liquid *Aragwadha Kshara* was injected into the fistulous track through the external opening using a 2 ml syringe. After waiting for *Vaksatha Matrakala*, the track was washed with *Nimbu swarasa* and saline water, and it was confirmed that all *Kshara* had been washed off. *Jatyadi Ghritha Varti* was inserted into the anal canal.

Post-operative measures

The patient was observed for four hours. Vitals were monitored and advised to take a sitz bath with *Triphala Kashayam* in the morning and evening for 15 minutes each time.

Assessment criteria

- A special performa was prepared to record observation, results and assess the effect of treatment.

- The assessment was done on subjective parameters like pain and objective parameters like tenderness and discharge.
- Patient was assessed every day after *Kshara* filling for 1 week.
- Follow up was done on 14th day, 21st day, 28th day, 35th day, 49th day, 63rd day, 77th day, and 91st day.

Results

During the evaluation, the patient showed notable improvement in pain, discharge, and tenderness.

- The patient had severe pain on the same day of *Kshara* infiltration. On daily evaluation, the patient experienced a slight improvement in pain. Maximum pain reduction was found on the 7th day, and on the 28th day, the patient experienced complete relief from the pain.
- The patient had severe tenderness during the first 3 days of treatment. Then, it gradually decreased, and on the 49th day, the patient got 90 % relief. Similarly, 100 % relief was found on the 63rd day.
- Since the first week of treatment, this method has shown good results in reducing discharge. On the 14th day, the patient got moderate relief from discharge. On the 21st day, the patient got complete relief from discharge.

DISCUSSION

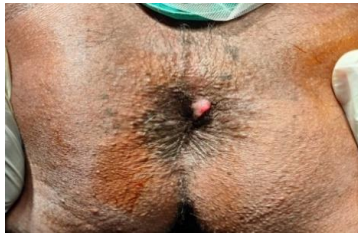Aragwadha Kshara infiltration showed promising results in the first week of the treatment. This helped

relieve discharge, reduce early pain, and complete fistulous track healing. The cryptoglandular hypothesis is the primary pathology in the Anal fistula.⁴ The correct identification of the site of cryptoglandular infection and its prompt eradication is important. As complete filling of liquid *Kshara* into the fistulous track helps in eradication of infective source. *Kshara* is highly caustic and has the ability to perform natural excision, incision and scraping. It is *Tridoshaghna*; thus, it helped to maintain the equilibrium of localised vitiated *Tridosha*.

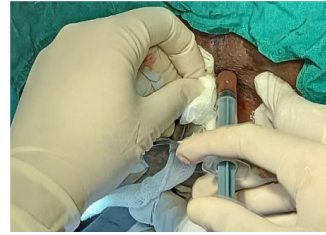
- *The Kshara* filling method is a less time-consuming, simple, and minimally invasive technique.
- No adverse effect was noted during the study period.
- It is an alternative treatment for patients unwilling to *Ksharasutra*.
- Standard protocol should be set regarding the duration of *Kshara* filling.
- The study can be done on more patients to observe for any recurrence with a longer follow-up duration.

CONCLUSION

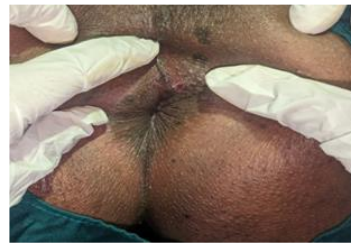From the above case study, it can be concluded that chemical cauterization is highly beneficial in the treatment of low anal fistula. This method can be effectively used in uncomplicated low anal fistulas with small tracts.



Before procedure



Kshara



After procedure

REFERENCES

1. Norman S Williams, P. Ronan O'Connell & Andrew W. McCaskie. Bailey & Love's Short Practice of Surgery, 27 ed. London: CRC Press; 2017.p.1363.
2. Sharma, P.V. Chakradatta. Third ed.2002; Varanasi: Chaukhamba Publisher;2002; p.373. 45/10-14.
3. Acharya Sushruta; Sushruta Samhita; Commentary by Dalhana; Gayadasa; Chowkambha Samskrita Samsthan; Varanasi, ed. reprint 2022; Sutrasthana, Ch 11/5, p.45.

4. Bhat MS. SRB's Manual of Surgery. 6th ed. New Delhi: Jaypee Brothers Medical Publishers; 2020. p. 971.ss

Source of Support: Nil

Conflict of Interest: None Declared

How to cite this URL: *Athira. K et al: Effect of chemical cauterization in anal fistula by filling liquid Aragwadha Kshara -A case report. International Ayurvedic Medical Journal* {online} 2025 {cited January 2025} Available from: http://www.iamj.in/posts/images/upload/272_275.pdf