



A RARE ANATOMICAL VARIATION OF BILATERAL BICIPITAL ORIGIN OF PLANTARIS MUSCLE: A CASE REPORT

Bhumika Rudani¹, Vikash Bhatnagar², Sandeep Madhukar Lahange³, Shailza Bhatnagar⁴, Anjali Sharma⁵, Tamanna Gumber⁶, Anita Bochalya⁷

M.D. Scholar¹, Professor², Associate professor^{3,4}, M.D. Scholar^{5,6,7}

PG Dept of *Rachana Sharir*, National Institute of Ayurveda, deemed to be University (*De-novo*)
Jaipur, Rajasthan

Corresponding Author: bhumirudani30@gmail.com

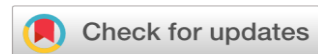<https://doi.org/10.46607/iamj3111102023>

(Published Online: October 2023)

Open Access

© International Ayurvedic Medical Journal, India 2023

Article Received: 08/08/2023 - Peer Reviewed: 25/08/2023 - Accepted for Publication: 10/09/2023.



ABSTRACT

The posterior calf group, plantaris muscle has a small fusiform muscle belly and a long slender tendon sandwiched between the soleus and gastrocnemius muscles. The case was reported during routine dissection at National institute of Ayurveda Deemed university, Jaipur. The subject was 31year-old male cadaver of north Indian origin. The Bilateral Bicipital origin of Plantaris Muscle was observed during the cadaveric dissection of the popliteal region. Two distinct PMS (Plantaris Muscles) were present, the SPM (superior Plantaris Muscle) and IPM (Inferior Plantaris Muscle). While the SPM originates from the lower lateral supracondylar ridge and the knee capsule, the IPM originates from the femoral condyle and SPM tendon splitting in to one part at the distal belly. The lateral side of the IPM tendon travels between GM (Gastrocnemius Muscle) and SM (Soleus Muscle) and ends at the calcaneal tendon. SPM and the medial side of the IPM tendon run along with the IPM tendon and insert at the fascia at the inner surface of proximal 1/3of the medial head of GM. The present case report introduces a new variation of the PM that should be taken into consideration.

Keywords: Plantaris muscle, Anatomical variation, Bilateral Bicipital origin

INTRODUCTION

The plantaris muscle comprises of a long, thin tendon and a small thin muscular belly between the soleus and gastrocnemius muscles is the plantaris muscle. Triceps surae is the collective name for the plantaris muscle, gastrocnemius muscle, and soleus muscle. The lateral supracondylar line of the femur, which is superior and medial to the lateral head of the gastrocnemius muscle, and the oblique popliteal ligaments in the back of the knee are where the muscle originates.¹ The tibial nerve, a branch of the sciatic nerve, supplies it with nerves. It is also known as "freshman nerve"² because medical students frequently mistake it for a nerve. The oblique popliteal ligament may serve as the genesis of the plantaris muscle. It is not rare for the muscle to interdigitate with the lateral head of the gastrocnemius and to extend fibrously to the patella.³

MATERIAL AND METHOD : During routine dissection of approximately 31-year-old male cadaver of North Indian origin, the Bilateral Bicipital origin of Plantaris Muscle was identified in both lower limb and carefully traced to avoid any harm to its surrounding structures. We first performed the blunt dissection followed by fine dissection. The origin, insertion and its nerve supply were carefully noted down during routine dissection at Department of Rachana Sharir, National institute of Ayurveda Deemed university, Jaipur.

CASE REPORT

While doing cadaveric dissection it was observed that the Plantaris was seen taking origin from lateral condyle of Femure and a long slender tendon along with Superior PM and Inferior PM. SPM originates from the lower lateral supracondylar ridge and the knee capsule. And IPM originates from the femoral condyle. as shown in fig.1 and fig.2 the tendon of SPM splitting into one part at the distal belly. The lateral side of the IPM tendon travels between Gastrocnemius and Soleus and ends at the calcaneal tendon. SPM and the medial side of the IPM tendon run along with the IPM tendon and insert at the fascia at the inner surface of proximal 1/3 of the medial head of Gastrocnemius muscle.

LEFT SIDE OBSERVATION

When the PM was exposed, we found two distinct PMs with their own muscle bellies and tendon. The superior PM from the lower lateral supracondylar ridge and the inferior PM (IPM) originated from the knee joint capsule and the lateral head of GM indirectly attached to the lateral femoral condyle and SPM tendon. it splits in to one part With the IPM tendon travels inferomedially Between GM and SM and eventually inserted at the calcaneal tuberosity along with the calcaneal tendon. The medial side of SPM merges with the IPM tendon and its tendon travels along the IPM tendon until proximal 1/3 of the medial head of GM.

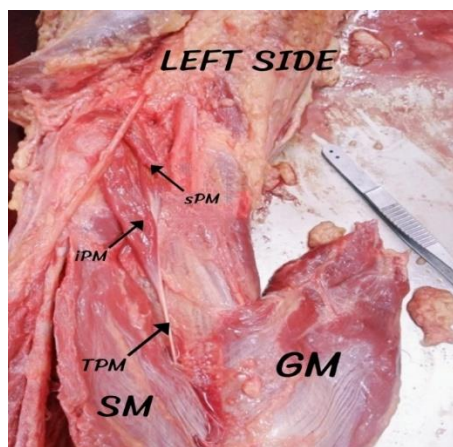


Fig.1 shows the appearance of the plantaris muscle in the left side of the case.

sPM- superior plantaris muscle, iPM- inferior plantaris muscle, TPM-tendon of plantaris muscle, SM-Soleus muscle, GM-Gastrocnemius muscle.

RIGHT SIDE OBSERVATION

In this side, we found two distinct PMs with their own muscle bellies and tendon. The superior PM (SPM) from the lower lateral supracondylar ridge and the inferior PM (IPM) originated from the knee joint capsule and the lateral head of GM indirectly attached to the lateral femoral condyle and SPM ten-

don. it splits in to one part With the IPM tendon travels anteromedially Between GM and SM and eventually inserted at the calcaneal tuberosity along with the calcaneal tendon .the medial side of SPM merges with the IPM and its tendon travel along the IPM until proximal 1/3 of the medial head of GM .

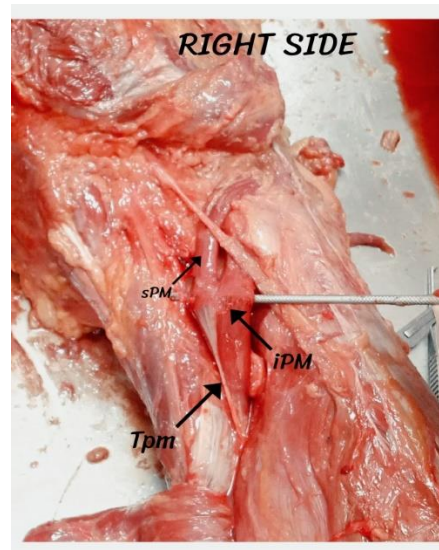


Fig.2 shows the appearance of the bilateral origin plantaris muscle in the right side of the case SPM- superior plantaris muscle, IPM- inferior plantaris muscle, Tpm-Tendon of plantaris muscle.

DISCUSSION

The PM has a small spindle –shaped muscle belly and a long slender tendon .it typically originates from the lateral supracondylar ridge of the femur above the lateral head of GM and inserts at calcaneal tuberosity. Its tendon travels inferomedially between GM and SM, which comprise the triceps surae muscle group working as a flexor of the knee and ankle along with PM. However, recent studies consider PM a proprioceptive organ due to its high density of muscle spindles. Moreover, the muscle may be absent (10%)⁴ or twice, according to conventional textbooks. For the clinical diagnosis of muscle rupture and the interpretation of an MRI scan⁵, precise anatomical understanding of the plantaris muscle is crucial. In plastic

and reconstructive procedures, the tendon of the plantaris muscle makes a great graft material.^{6 -7} All physicians must be aware of the morphological variety of this muscle since the plantaris tendon's course can result in Achilles tendinopathy and because this tendon is utilised to rebuild other tendons and ligaments. In recent years, it has been suggested that the muscle rupture should be referred to as a "tennis leg" Whatever the situation, it is generally known that excessive triceps surae contraction and extension might harm the plantaris muscle. However, in the absence of an MRI and an ultrasound, this could be mistaken for deep vein thrombosis or a triceps surae muscle injury. The preferred treatment for "tennis leg" at the moment is non-surgical. However, if the injured

plantaris muscle is removed during the super-acute phase or if the muscle is simply gone, symptoms may improve more quickly.

The variation of plantaris muscle, also described as crossing of the neurovascular bundle can result in a tibial nerve compression⁸ although many of the mainstream textbook in china does not include it. around 10% of people are thought to lack the planter. Researchers have proposed that the plantaris muscle initially linked to the planter aponeurosis, but that during the course of evolution, its position “shifted backward “for example, a plantaris muscle loop may be used treat lower limb venous insufficiency. This loop is superior to the

Semitendinosus-biceps femoris loop and the pedicled fascia lata loop in terms of rejection risk, material choice and performance. Additionally, there is a possibility that the plantaris muscle will be used in the future to correct heart valve abnormalities via autologous transplantation. The plantaris muscle tendon typically inserts into the calcaneal tendon. There has been a discernible rise in calcaneal tendon disease instances in recent years, and this affects the general population as well as athletes, with accompanying weakness and functional impairment. Only 34% of asymptomatic tendons showed histopathological abnormalities. In fact, several researchers have suggested that the aetiology of this condition was directly related to the insertion of the plantaris muscle. The excision of the plantar muscle, its surrounding soft tissue, and its tendon, along with a decrease in tendon tension, have been linked in recent research to successful treatment of chronic pain in the centre of the calcaneal tendon. Additionally, one year later, follow-up is still satisfactory. The plantaris muscle is degenerative from a morphological perspective, as seen by a short muscular belly and elongated tendon. The muscle has thus been unable to adjust to quick muscular contraction. The so-called "tennis leg," which includes swelling and severe leg pain, may be caused by the passive stretching of the plantaris muscle, particularly when the knee joint is extended and the ankle is flexed less than 90 degrees, according to relevant study. In fact, middle-aged people in poor

physical condition, as well as athletes, people who exercise a lot, etc., can develop a violent plantar flexion injury that ruptures the plantaris tendon.

On the other hand, some researchers contend that the plantar muscle is likely to make up the proprioceptive organ of the larger, more potent plantar flexors because of its high-density muscle spindle. This is due to the fact that most narrow tendons govern finer motor activities rather than producing power. In contrast, the absence of the plantar muscle may increase the risk of injury to the major stable knee ligaments due to increased knee relaxation during lateral and medial rotation and weakened initial knee flexion. Resection, absence, or transplanting of the plantar muscle is all associated with high scientific value and broad potential applicability for disease treatment. The absence of the muscle and its tendon obviously makes transplanting and removal impossible, but the plantaris muscle's prospective graft condition can be checked using pre-operative US or MRI. Case reports will also provide clinical references.

CONCLUSION

A PM with an unusual genesis and a course were given. It could resemble a mass in the popliteal region because of its superficial alignment. A long and twisting trajectory could make it more prone to harm.

REFERENCES

1. Delgado GJ, Chung CB, Lektrakul N, Azocar P, Botte MJ, Coria D, Bosch E, Resnick D. Tennis Leg: Clinical US Study of 141 Patients and Anatomic Investigation of Four Cadavers with MR Imaging and US. *Radiology*. 2002; 224:112–19
2. Moore KL, Dalley AF, editors. *Clinically Oriented Anatomy*. 5th Ed. Philadelphia: Lippincott Williams & Wilkins; 2006. pp. 648–9.
3. Freeman, A. J.; Jacobson, N. A.; Fogg, Q. A. (2008). "Anatomical variations of the plantaris muscle and a potential role in patellofemoral pain syndrome". *Clinical Anatomy*. 21 (2): 178–81.
4. Standring S, ed. *Gray's Anatomy. eAnatomical Basis of Clinical Practice*. 39th Ed., Philadelphia, Elsevier Churchill Livingstone. 2005; 1499.

5. Spina AA. e plantaris muscle: Anatomy, injury, imaging and treatment. J Caa Chiropr Assoc. 2007; 51: 158-65
6. Pagenstert GI, Valderrabano V, Hintermann B. Lateral ankle ligament reconstruction with free plantaris tendon graft. Techniques in Foot & Ankle Surgery. 2005; 4: 104-12.
7. Shuhaiber JH, Shuhaiber HH. Plantaris tendon graft for atrioventricular valve repair: a novel hypothetical technique. Tex Heart Inst J. 2003; 30: 42-4.
8. The plantaris muscle — rare relations to the neurovascular bundle in the popliteal fossa Ł. Olewnik¹, M. Podgórski², M. Polgúj³, M. Topol Folia Morphol. Vol. 77, No. 4, pp. 785–788 DOI: 10.5603/FM.a2018.0039

Source of Support: Nil

Conflict of Interest: None Declared

How to cite this URL: Bhumika Rudani et al: A Rare Anatomical Variation of Bilateral Bicipital origin of Plantaris Muscle: A Case Report. International Ayurvedic Medical Journal {online} 2023 {cited October 2023} Available from: http://www.iamj.in/posts/images/upload/2589_2593.pdf