

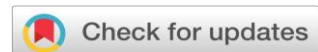AYURVEDIC MANAGEMENT OF CERVICAL EROSION THROUGH YONIPRAKSHALANA WITH TRIPHALAADI KWATH, APAMARGA KSHARA PRATISARANA, AND PANCHVALKALDI TAILA YONI PICHU - A CASE STUDY**Preeti Garg¹, K. Bharathi²**

¹Final Year PG Scholar, Prasuti Tantra and Stree Roga Department, National Institute of Ayurveda, Jaipur, Rajasthan, India

²Head of PG Department of Prasuti Tantra and Stree Roga Department, National Institute of Ayurveda, Jaipur, Rajasthan, India

Corresponding Author: PREETY.PG90@GMAIL.COM<https://doi.org/10.46607/iamj4610052022>**(Published Online: May 2022)****Open Access**

© International Ayurvedic Medical Journal, India

Article Received: 29/04/2022 - Peer Reviewed: 01/05/2022 - Accepted for Publication: 02/05/2022**ABSTRACT**

Cervical erosion has been seen as a commonest in gynecological clinics. In the initial stage, it is asymptomatic but later on can cause symptoms like white discharge per vaginum, pruritis vulva, low back, pelvic pain, dyspareunia, etc. These symptoms can adversely disturb the physiological, psychological health even professional life of the women. When the squamous epithelium of the ectocervix is replaced by the columnar epithelium of endocervical length, is known as Cervical erosion. Cervical erosion can be correlated with two conditions based on the clinical features, one is *Karnini yonivyapad* (Erosion of recent origin) and the other one is *Deergha Kalanubandha Vrana* (Chronic Erosion), and this present case study is diagnosed with *Karnini yonivyapad* i.e., erosion of recent origin. A 42-year-old female patient came in PTSR OPD, Jaipur, with complaints of foul-smelling excessive irritant thick whitish discharge per vaginum with itching valva, low back pain, and pelvic pain for 7 months. She took allopathic treatment for that but didn't get complete relief. The doctor also advised for hysterectomy. But she was not willing to a hysterectomy, and she opted for Ayurvedic treatment. In this case study, the patient with cervical erosion was treated with Ayurvedic *Sthanika chikitsa- Yonidhavana* by *Triphalaadi kwatha*, *Apamarga kshara pratisarana*, and

panchvalkali taila yoni-pichu for 5 alternative days. After this combined Ayurvedic therapy of *Sthanik chikitsa* cervical erosion as well as associated symptoms have been completely cured.

Keywords: Cervical erosion, *Karnini yonivyapad*, *Yoniprakshalana*, *Kshara pratisarana*, *Yonipichu*.

INTRODUCTION

Cervical erosion is a gynecological problem in which the squamous epithelium of the ectocervix is replaced by the columnar epithelium, which is the continuation of the endocervix (Endocervical canal) which is more prone to infection. Due to increasing chances of infection, there are also more chances of malignancy¹. Cervical erosion has a 35-80 % incidence in the reproductive age of the woman². Cervical erosion is of two types. Congenital ectopy mostly heals spontaneously. Acquired ectopy occurs mainly due to an elevated level of the estrogen hormone. This condition is often observed during pregnancy and amongst birth control pill users. Infection can also play an important role in erosion because the delicate columnar epithelium is more vulnerable to trauma and infection. The lesion of cervical erosion may be asymptomatic in the early stage. But later on, many symptoms can be noted like vaginal discharges which may be excessively mucoid, mucopurulent, offensive, and maybe even blood-stained due to premenstrual congestion. Bleeding during contact especially occurs during pregnancy and pill users, back pain, pelvic pain, and sometimes infertility may be produced³. In modern system medicine, long-time taking therapies like diathermy cautery, and cryosurgery are applied. But none of the above therapies are satisfactory in treating cervical erosion and occasionally cause side effects like excessive vaginal discharges. Cervical erosion is a benign condition but if left untreated may predispose to cervical malignancy. That's why it is important to pay attention to this troublesome disease and to detect these lesions early enough and treat them adequately.

There is no direct description found in the reference to cervical erosion. But due to symptoms and signs, it can be correlated with two conditions one is *Karnini yonivyapad* (Erosion of recent origin)⁴ and the other one is *Deergha Kalanubandha Vrana* (Chronic Erosion). It occurs due to bearing down straining during

labor in the absence of true labor pains i.e., *Akalavahana*⁵. In this condition, the vitiated *vayu* is obstructed by the fetus, withholding *kapha dosha* and getting mixed with *Rakta dhatu* and producing *karnika* in *Yoni*. *Karnika* which is made in *yonis* can be correlated to the erosion of the cervix which may slightly be elevated above the level of the squamous epithelium of the vaginal portion of the cervix. Later on, it becomes granular in appearance which gives a grating sensation while touching. Due to excessive taking of *vata vardhaka* diet, *Kha-vaigunya* takes place in the *artavaha-srotas*. After that *Dosha- dushya-murchana* takes place due to this vitiated *vayu dosha* gets mixed *kapha* and *rakta*. This disease has *Garbhashaya-dwaramukha* i.e., Cervix as *adhistan*. *Karnika* is formed on the *Garbhashaya-dwaramukha* in the phase of *Vyakta-avastha*, which is a cardinal feature of *karnini yonivyapad*. In Ayurvedic text *karnika* is described as *Mansakandi*, *Granthi*, *Mansankura*, *Mansakandakar granthi* etc. The line of treatment has followed this case to treat the provoked *kaphadosha* and vitiated *raktadhatu*. In this present case study Ayurvedic *Sthanik chikitsa- Yonidhavan* by *Triphalaadi kwath*, *Apamarga kshar pratisarana*, and *Panchvalkali taila pichu* were given. *Triphaladi kwath* contains *Triphala churna*, *Vidanga churna*, and *Sphatika bhasma*. *Triphala* is having *tridoshshamaka* specially *kaphapittashamaka*, *grahi*, *shoshaka*, anti-inflammatory, and antibacterial properties. *Vidang* is also known as *Krimighna*, *Jantunashan* and is having *kriminashaka*, antifungal, antibacterial properties also it pacifies *Kapha* and *Vata dosha*. *Sphatika bhasma* includes *kaphashamaka*, *Vrana ropana* (wound healing), *daha-hara* (relieves burning sensation), anti-inflammatory, anti-microbial, anti-hemostatic, astringent, antioxidant properties. It also promotes tissue regeneration. *Kshara*⁶ means *Ksharana* i.e., cut off the unhealthy part. *Apamarga kshara* contains *Lekhana*, as well as

Ropana properties, and these properties work simultaneously. Apamarga kshara has strong alkaline nature and corrosive action, due to which it brought the destruction of superficial tissues of eroded cervix followed by sloughing off of unhealthy tissues and cells. It also helps in the re-epithelialization of squamous epithelium easily. Lastly, Panchvalkali taila yoni Pichu has kaphapittashamaka, antiseptic, anti-inflammatory, antibacterial, antimicrobial, wound purifying and healing, and astringent properties. Panchvalkali includes kashya rasa which it's having stambhana properties and shows static action on vaginal discharges. It also contains tannin which acts as an anti-inflammatory dravya that inhibits enzymes such as 5-lipo-oxygenase and hyaluronidase and modifies intracellular signaling pathways in the immune system.

CASE STUDY

OBJECTIVE: To study the effectiveness of yoniprakshalana with triphalaadi kwath, apamarga kshara pratisarana, and panchvalkali taila yoni-pichu in the management of cervical erosion.

STUDY DETAILS

Name of patient- XXX

Date of the first visit- 22/7/2021

Age-42 Years

Religion- Hindu

Occupation- Housewife

CHIEF COMPLAINTS WITH DURATION

- Foul-smelling excessive irritant thick whitish discharge per vaginum with itching valva for 7 months.

- Low backpain and pelvic pain for 6 months.

HISTORY OF PRESENT ILLNESS

According to the patient, she was asymptomatic 7 months back. Gradually she developed complaints of foul-smelling excessive irritant thick whitish discharge per vaginum with itching valva. She had also complaints of low back pain and pelvic pain. She had taken allopathic medicine for that but didn't get complete relief. The doctor also advised for hysterectomy. But she was not willing to the hysterectomy, and she opted for Ayurvedic treatment. She visited PTSR OPD of NIA, Jaipur, for proper investigation and Ayurvedic management.

HISTORY OF THE PATIENT

Personal history

- Diet-Vegetarian
 - Appetite-Normal
 - Bowels- Regular
 - Bladder-Normal micturation
 - Sleep- Sound
 - Medication- Taking oral hypoglycemic drug (Metformin-500 mg BD) for 3 years, Thyroxin- 112 mg since 2013
 - Addiction-Not any
 - Past medical/surgical history-Not significant
 - Family History- Not significant
- Menstrual and Marital History -**
Menarche-At the age of 13 years
LMP -22/08/2021

Menstrual History

Duration of menses blood flow	5 days
Intermenstrual Interval	28-30 Days
Regular/ Irregular	Regular
Flow	Normal
Colour	Red
Pain	Absent
Clots	Absent
Smell	Absent
Any other complaints	No

- Married life- 19 years
- Obstetrics History • G6 P4 L3 D1 A2
- Last Delivery - Fullterm Cesarean section, Female Child, 8 Years back, all children are healthy.

ASHTAVIDHA PARIKSHANA (EIGHT FOLDS OF EXAMINATION IN AYURVEDA)

- *Nadi* (Pulse) - 82/min, regular.
- *Mala* (Stool) – *Nirama*
- *Mutra* (Urine) – In daytime-8-10 times, On Night-2-3 times, Pale yellow
- *Jivha* (Tongue) – *Nirama*
- *Shabda* (voice) - *Prakruta & Spasta*
- *Sparsha* (Touch) - *Sama Shitoshna*
- *Drika* (vision) - *Prakruta*
- *Aakruti* (Body proportion) - *Madhyama*

PHYSICAL EXAMINATION GENERAL EXAMINATION-

- Height- 155cm
 - Weight- 65 kg
 - BMI- 27.2
 - B.P- 110/70 mm Hg
 - Average built and nourished
 - Pallor- Nil
 - Nails, tongue, and conjunctiva- Pink
 - No evidence of lymphadenopathy, icterus
- Systemic Examinations
- Respiratory system – Air entry bilateral clear
 - Cardiovascular system – S1 S2 audible
 - Central nervous system – Conscious

P/ S EXAMINATION-

Cervix – Erosion + + + +
Thick white discharge + +
Foul smell present

P/V EXAMINATION-

Uterus- Anti-verted, Anti-flexed, Normal sized
Cervix- downward, soft, Hypertrophied
Fornix- tenderness + + + +

INVESTIGATION-

1. PAP SMEAR- 24/7/2021: Smear comprised of intermediate and superficial squamous epithelial cells in the background of acute inflammatory infiltrate. Endocervical cell clusters are present, showing squamous metaplasia in a few places. On overall impression, the smear showed inflammation.

2. Hb- 11.6 gm%
3. RBS- 180 gm/dl
4. Liver function test, Renal function test, Lipid profile- Within normal range.

THE TREATMENT SCHEDULE FOR THE PRESENT STUDY

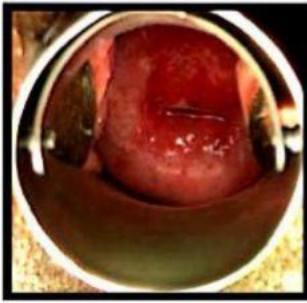
Principle of Treatment- Treatment should be *agni deepaka, ama pachana, vatashamaka, and kaphashamaka*.

1. *Nidana Parivarjana* (Elimination of Causes): - Complete history taken and eliminate possible causes of the disease, like faulty dietary habits, fast food, *abhishyandi* like *dadhi, ati-amla aahara*, late-night sleeping, overthinking, *Viruddha Aahara, Vegvidharan* (withholding natural urges like stool, urine). *Nidan parivarjan* is the first treatment mentioned in the first chapter of *Sushruta's Uttarantra*⁷.
2. *Aahar Vyavastha* (Dietary Changes)- Advice use a diet of green leafy vegetables, *jau* (barley), Bitter gourd, green gram (*Mudga*), *Purana Shali* rice, Cow's milk & ghee in the diet and seasonal fruits, plenty of water, because food is great medicine (Acharya *Kashyapa* mentioned that *Aahar* is *Mahabhaishajya*).
3. **TREATMENT** –
 - ✓ *Sthanika chikitsa* –
 - *Apamarga kshara pratisarana* to destroy the erosion.
 - *Yonidhavan* with *Triphaladi kwath* (*triphla churna + vidang churna + sphatika bhasma*) to combat infection.
 - *Panchvalkali taila yoni-pichu* for healing of erosion.

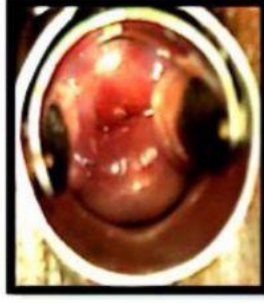
These three *Karmas* were done as a combined therapy in patient and this treatment was done for 5 days after menses.

- ✓ Oral medication- *Triphala guggulu* – 2-tab BD

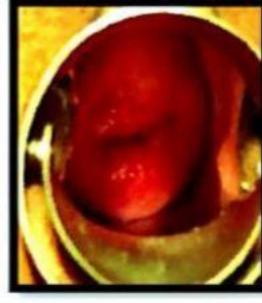
RESULT



Before Treatment



During Treatment



After Treatment

DISCUSSION

Cervical erosion needs the urgent attention of gynecologists as it affects women's day-to-day activity and thereby upsets the patient psychologically. If cervical erosion is symptomless then there is no need for treatment. But when it is symptomatic and infected then urgent treatment is needed. Modern medical science having treatment for cervical erosion is cauterization & cryosurgery which have their own side effects like bleeding per vaginum, secondary infertility, stenosis, infection, etc. Cauterization is a more costly and invasive procedure that is not affordable for all patients. That is why the Ayurvedic therapy *ksharakarma* is getting valued and used.

This cervical erosion can be correlated with *Karnini yonivyapad* and Acharyas described that the treatment of *Karnini yonivyapad* should be *vatahara*, *kaphahara*, and *Shodhana*. In this case, *Triphaladi kwath yoniprakshalana* became helpful to combat microbial growth (infection) with excessive discharge and reduction of disease, because this has *kaphapitta shamaka*, *grahi*, astringent, antibacterial, and antifungal properties. *Apamarga kshara* played the most important role in the process of the destruction of superficial tissues of eroded cervix followed by sloughing off of unhealthy tissues and healing by its *Ksharana*, *Lekhana*, and *Ropana* properties. After that *Panchvalkali taila* helped in the healing of the eroded area. properties of all the above-mentioned *dravyas*, the patient got complete relief from the erosion of the cervix also got the normal appearance of the cervix and the symptoms

like white discharge per vaginum, low backache, etc also cured.

CONCLUSION

We can prevent the incidence of cervical erosion by educating the women for improving their general health and personal hygiene. The *Sthanika chikitsa* mentioned in Ayurvedic texts like *yoniprakshalana*, *yonipichu*, *yonidhupana*, *kshara* application play an important role in curing cervical erosion and other infections also. *Apamarga kshara karma* gave the best result in cervical erosion associated with other *karma* like *prakshalana*, and *yonipichu*. After using this procedure recurrence of cervical erosion is not possible and it also helps to cure the secondary infection. This *Sthanika* treatment has no side effects and is cost-effective also.

REFERENCES

1. D. C. Dutta's Textbook of Gynecology including contraception, New Central Book Agency (P) Ltd, 6th edition, Benign Lesions of the Cervix Chapter-18, pp.267
2. Akanksha Mahesh Naik et al. Ayurvedic management of cervical erosion through Yonidhavan with Triphala and Daruharidra kwath, Apamarga kshar pratisaran with Jatyadi tailpichu
3. D. C. Dutta's Textbook of Gynecology including contraception, New Central Book Agency (P) Ltd, 6th edition, Benign Lesions of the Cervix, Chapter-18, pp.268
4. Charak Samhita, chaukhamba sanskrit prakashan, Dvitiya bhag – Chikitsasthan, Pp. - 742
5. Charak Samhita, chaukhamba Sanskrit prakashan, Dvitiya bhag – Chikitsasthan, Chapter-30 Pp. - 742

6. Sushruta Samhita, chaukhamba Sanskrit prakashan, Prathama bhag – Sutrasthana, Chapter-11 Pp. - 233
 7. Sushruta Samhita, chaukhamba Sanskrit prakashan, Dvitiya bhag – Uttaratranta, Chapter-1 Pp. – 54
-

Source of Support: Nil

Conflict of Interest: None Declared

How to cite this URL: Preeti Garg & K. Bharathi: Ayurvedic Management Of Cervical Erosion Through Yoniprakshalana With Triphalaadi Kwath, Apamarga Kshara Pratisarana, And Panchvalkali Taila Yoni Pichu - A Case Study. International Ayurvedic Medical Journal {online} 2022 {cited May 2022} Available from: http://www.iamj.in/posts/images/upload/1384_1389.pdf