

BILATERAL PRE-HILAR BRANCHES OF THE RENAL ARTERIES – A CADAVERIC STUDY

Kanthy G M¹ Dayana H P G Scholar²

¹Prof. Dept of P.G. Studies in Shareera rachana, SDM College of Ayurveda, Udupi, Karnataka, India

²Final year P G Scholar (Rachana sharira),SDM College of ayurveda, Udupi, Karnataka, India

ABSTRACT

Each kidney is supplied by renal artery arising from the abdominal aorta. The renal artery gives branches within the hilum before entering or after entering the kidney. Some time there may be prehilum branches and they may run towards the upper or lower pole of the kidney. During the routine abdominal dissection in the department of anatomy, anatomical variations of renal artery branches were noted. After arising as a single renal artery from the abdominal aorta the renal artery divided into three divisions on the right side and two divisions on the left side. The divisions were not near the hilum of the kidney. The details of early branching of the renal artery and its importance are discussed in this study.

Key words- Renal artery; Hilar branches; Extra hilar branches

INTRODUCTION

The renal arteries are large trunks which arise from the lateral aspect of abdominal aorta. The right artery is longer and passes posterior to the inferior vena cava, right renal vein, head of pancreas and descending part of duodenum. Left is a little higher, lies posterior to left renal vein, body of the pancreas and splenic vein¹. Upon or before reaching the hilum of the kidney the renal artery on each side divides into anterior and a posterior division. The primary branches of the divisions supply the vascular segments of the kidney. The vascular segments are supplied by arteries which have virtually no anastomosis between their neighbours and are known as end arteries. In contrast the larger intra renal veins have no segmental organization and anastomose freely.²

The classical description of the renal vasculature, formed only by one artery and one vein, occurs in less than 25% of cases. Most often encountered

morphological variations of renal artery are its variable number and unusual branches originating from it. Most of these variations remained undiscovered until being noticed during any surgical procedure or found by forensic pathologist during autopsy. In this case report we report the unusual variation in the branching pattern of renal vessels during cadaver dissection.

According to the nomenclature adopted by Sampao and Passosin 1992 extra hilar arteries are branches of renal arteries that present an extra hilar penetration in the superior or inferior pole.³

Methodology

The dissection of male cadaver was carried in the Dept of Anatomy as per Cunningham's manual. The abdominal dissection was started as layer of skin, fascia, abdominal muscles aponeurosis with blood vessels and its nerve supply. Then peritoneum and organs one by one, reached to the posterior abdominal wall.

Their we identified the blood vessels supplying to the both kidneys, there are some variation of blood vessels which are supplying to the both kidneys. We studied the renal vessels variation in their course and branching pattern in this cadaver and discussed as follows.

Observations –

During the routine abdominal dissection in the department of Anatomy, to the Post graduate students, of S D M College of Ayurveda Udupi, The 85 years old male cadaver abdominal dissection was carried and dissected anterior abdominal wall with muscles and organs. When we reach the kidney organs we observed the renal vessels variation and its course. The right and left renal arteries showed early branching pattern before it reaches to the hilum of the kidneys. The main renal artery enters the kidney through hilum and some branches that are prehilar enters through one of its poles of both kidney.

Observations of Right Kidney –

1. The right kidney has three supernumerary renal arteries branching

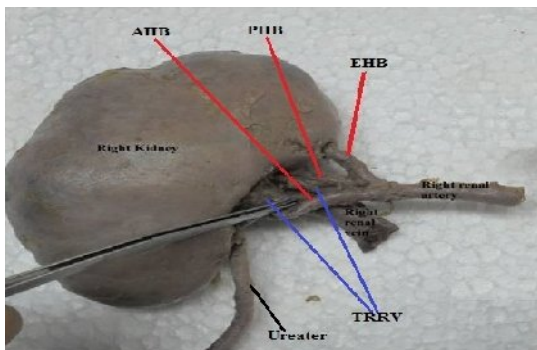


Figure 1- Photography showing Prehilar division of right renal artery (AHB - Anterior Hilar Branch, PHB -Posterior Hilar Branch, EHB - Extra Hilar Branch, TRRV- Tributaries of

from the main renal artery. One extra hilar branch directed towards the upper pole and enters the upper pole. The other two hilar branches enter the kidney as anterior & posterior aspect of the kidney.

Observations of Left Kidney –

1. The left kidney has two supernumerary renal arteries from main renal artery one branch to hilar and one branch extra hilar directed towards the upper pole and enters the upper pole of the kidney.

Both the renal veins and ureters were found to be anatomically normal in location and arrangement. Renal vein received two tributaries near the hilum of both the kidneys

There is a variation in the arrangement of renal arteries in this case. Here the arteries supplying the apical vascular segment branched out from the renal artery before reaching the hilum on both sides as per nomenclature adopted by Sampao and Passosin it was named as upper polar artery.

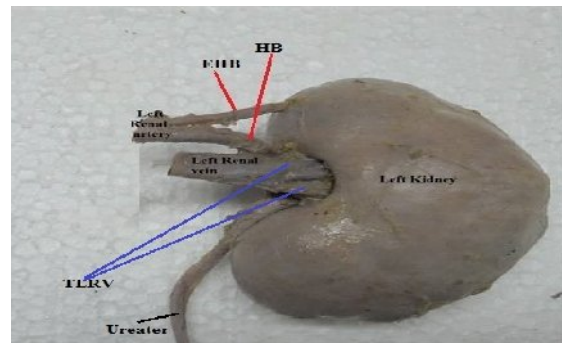


Figure 2 - Photography showing Prehilar division of left renal artery (EHB - Extra Hilar Branch, HB - Hilar Branch, TLRV- Tributaries of Left Renal Vein)

DISCUSSION

Shoja M M et al, studied the pre hilar branching pattern of renal artery.

They reported four different patterns of branching of renal artery. They were fork pattern in 92.6% of kidneys, duplicate in

80.2%, triplicate in 12.4%, and ladder pattern in 7.4% of kidneys.

Healy J C et al stated that the renal vascular segment was originally recognized by John hunter in 1794, but first detailed account of primary pattern was produced during 1950's from casts and radiographs of injected kidneys. Five arterial segments have been identified. They were apical, superior, middle, inferior, and posterior segments.⁴

Embryological explanation of these variations has been presented and discussed by Felix. In an 18 mm foetus, the developing mesonephros, metanephros, suprarenal glands, and gonads are supplied by nine pairs of lateral mesonephric arteries arising from the dorsal aorta. Felix divided these arteries in to three group as follows 1st and 2nd arteries as cranial, 3rd to 5th arteries as middle, and 6th to 9th arteries as caudal group. The middle group gives rise to renal arteries. Satyapal have demonstrated that 39% of renal veins consists of two primary tributaries.⁵

Merklin and Michels classified the supernumerary renal arteries depending upon its origin as 1) supernumerary renal arteries originating from aorta, 2) supernumerary renal arteries originating from

the main renal arteries and 3) supernumerary renal arteries originating from other arterial sources. Upper polar and lower polar supernumerary renal arteries originating from renal arteries directed towards superior or inferior pole, have vertical trajectory in comparison to supernumerary renal arteries taking origin from aorta. Vertical trajectory of these arteries can lead to polar infraction and they can also be injured during mobilization and other surgical procedures. Lower polar supernumerary renal arteries of aortic or renal origin can be a cause of ureteropelvic junction obstruction.⁶

Apparently, these arteries anatomical variations do not interfere in renal function and should be differentiated from vascular malformations or anomalies that may cause renal or systemic functional disorders.⁷

The complex vascular anatomy of the kidney and high prevalence of vascular variations reinforce the need for accurate preoperative vascular imaging in transplantation.

Prehilar division of artery studied and observed by different Research Scholars

Study carried out by different research scholar	Percentage of Prehilar division of renal artery
1) Virendra B. Scholar in 2010	11.66 % cases of prehilar division of renal artery identified.
2) Budhiraja V in 2013	33.3% on right side, 28.5% on left side, Cases of prehilar division of renal artery identified
3) Rakhi Rastogi in 2013	12.2% (HSA-8.1%,UPSA-2.7%, LPSA- 1.4%) Cases of prehilar division of renal artery identified
4) Sofiya Sabouri in 2011	16.5% Cases of prehilar division of renal artery identified

(Note 1:-HSA: Hilar Supernumerary renal Artery, UPSA: Upper Polar Supernume-

rary renal Artery, LPSA: Lower Polar Supernumerary renal Artery.)

Adequate preoperative living kidney donor evaluation is mandatory to reduce the possible occurrence of surgical complications that can threaten the graft and sometimes the survival of the patient. Successful transplantation requires through evaluation of condition of transplantation candidate, anatomic variations and abnormalities that may alter the surgical approach.⁸

Thus the awareness of variations in renal vessels is necessary for surgical management during renal transplantation, repair of abdominal aorta aneurysm, and urological procedures and for angiographic interventions.

CONCLUSION –

1. The renal artery variation that is pre-hilar branches was identified and noted its clinical and surgical importance.
2. The identification of such variations is an important knowledge in the field of clinical anatomy.
3. Renal vasculature often shows variations from classical description. Occurrence of pre-hilar division of artery and its upper polar presentation is not a rare finding. The awareness of such variations in renal vessels is necessary for surgical management during renal transplantation; repair of abdominal aorta aneurysm and urological procedures and for angiographic interventions.

REFERENCES

1. Henry Gray, Gray's Anatomy 36th Edition – 1980. Pp .718
2. Henry Gray, Gray's Anatomy 36th Edition – 1980. Pp.1396 – 1397.
3. Budhiraja V, Rastogi R., Bankwar. Anatomical variation of renal artery and its clinical correlations: a cadaveric study from central India. J.Morphol. Sci, 2013; 30: 228-233.
4. Amudha Govindarajan, VimalaVel-laichamy; A case report on the pre hilar branching of right renal artery with variations in the hilar architecture of the right kidney and the origin of right testicular artery; IJMHS:2014 March-April,4: 56-58.
5. Dr Chandrika G Teli, Usha kothandaraman; Complex and unusual variation of renal vessels-embryologic basis and clinical significance ;IJAV;2012 :5: 87-89.
6. Virendra Budhiraja, Rakhi Rastogi, Vaibhav Anjankar, C.S. Ramesh Babu, Prabhat Goel. Research article “ Supernumerary Renal arteries & their embryological & Clinical correlation, A Cadaveric study from North India”; Hindawi Publishing Corporation ISRN Anatomy; volume - 2013: (Article ID-405712)
7. Awojobi OA, Ogunbiyi OA, Nkposong EO. Unusual relationship of multiple renal arteries. Urology 1983; 21(2):205-6.
8. Sofiya Sabouri, Makhtoom Shanhnazi, Alireza Khatami, Behnam Ghiasvand, CT Angiography in evaluation of live kidney donors;PJR:2011Apri-June ;21(2):63-66.

CORRESPONDING AUTHOR

Dr.Kanthi G M

Prof. Dept of P.G. Studies in Shareera rachana,

S. D. M. College of Ayurveda, Udupi., Karnataka, India

E-mail – girishakanthi@gmail.com