

**MULTIPLE DUODENAL DIVERTICULA – A CASE REPORT****Nithin Kumar<sup>1</sup>, U Govindraju<sup>2</sup>, Dayana H<sup>3</sup>, Sheeja C.R<sup>4</sup>**<sup>1</sup>Assistant Professor, Dept of Shareera Rachana, SDM College of AyurveUdupi, Karnataka, India.<sup>2</sup>Professor, Dept of Shareera Rachana, SDM College of Ayurveda, Udupi, Karnataka, India<sup>3,4</sup>Final year PG scholars, Dept of Shareera Rachana, SDM College of Ayurveda, Udupi Karnataka, India**ABSTRACT**

A duodenal diverticulum is an abnormal pouch that develops on the duodenum. The development of this pouch usually does not cause any symptoms, although serious complications may develop. During routine dissection in the Department of Shareera Rachana we came across an incidental finding of duodenal diverticula at the second part of the duodenum. Clinical importance and significance of duodenal diverticulum is discussed herein.

**Key words:** Diverticulum; Major duodenal papilla; Ampulla of Vater

**INTRODUCTION**

Duodenum is the shortest, widest and most fixed proximal part of small intestine. It has no mesentery. Its course presents a remarkably constant curve which encloses the head of pancreas. It lies entirely above the level of umbilicus.

For descriptive purpose it is divided in to first, second, third and fourth parts. First and second parts are respectively superior and descending while third and fourth parts are horizontal and ascending.

The bile duct and pancreatic duct come in contact with medial side of second part of the duodenum. The two ducts enter the wall of the gut obliquely and there unites to form a short dilated tube named pancreatic ampulla. The ampulla opens in to major duodenal papilla which is situated within the descending part of duodenum at the junction of medial and posterior walls about 8-10 cm distal to the pylorus. The accessory pancreatic duct when present opens about 2 cm proximal to major duodenal papilla on small minor duodenal pa-

pilla. The wall of duodenum is made up of serous, muscular, sub mucous and mucous layers [1].

A diverticulum is a pouch or sac opening from a tubular or saccular organ, such as the gut or bladder. Duodenal diverticulum is often found projecting from the duodenum near the duodenal papilla [2].

Duodenal diverticulum was first reported by a French pathologist Chomel in 1710 and was diagnosed radiologically by Case in 1913 [3].

**Case report**

During the routine dissection in the Department of Shareera Rachana, SDM College of Ayurveda Udupi, we identified two extra luminal duodenal diverticula in a 50 year old male cadaver. Both the diverticula were communicating with the lumen of the duodenum through a single opening which was at 1.5 cm above the opening of major duodenal papilla.

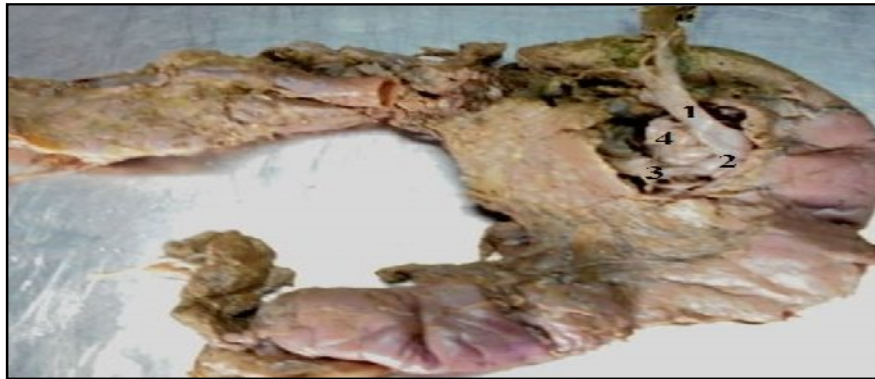1. One was at the postero medial surface. The sac measured 9 cm in circumfer-

ence and 2.2 cm in depth. The lower limit of the duodenal diverticulum was at 17 cm proximal to duodeno jejunal flexure and upper limit was at 3.5 cm distal to the pylorus.

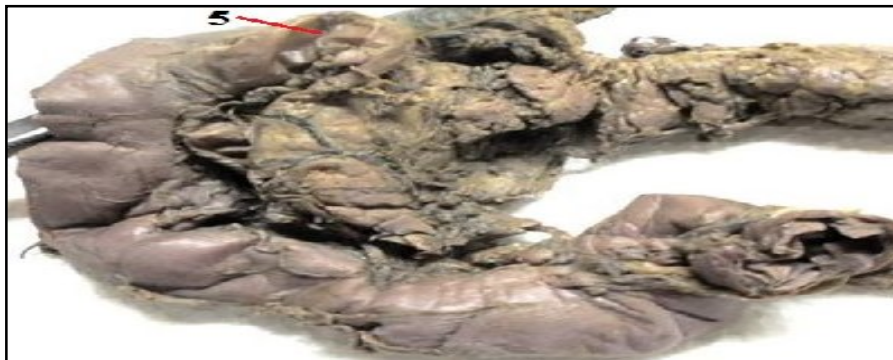2. Second one was at the antero medial surface of second part of the duodenum. The sac measured 10 cm in circumference and 3 cm in depth. It was at 18 cm proximal to duodeno jejunal flexure and 1.8 cm distal to the pylorus.

The main pancreatic duct was joined with accessory pancreatic duct to form the common pancreatic duct. Later it joined with bile duct to form ampulla of Vater outside the duodenal lumen, within the substance of Pancreas. This ampulla opened in the summit of major duodenal papilla within the lumen, 7.5 cm distal to pylorus. The minor duodenal papilla was absent.

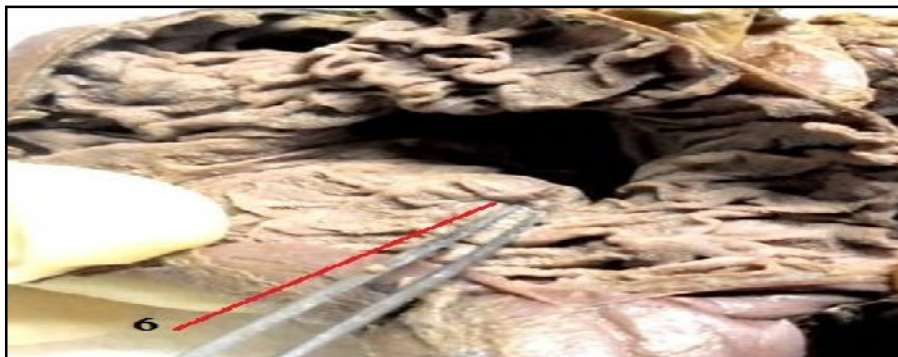**Figure 1:** [1] Common Bile duct, [2] Ampulla of Vater, [3] Common Pancreatic Duct, [4] Posterior Diverticulum



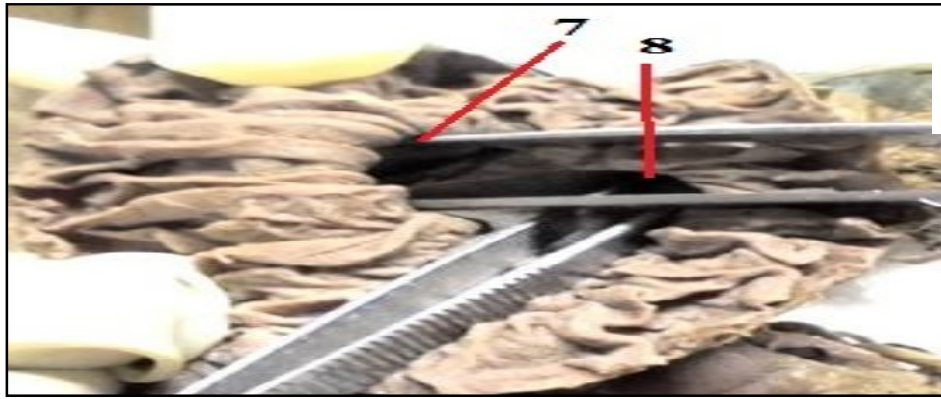
**Figure 2:** [5] Anterior Diverticulum



**Figure 3:** [6] Major Duodenal Papilla



**Figure 4:** [7], [8] Openings of Duodenal Diverticula



## DISCUSSION

Duodenum is the second most common site of diverticula in the alimentary tract after colon. Duodenal diverticula in the vast majority remain asymptomatic throughout the life. In 10% of patients, some symptoms are attributable, with only a minority requiring surgical intervention [3].

Duodenal diverticula can be classified into intraluminal duodenal diverticulum (IDD) and extra luminal duodenal diverticulum (EDD). IDD are congenital, resulting from defective recanalisation of duodenal lumen during foetal development with coexistent congenital anomalies. EDD are acquired or false diverticula, resulting from mucosal herniation at the point where blood vessels penetrate the intestinal wall, which also explains their typical location at the medial or pancreatic border, in 88% of cases. Only 4% of them occur on the lateral wall of the duodenum [3].

EDD are more common and can be further classified into Periapillary diverticula (PAD) and juxta papillary diverticula (JPDD). PAD are extra luminal mucosal out pouching of duodenum arising adjacent to, or containing the ampulla of Vater or intraluminal portion of common bile duct (CBD). JPDD are defined as EDD located within radius of 2 cm of major papilla but not containing it. Some has referred to above definition as ampullary and periampullary, however consistent and precise terminology needs to estab-

lish<sup>4</sup>. About 70% to 75% of all diverticula are periampullary [4].

The exact aetiology of duodenal diverticula is not clear, however; it might be the end result of disordered duodenal motility, advancing age, progressive weakening of intestinal smooth muscles and increase in intra duodenal pressure may encourage the out pouching of the duodenum. It is difficult to ascertain the true prevalence of duodenal diverticula. They are seen in 1% - 6% of upper gastro intestinal contrast studies, 12% - 27% of endoscopic studies and 15% - 22% of autopsies. Diverticula are rare below the age of forty and prevalence rate increases with age [4].

Diverticula of duodenum are classified as primary and secondary. Majority of secondary or false diverticula are the result of chronic duodenal ulceration, so called 'prestenotic diverticulum', whereas the primary is true diverticula. Diverticulum may be single or multiple and as many as 6 or more has been reported. Incidence of multiplicity in x-ray series is 1.4 to 23.5% and in autopsy series it is 3.5 to 30% [5].

Histologically in majority, the circular and longitudinal muscle coats of duodenum are missing and the mucosa and muscularis mucosae make up the wall of the diverticulum [5].

Elective surgical treatment of asymptomatic diverticulum is not justified, as these are innocent; however a small percentage can cause problem ranging from mild and

slightly annoying symptoms to dangerous and even fatal complications. Diverticulectomy done for vague pain and abdominal discomfort is dangerous, unrewarding and only about 50% of patients treated by diverticulectomy electively were entirely relieved of their symptoms. Surgical excision is not without complications and mortality rate of 30% in post-operative period has been reported. A delay in diagnosis can lead to perforation in DD which carries a mortality rate of 90% [5].

The complications arise from pressure effects or from inflammation. Mechanical compression by diverticula can lead to Jaundice, cholangitis, acute and chronic pancreatitis and duodenal obstruction, whereas inflammation can lead to ulceration, perforation, abscess formation and haemorrhage [6].

Knowledge about duodenal diverticulum is important for surgeons to avoid complications during various abdominal surgeries. It is also important for radiologists while doing ultrasound examination and evaluating radiographs.

#### REFERENCES

1. Henry Gray. Susan Standing, editor. Gray's Anatomical Basis of Clinical Practice, 39<sup>th</sup>ed. Elsevier Churchill Livingstone Ltd; Pp-1557, p-1342-1344.
2. Steadman's Medical Dictionary, 28<sup>th</sup>ed. Lippincott Williams & Wilkins; Pp-2168, p-575.
3. Sulochana Sakthivel, Kavitha kannaiyan, Sivakami Thiagarajan; prevalence of duodenal diverticulum in south Indian: A Cadaveric study, ISRN 2013; 767403:5
4. Mian Muhammed Rizwan, Harpeet Singh, VP Chandar, Maria Zulfqar and Veera Singh, Duodenal diverticulum and associated pancreatitis case report with brief review of literature, WJGE Mar 16, 2011; 3(3):62-63
5. Sanjay K. Mahajan, Rajesh Kashyap, Upender K. Chandel, Jatinder Mokta, Satinder S. Minhas. Duodenal diverticulum: Review of literature, Indian Journal of Surgery 2004; 140-145
6. L S Wong, S Hobbs, N J Dorricott; Duodenal diverticulum as a cause of massive gastro intestinal bleeding, J R Soc Med 1999; 92:254-255

---

#### CORRESPONDING AUTHOR

**Dr. Nithin Kumar**

Assistant Professor, Dept of Shareera Rachana, SDM College of Ayurveda, Udupi, Karnataka, India

**Email:** nithinkumarjain@gmail.com

---