



TERMINOLOGY OF SKIN LESIONS



DR. M. RATHOD

PHD SCHOLAR, NATIONAL INSTITUTE OF AYURVEDA, JIAPUR

TERMINOLOGY OF SKIN LESIONS

Primary skin lesions Macules and patches

These are flat, discrete areas of altered color ([Figure. 1.2](#)). In some instances, such as lentigo (increase in number of basal melanocytes), there may be fine surface scaling as a secondary phenomenon (presumably due to disturbance of the basal keratinocytes by the increased melanocyte density). Authors vary in the size cut-off between a macule (smaller) and a patch, with definitions ranging between 1- and 2-cm size limits. As such definitions are arbitrary and of no particular biological significance, it is more helpful to record the actual size.

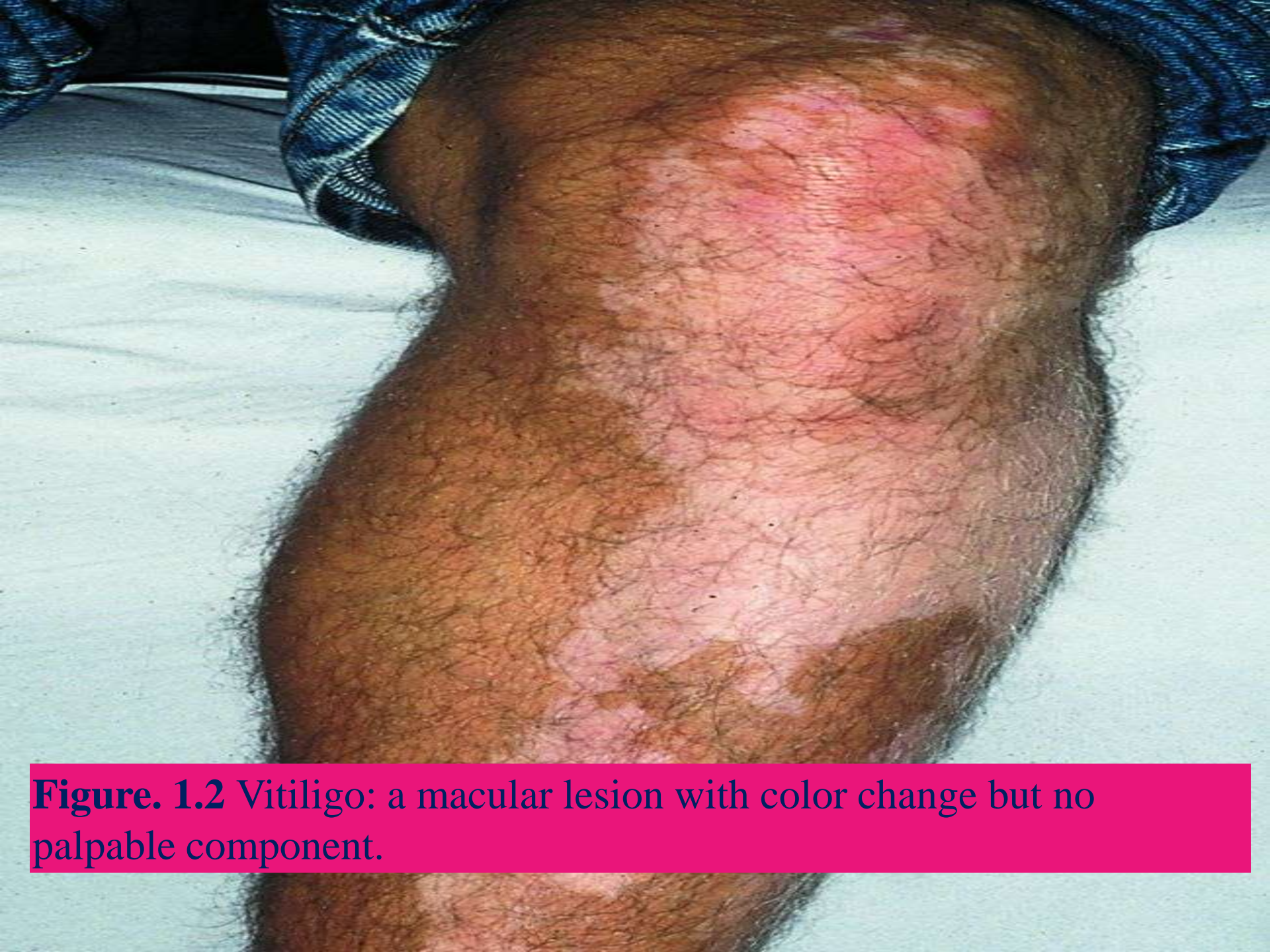

Figure. 1.2 Vitiligo: a macular lesion with color change but no palpable component.



- *Plaques*


- *These are elevated lesions, predominantly flat-topped but palpable (Figure. 1.3). There is more potential for variable surface features (e.g. smooth, scaly, and crusted) than in a macule;*
- 

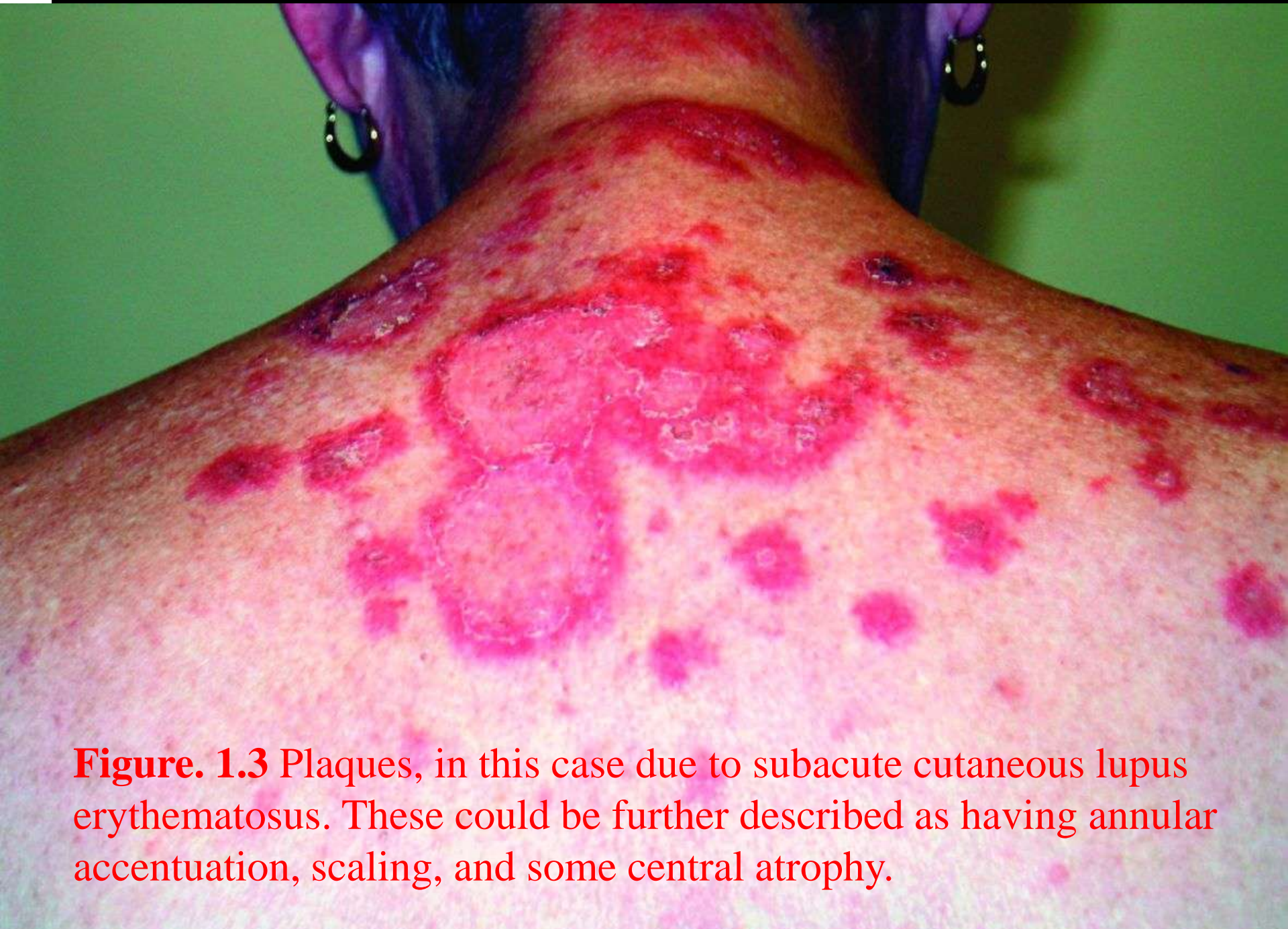

Figure. 1.3 Plaques, in this case due to subacute cutaneous lupus erythematosus. These could be further described as having annular accentuation, scaling, and some central atrophy.

- *Papules and nodules*

- *These are raised and essentially dome-shaped lesions (Figs 1.4 and 1.5). As with macules and patches, there are variable size cut-offs between papules (which are smaller) and nodules (which are larger). The arbitrary cut-off (either 0.5cm or 1cm in different publications) ignores the possibility of lesions of mixed sizes or of growth from a papule to a nodule. The term maculopapular is applied to eruptions that have mixed features of macules and papules or plaques; although this pattern is frequent in drug eruptions and viral exanthems, it is a rather overused term that often does not accurately describe the predominant component of the eruption.*

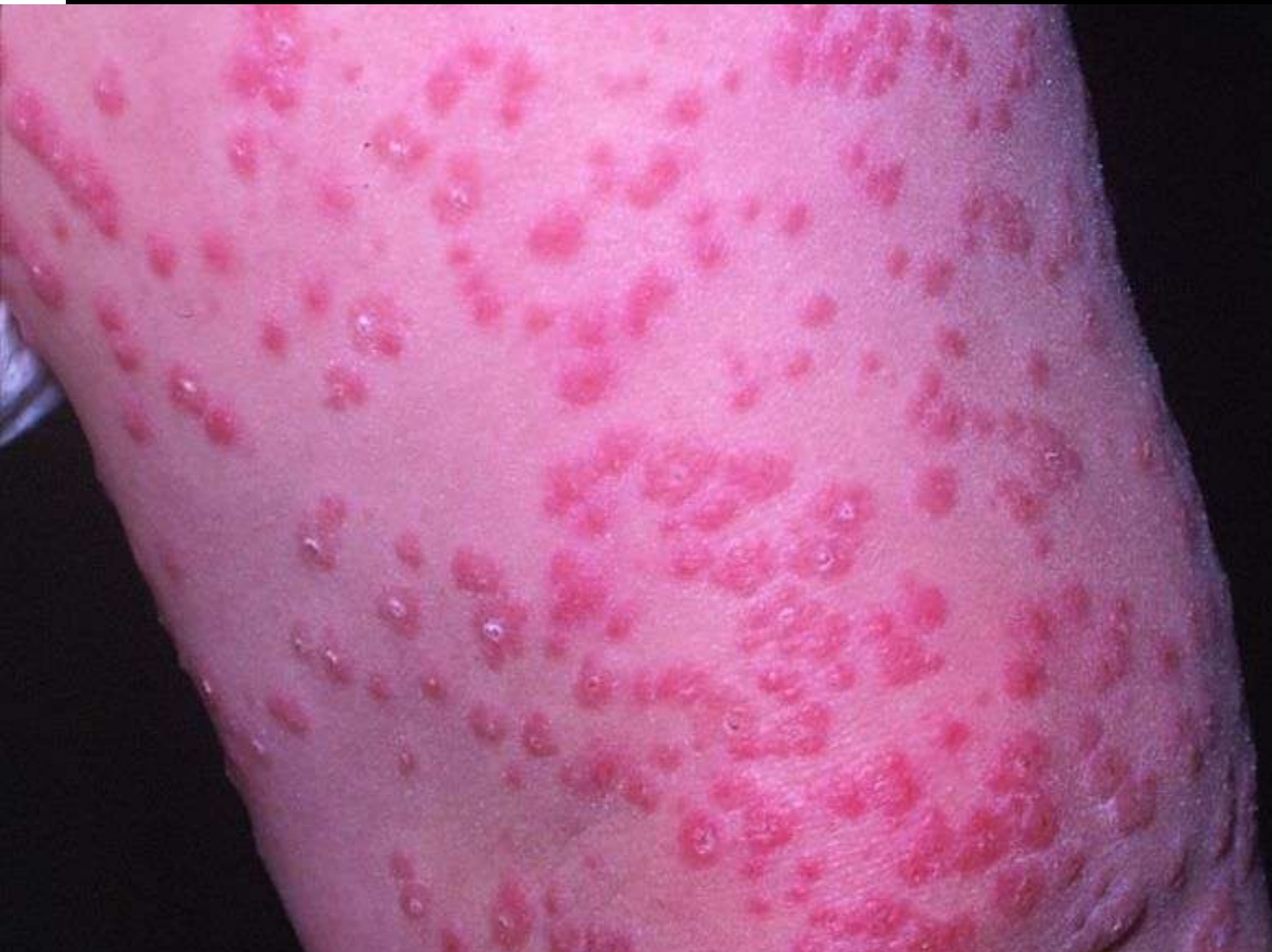

Figure. 1.4 Papules, in this case due to a condition called Gianotti–Crosti syndrome. There are multiple small dome-shaped lesions with some central umbilication.

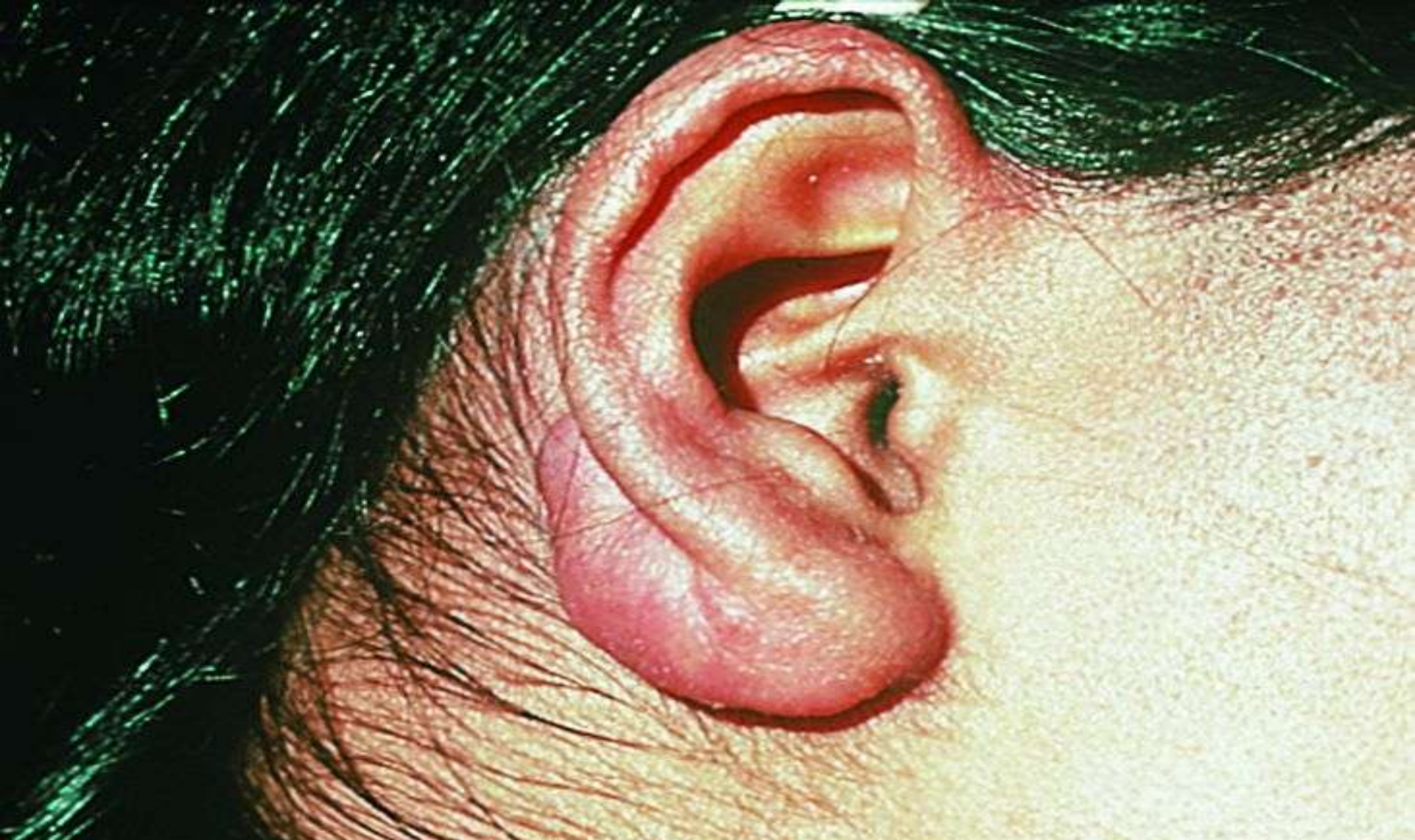

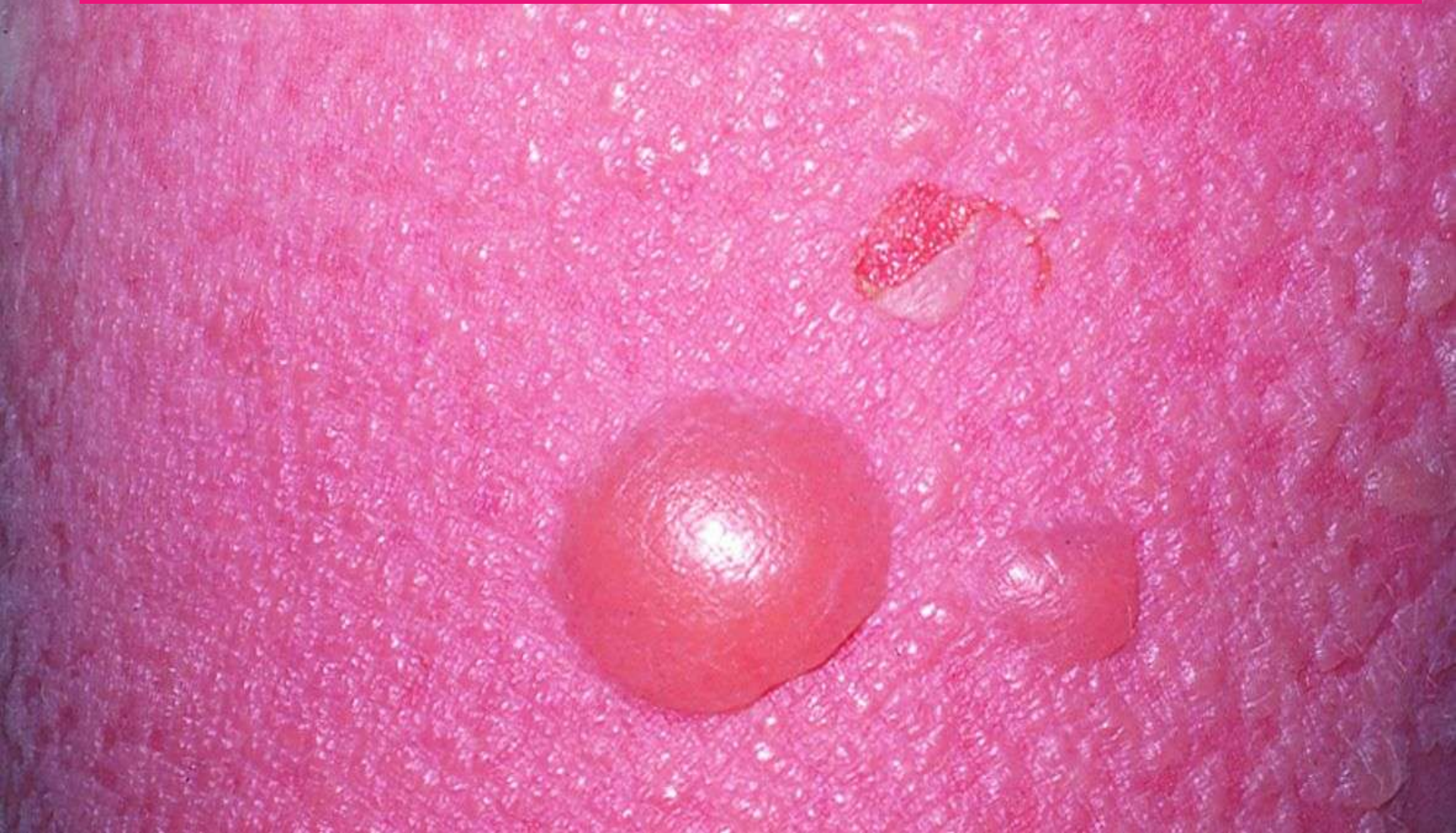Figure. 1.5 An example of a nodule, in this case a keloid on the earlobe secondary to ear piercing.

- *Blisters (vesicles and bullae)*

- *Blisters can be divided into smaller (0.5- or 1-cm cut-off) vesicles and larger bullae ([Figs 1.6](#) and [1.7](#)). Again, this is somewhat arbitrary; in practice most vesicular eruptions (e.g. those of pompholyx eczema, [Fig. 1.7](#)) actually consist of lesions of 1–4mm, whereas most conditions that would usually be described as bullous have at least some lesions of over 1cm. Blisters should be documented as unilocular (e.g. in friction blister and bullous pemphigoid) or multilocular (e.g. in pompholyx eczema).*

-

Figure. 1.6 Blister: this is a unilocular blister with clear fluid content in a patient with toxic epidermal necrolysis . Intact blisters are relatively uncommon in this condition.



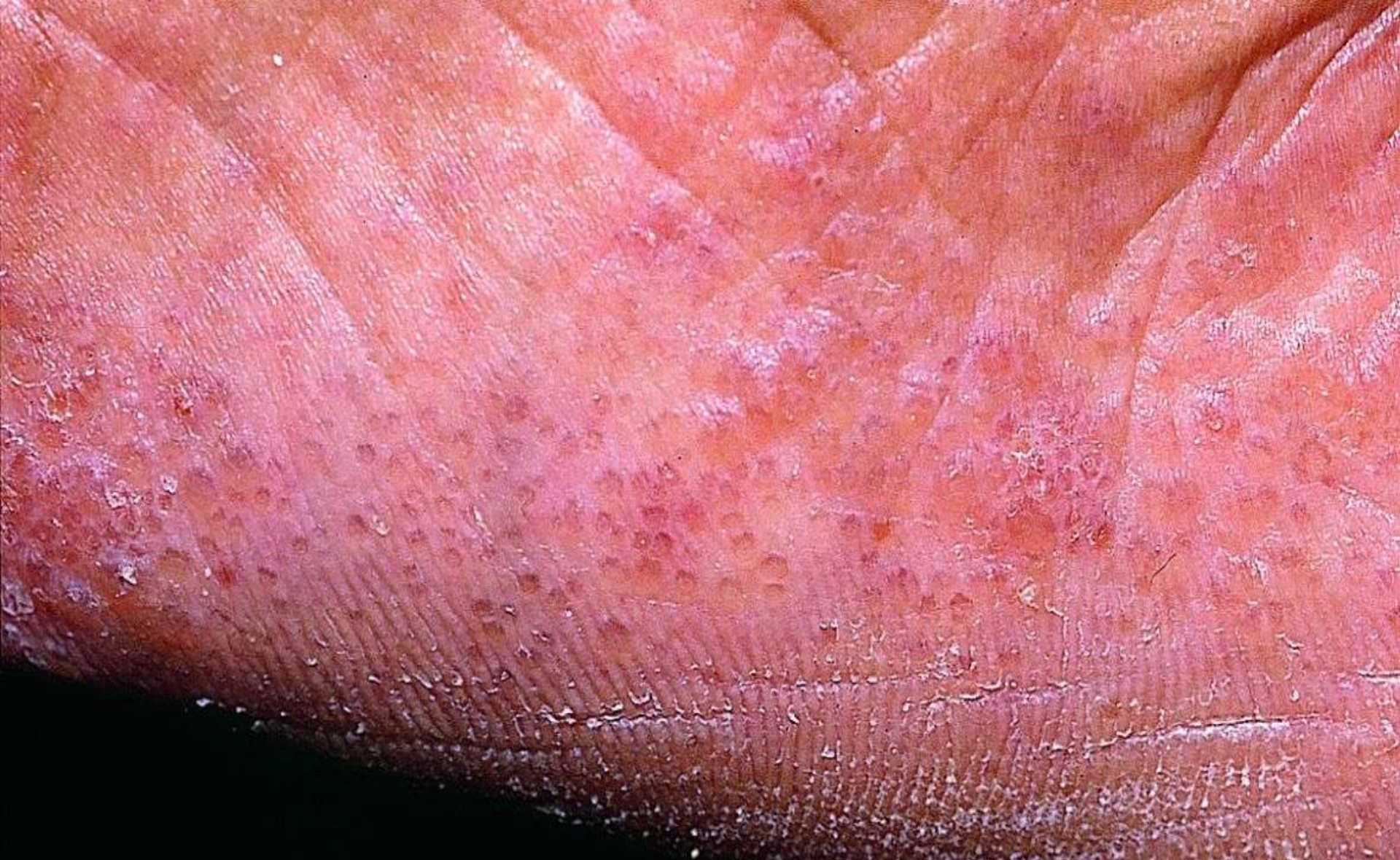

Figure. 1.7 Multiple small vesicles in this case from pompholyx.



- *Pustules*


- *These are similar to blisters but contain pus, which is usually yellow but may be greenish in older pustules (Figure. 1.8). Older pustules usually dry to form brownish scabs.*
- 

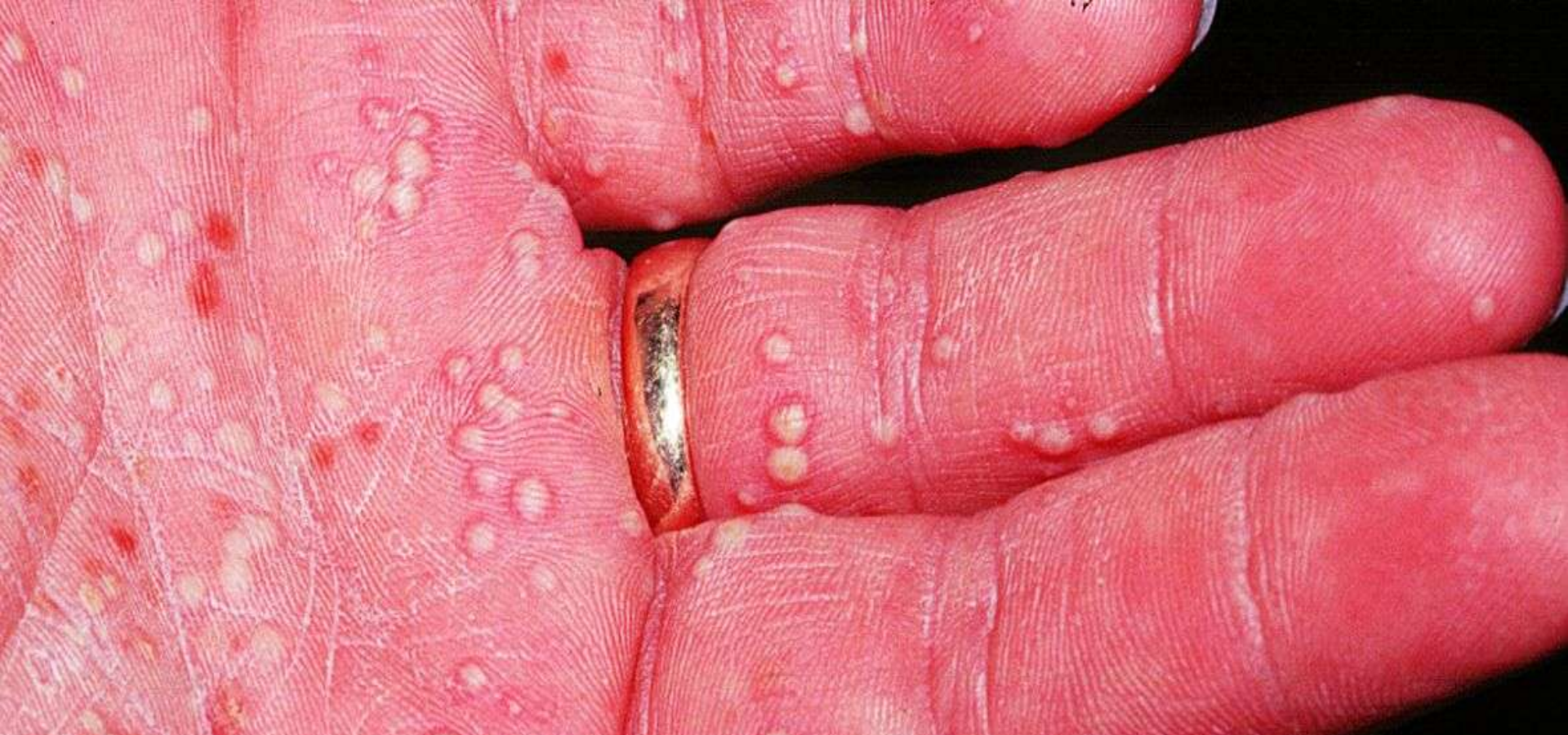

Figure. 1.8 Pustules: multiple yellow pustules on the palm of the hand, in this case due to acute palmoplantar pustulosis. This should be compared with the more common chronic palmoplantar pustulosis (discussed in the context of psoriasis), in which the pustules are more variable in size and in stages of evolution.

■ *Telangiectasia and other vascular lesions*

- *Vascular changes such as telangiectasia (discrete visible vessels) should be distinguished from erythema (increased redness due to increased blood flow rather than due to a fixed structural vascular abnormality) and purpura (small spots of extravasated blood), whether as components of a rash or a discrete localized lesion. Blood that is within vessels can generally be compressed out of the skin by pressure, hence causing blanching, whereas this cannot be achieved with extravasated blood. There are occasional instances where intravascular blood cannot be compressed out using simple clinical techniques .*

Ulcers and other breaks in the skin

Breaks in the skin may be divided into the following.

- *Ulcers*—the term can be applied to any skin break but is generally taken to imply a defect extending into the dermis (Figure. 1.9);
- *Erosions*—these are superficial, involving the epidermis only.
- *Fissures*—a specific morphology of skin break resembling a small slit.
- *Excoriations* are a type of erosion or ulcer caused by scratching, the term describing the process by which the break has occurred rather than being used as a term for a specific primary lesion.

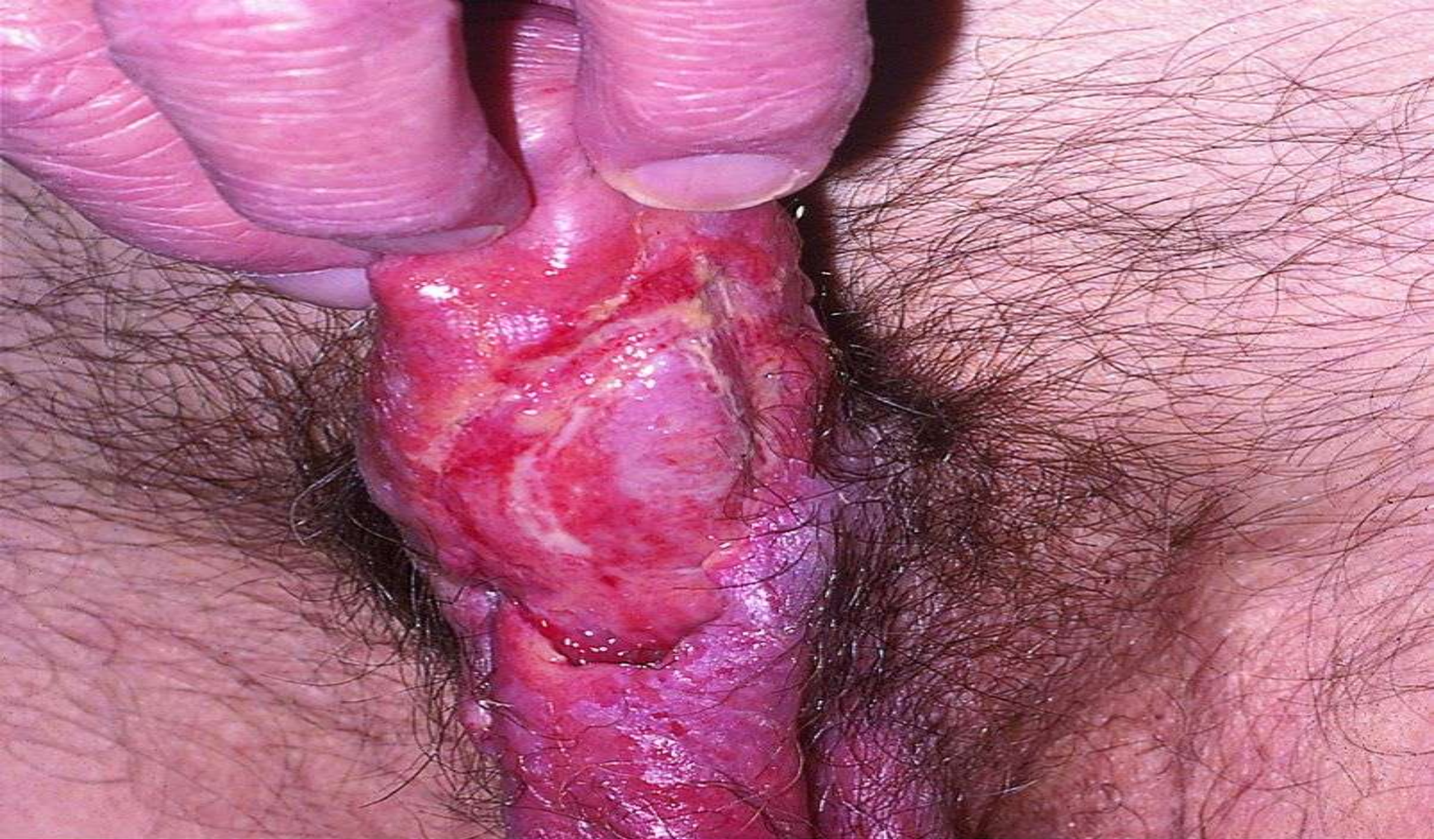

Figure. 1.9 Ulcers: defects through the epidermis reveal underlying dermis or fat. This ulceration of penis was probably due to Behçet disease, although the patient did not fulfill criteria for the diagnosis, as he had no oral ulcers .

Weals

These are due to dermal edema. Patients often confuse weals and blisters, so a history of 'blisters' may be misleading. Gentle pressure on a blister will alter its shape, which generally returns to the previous shape very quickly unless the fluid content is highly proteinaceous, and firm pressure may cause the blister to spread or to break. By contrast, gentle pressure on a weal has no effect (except blanching if it is erythematous), while firm pressure may compress fluid out of it to leave an indentation that slowly refills. However, the simplest distinction is that blisters can be punctured and then leak fluid.

Surface morphology and secondary changes

It is useful to note certain surface features of papules, nodules, and plaques.

Overall shape

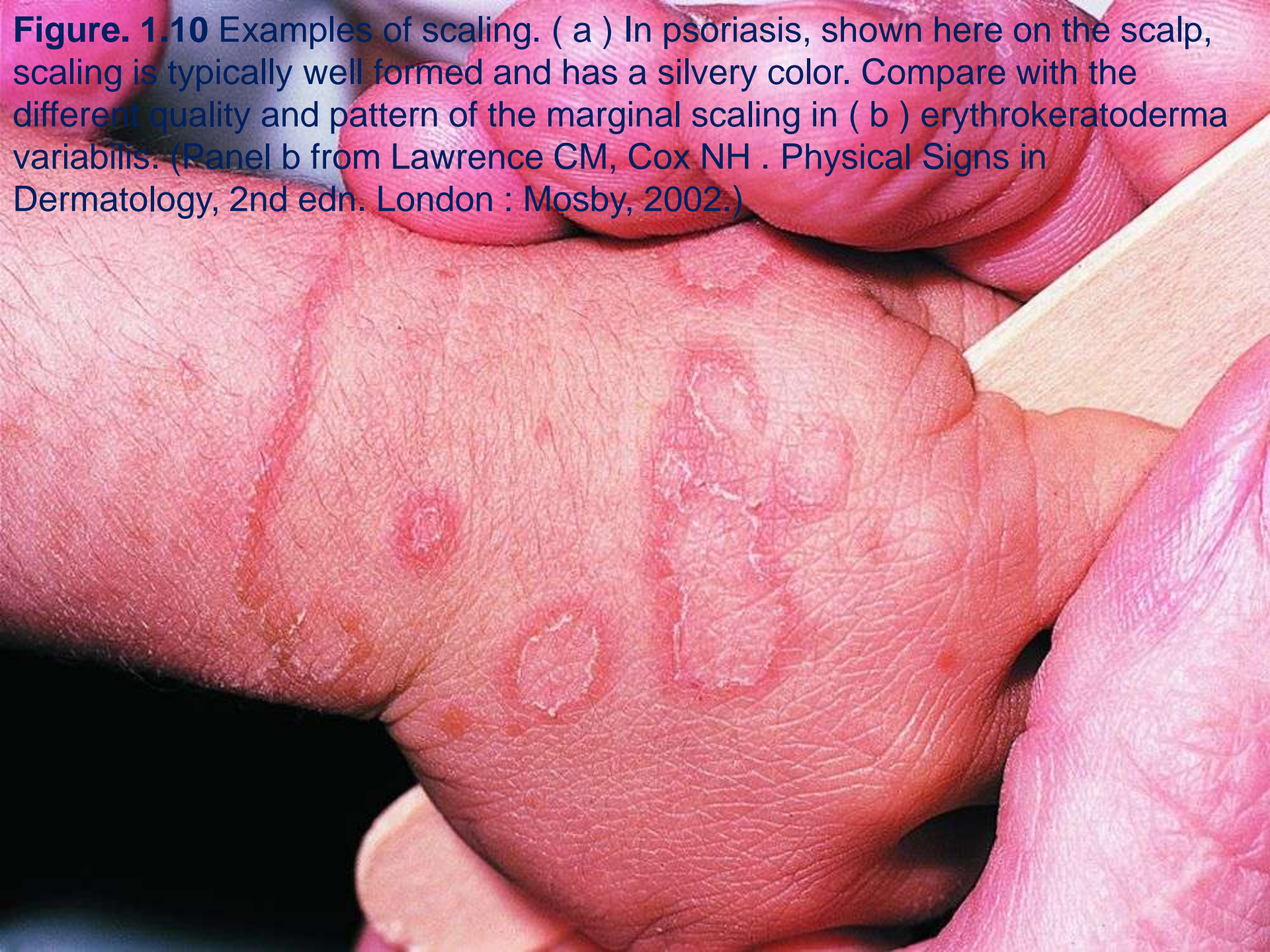
Papules and nodules can be further characterized as dome-shaped, flat-topped, umbilicated, etc.

Surface changes

A particularly important issue is distinction between disorders with and without an epidermal component, implied by scaling and crusting ([Fig.1.10](#)). Thus, for example, annular lesions of ringworm (scaly) and granuloma annulare (no scaling) can readily be distinguished.

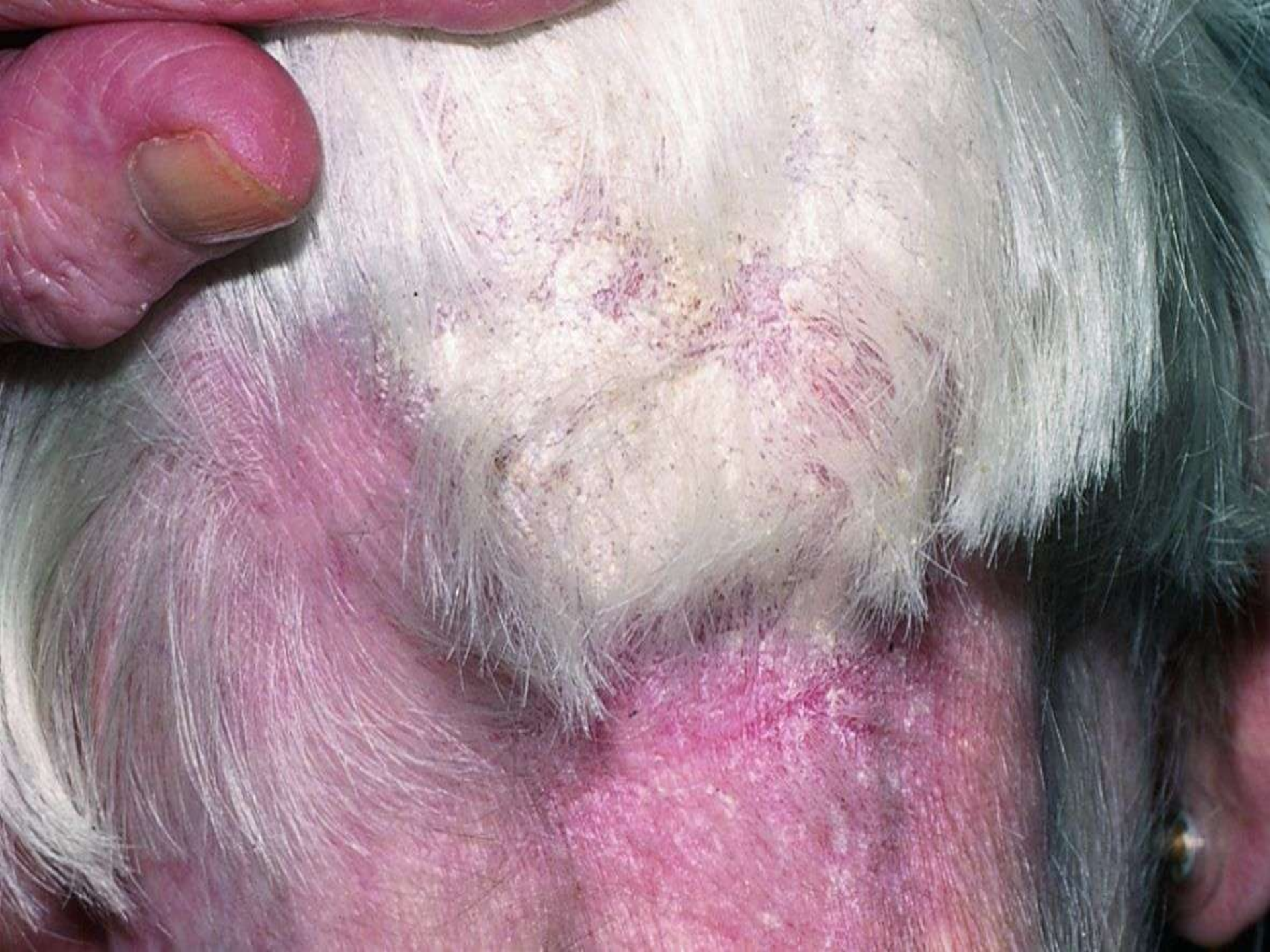

Figure. 1.10 Examples of scaling. (a) In psoriasis, shown here on the scalp, scaling is typically well formed and has a silvery color. Compare with the different quality and pattern of the marginal scaling in (b) erythrokeratoderma variabilis. (Panel b from Lawrence CM, Cox NH . Physical Signs in Dermatology, 2nd edn. London : Mosby, 2002.)



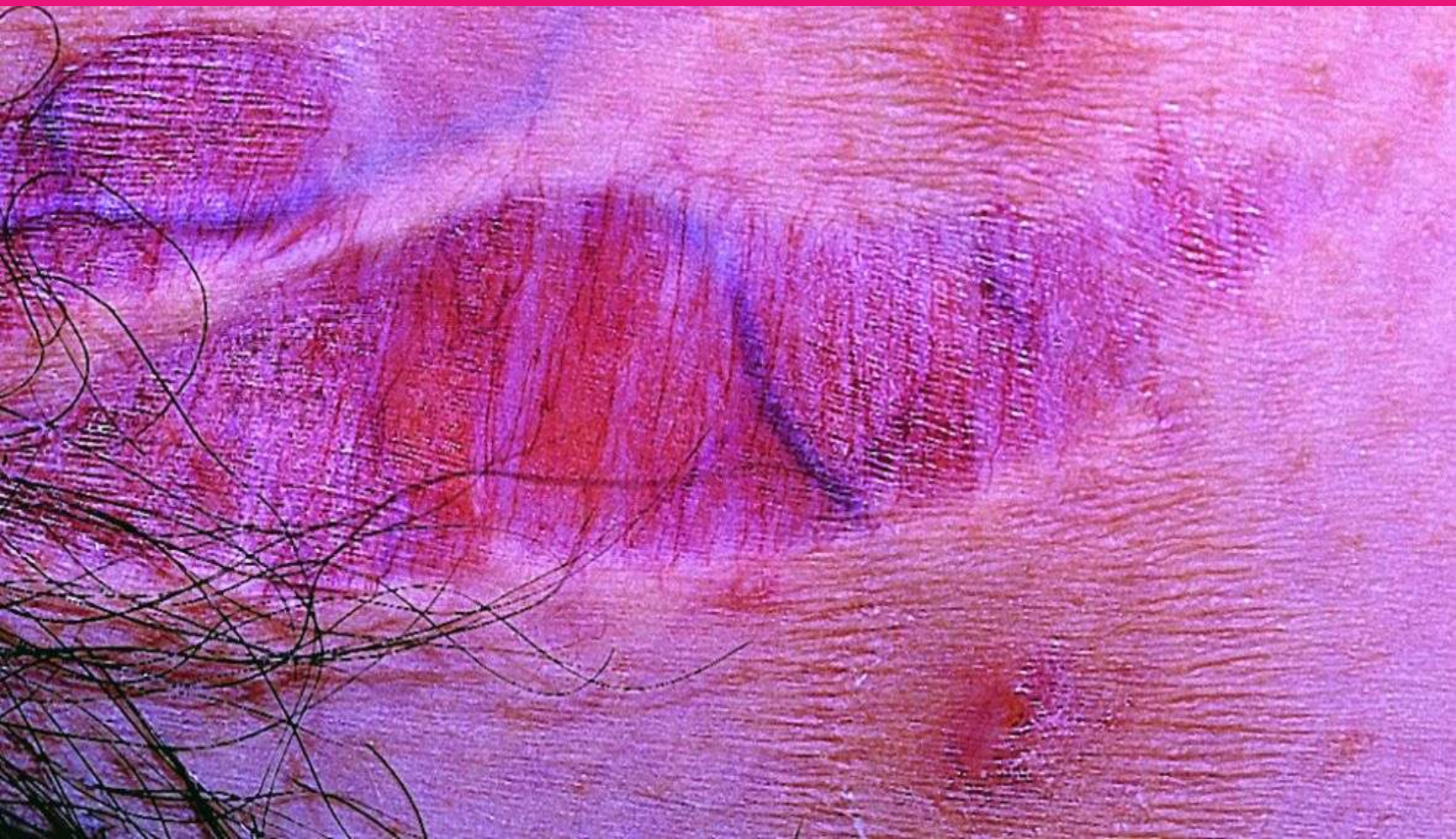- **Useful terms are as follows:**

- *Smooth*—this may be like the normal skin surface or smoother.
- *Scaly*—scaling is due to flakes of keratin, which can be felt, and rubbed or scraped off the skin. It can be qualified as fine (e.g. in pityriasis versicolor) or coarse (e.g. in psoriasis), and as loose or adherent. Disorders with scaly papules and plaques are termed papulosquamous.

- *Texture changes*



- *Alterations in any skin component may cause thinning (atrophy) or thickening. Epidermal atrophy causes a fine wrinkling appearance of the skin (except over the surface of a nodule, where it may produce abnormally smooth and tight-looking skin due to the tension that is being exerted). It is often combined with dermal atrophy ([Figs 1.11](#) and [1.12](#)). Dermal atrophy may lead to a herniation of the underlying fat (a process termed anetoderma). Fat atrophy in the absence of dermal atrophy causes a deep indentation of the skin.*

Figure. 1.11 Atrophy of the skin, in this case in striae distensae. This occurs due to stretching of the skin (e.g. on abdomen or thighs in pregnancy or when the skin is damaged by **EXCESSIVE** use of topical corticosteroids). The skin appears thinned, and dermal vasculature is readily visible in the line of the applied tension that has stretched the skin.



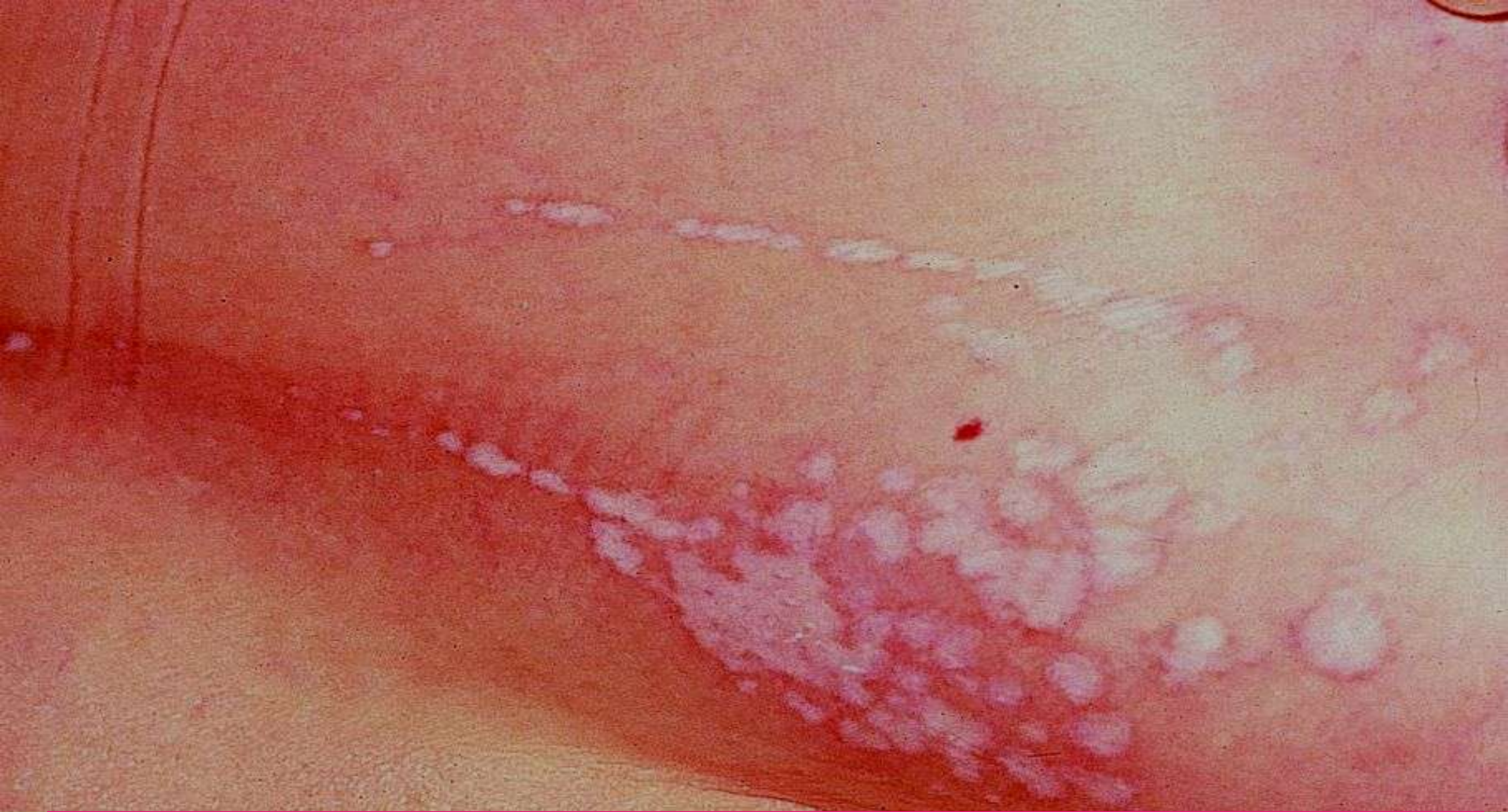

Figure. 1.12 Lichen sclerosus et atrophicus. In this condition, there is epidermal atrophy together with a homogenization and edema of the upper dermal collagen. This produces a typically white color and a thinned appearance of the skin. In this patient, the two lines of lesions represent a Koebner response.

- 
- *Thickening of the skin includes epidermal thickening (e.g. lichenification due to rubbing), dermal thickening (e.g. sclerosis due to increased collagen in scleroderma, and peau d'orange appearance due to dermal mucin), and fat hypertrophy ([Fig.1.13](#)).*
- 

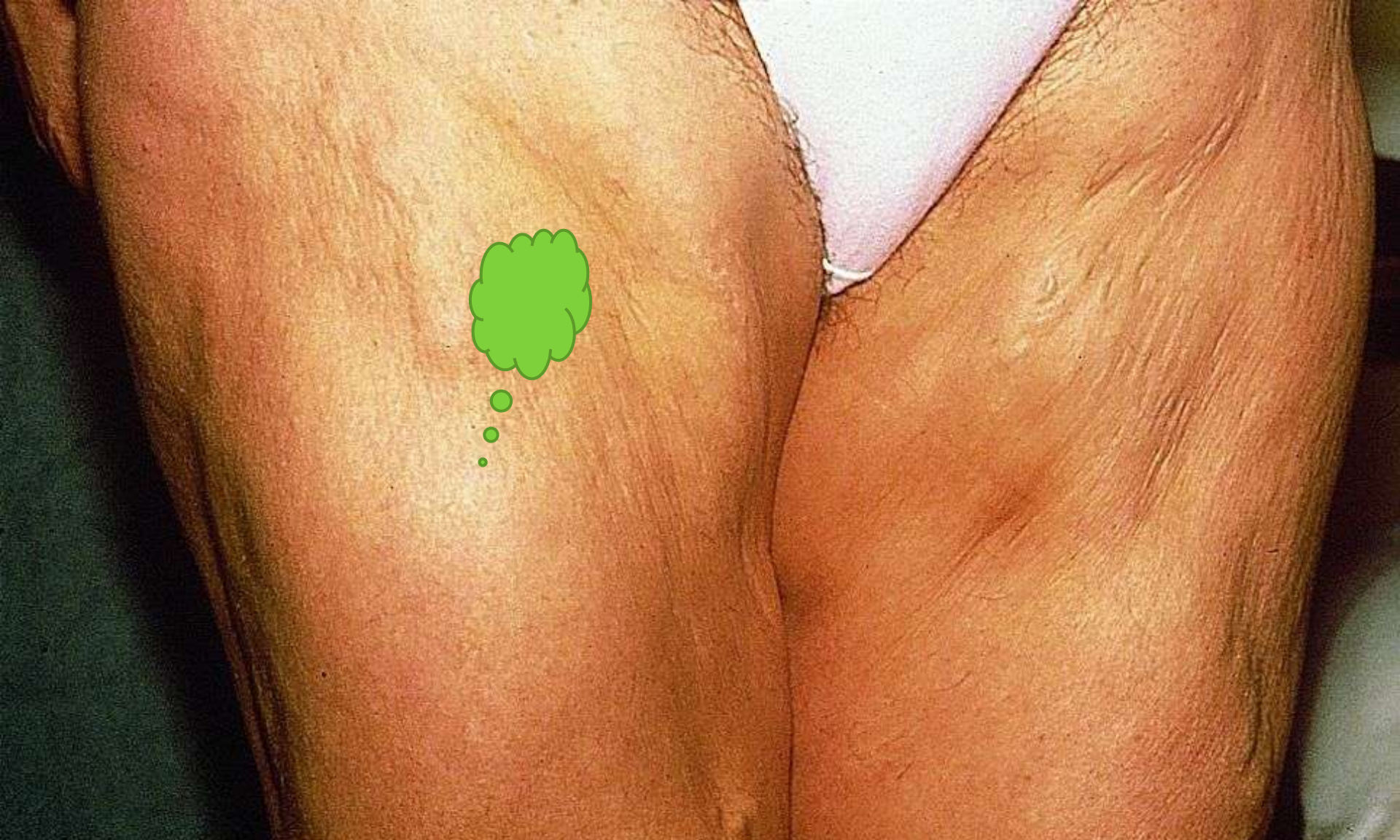



Figure. 1.13 In this case, mixed fat hypertrophy and atrophy (note the normal skin color because the abnormality is deep to the skin).

- 
- *These processes, and the predominant level of the skin that is affected, can usually be identified from the physical signs, both palpable and visible (e.g. increased skin markings in lichenification, more visible vessels due to atrophy).*

- *Shapes and patterns, symmetry*
- *These processes, and the predominant level of the skin that is affected, can usually be identified from the physical signs, both palpable and visible (e.g. increased skin markings in lichenification, and more visible vessels due to atrophy).*

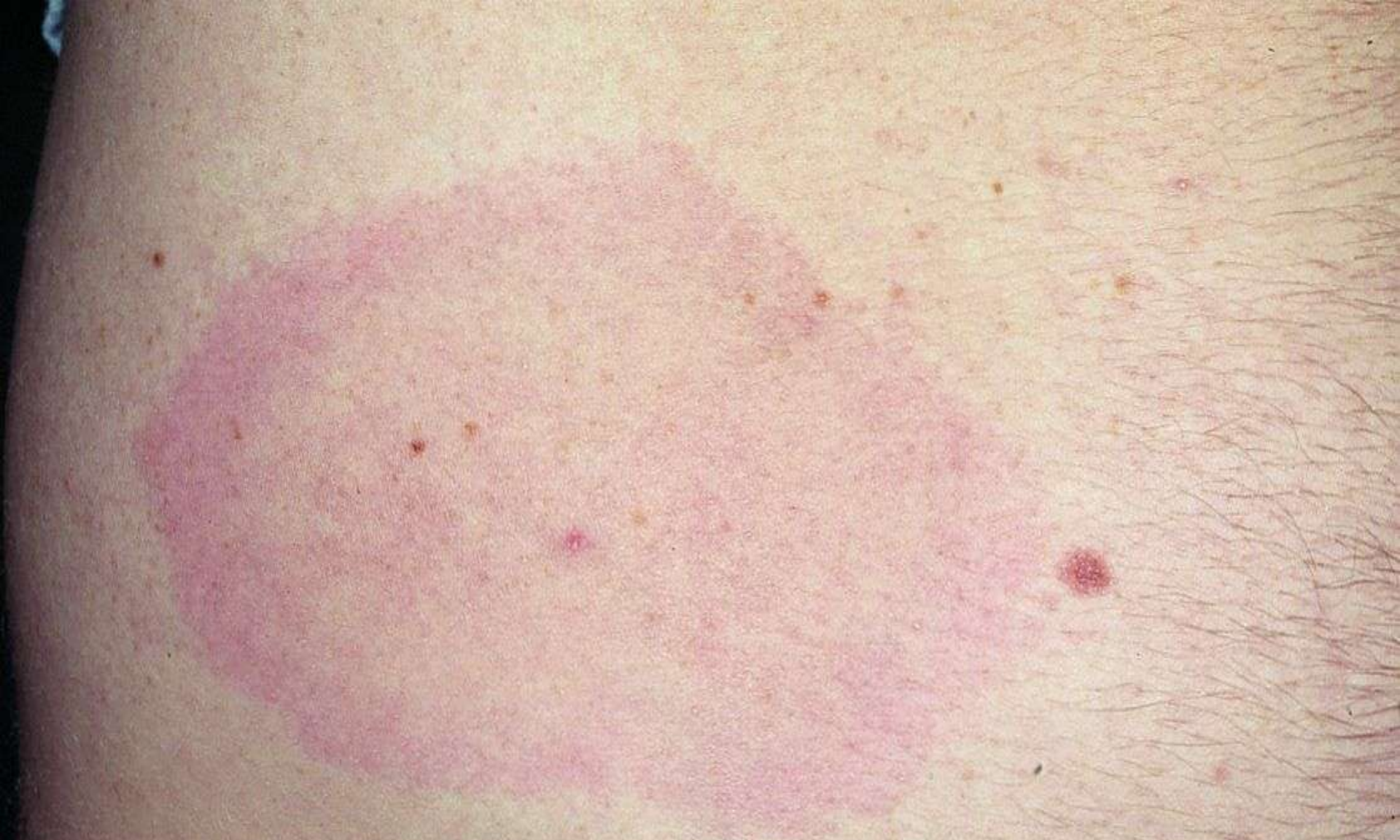

Figure. 1.14 Annular lesion: a complete circle. In this case due to erythema migrans of Lyme disease. Parts of a circle are termed arcuate or arciform.

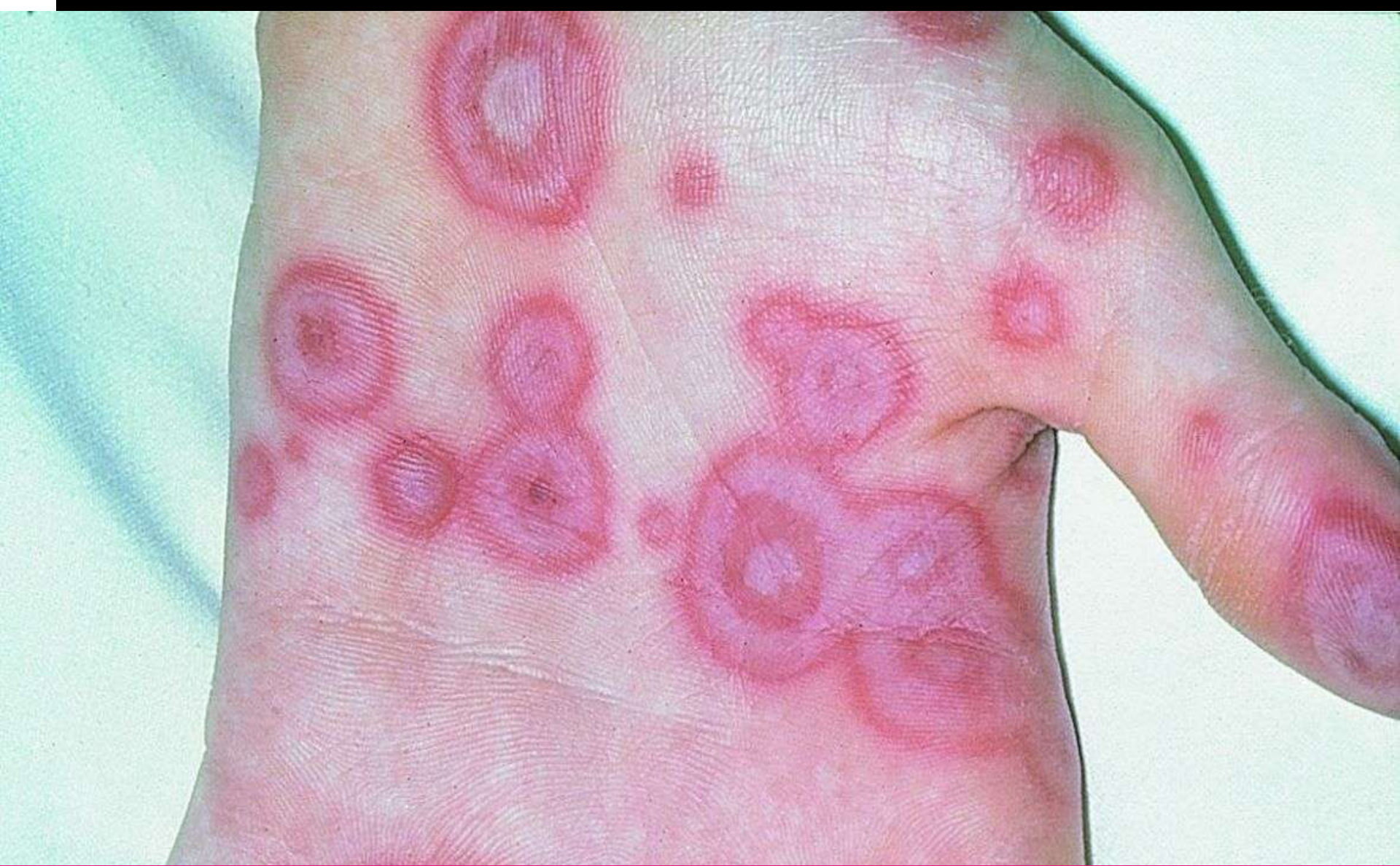


Figure. 1.15 Classic target lesions, comprising multiple concentric circles, typically (as in this case) seen in erythema multiforme triggered by herpes simplex virus infection.

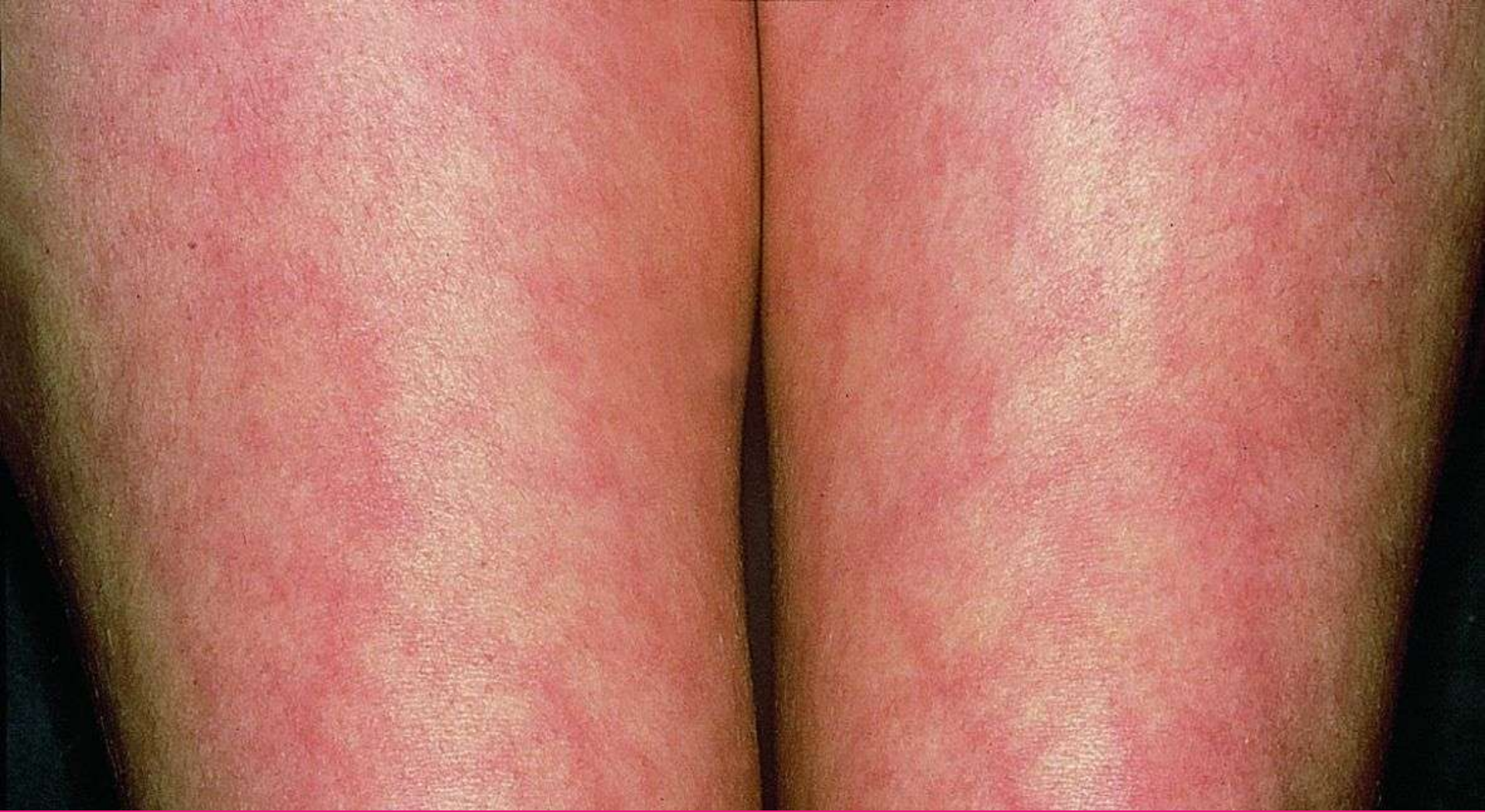

Figure. 1.16 This net-like or chicken wire pattern is termed livedo . A uniformly sized faint livedo pattern is common over fatty areas of skin, especially in babies and young women, and is a physiologic phenomenon reflecting areas of slower flow of deoxygenated blood (known as cutis marmorata).

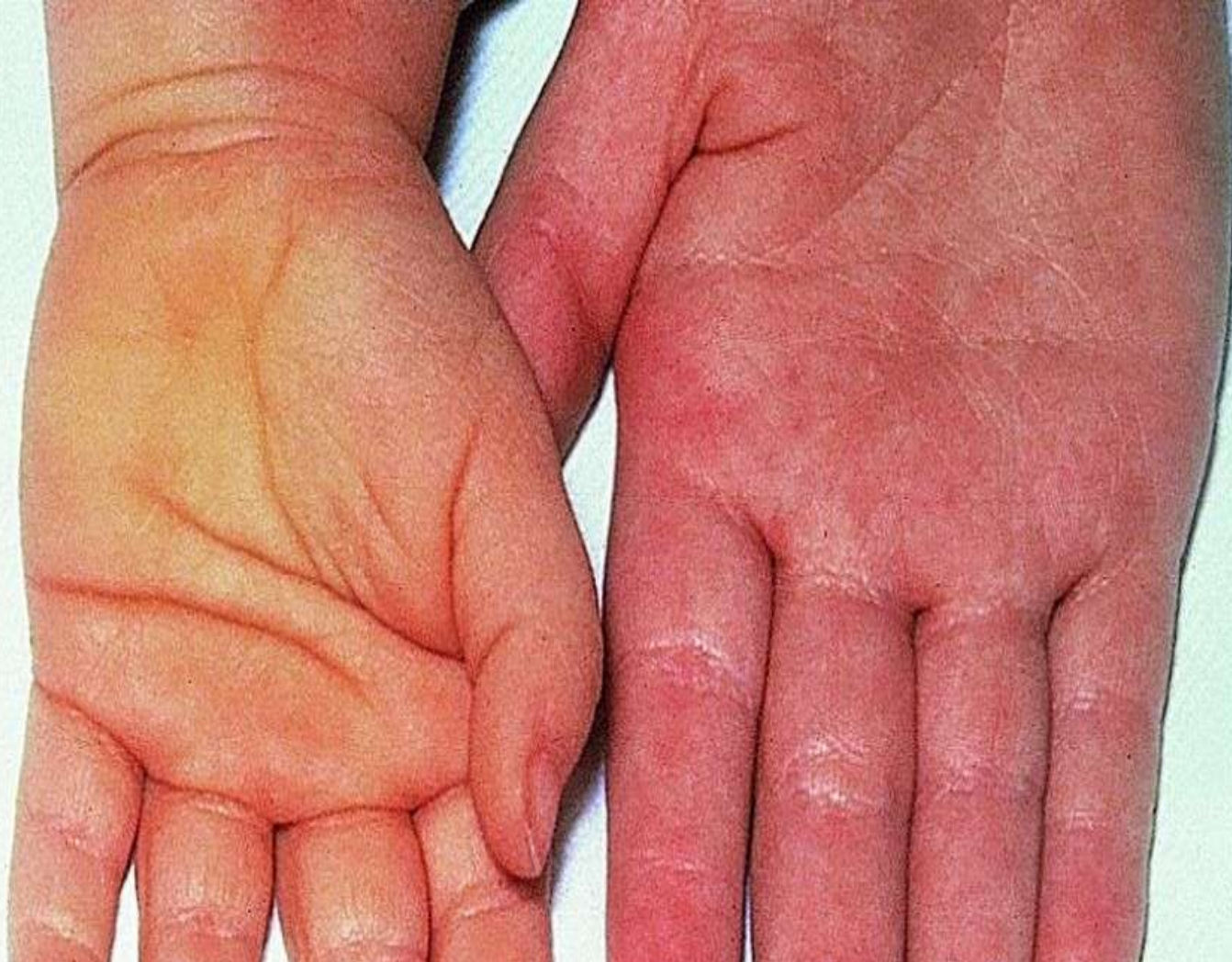

Figure. 1.17 Skin color may be rather subjective, but the hand on the left in this picture is clearly more yellow than the normal control. This patient had carotenemia, which may occur as a metabolic defect or in hypothyroidism, but is commonly dietary due to excessive carotene intake.



- **Shapes of individual lesions**

- *Examples of lesional shapes, and conditions with which they are associated, are listed in Table 1.1 ; some specific common examples are addressed in more detail in Tables 1.2 - 1.4 .*

Shape	Description	Example(s)
Discoïd (nummular)	A filled circle	Discoïd eczema
Petaloid	Discoïd lesions that have merged together	Seborrheic dermatitis on the trunk
Arcuate	Incomplete circles	Urticaria
Annular	Open circles with different central skin compared with	Tinea corporis, granuloma annulare
Polycyclic	Circles that have merged together	Psoriasis
Livedo	Chicken wire criss-cross pattern	vasculitis
Reticulate	A finer lace-like pattern	Oral lichen planus
Target	Multiple concentric rings	Erythema multiforme
Stellate	Star-shaped	Lesions of meningococcal septicemia
Digitate	Finger-shaped	Parapsoriasis
Linear	Straight line	Koebner reaction to a scratch in lichen planus (see Tables 1.3 and 1.4)
Serpiginou	Snake-like	Cutaneous larva migrans

EXAMPLES OF LESIONS OR GROUPINGS OF LESIONS THAT PRODUCE ANNULAR MORPHOLOGY

Scale	Typically annular	Often Include annular components
Present	Ringworm Erythema annulare centrifugum	Psoriasis Seborrheic eczema Pityriasis rosea (herald patch) Impetigo Subacute cutaneous lupus erythematosus Mycosis fungoides
Absent	Granuloma annulare Jessner lymphocytic infiltrate 'Annular erythemas' Erythema annularis telangiectoides	Urticaria Erythema multiforme Lichen planus Sarcoidosis

EXAMPLES OF LESIONS OR GROUPINGS OF LESIONS THAT PRODUCE LINEAR MORPHOLOGY

Determinant of patterns	Example(s)
Blood vessels	Thrombophlebitis, Mondor disease (linear thrombophlebitis on the trunk)
Lymphatics	Eczema related to varicose veins Temporal arteritis Lymphangitis
Dermatome	Sporotrichosis, fish tank granulomas
Nerve trunks	Herpes zoster, zosteriform nevus, zosteriform
Developmental and Blaschko lines	Darier disease, zosteriform metastases Leprosy (thickened cutaneous nerves) Pigmentary demarcation line, linea nigra Epidermal nevi, incontinentia pigmenti,
Skin stretching Infestation	Lhypomelanosis of Ito, linear psoriasis, linear lichen planus, lichen striatus Striae due to growth spurt (on lower back) Larva migrans (wavy, not straight, lines)

External

injury

Plants

Phytophotodermatitis

Allergens

Elastoplast, nail varnish (neck), necklace, waistbands, etc.

Chemical

Caustics (e.g. phenol)

Thermal

Burns

Physical

To normal skin

Keloid scar, bruising, dermatitis artefacta, amniotic
constriction bands

To abnormal skin Purpura (cryoglobulinemia, amyloid,
vasculitis)

Blisters (epidermolysis bullosa, porphyrias)

Inoculation

Warts, mol luscum contagiosum

Koebner phenomenon

Other determinants

Psoriasis, lichen planus, others Scar sarcoid

Linear scleroderma (limb, central forehead)

Senear-endash Caro ridge (on hands in psoriasis)

Dermatomyositis (linear pattern on dorsum of fingers;
Gottron sign)

Interstitial granulomatous dermatitis (rope sign)

Color

Skin color involves contributions from several pigments. A wide range of skin colors occur in different physiologic and pathologic states. The subtleties of color may not be appreciated without experience.

- *melanins (red, brown, or black; these usually provide the dominant pigment in normal skin)*
- *blood (red, purple, or blue)*
- *carotenoids (yellow; [Fig.1.17](#)) and .*
- *dermal fibrous tissue (white).*

- *A wide range of skin colors occur in different physiologic and pathologic states. The subtleties of color may not be apparent, for example, patches of vitiligo (loss of melanin) and of nevus anemicus (loss of red color due to vasoconstriction) are both often termed 'depigmented' by non-specialists, but the vitiligo is white or pale pink, whereas nevus anemicus is usually a pale yellowish brown color (i.e. hypopigmented rather than depigmented). Some shades of color are quite characteristic (e.g. the yellow-orange color of xanthomas), and others are sufficiently useful that they narrow the list of likely diagnoses (e.g. purplish or violaceous coloring of lichen planus or dermatomyositis). Thus an accurate description of shades of red or other color changes can be diagnostically useful even without experience.*

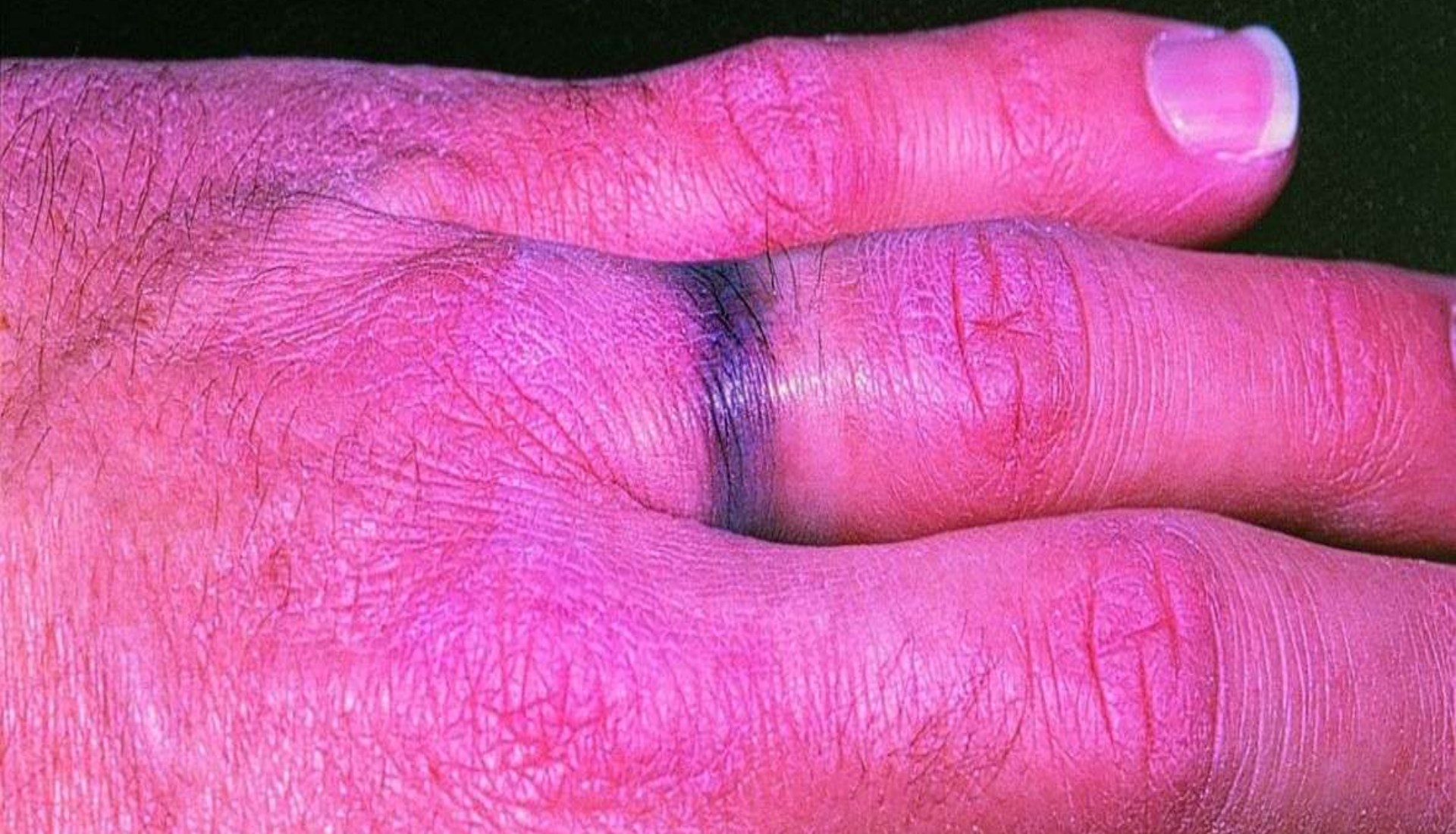

Figure. 1.18 Black dermographism. Gold rings are a common cause, usually after there has been a solvent or abrasive agent under the ring. In this case,