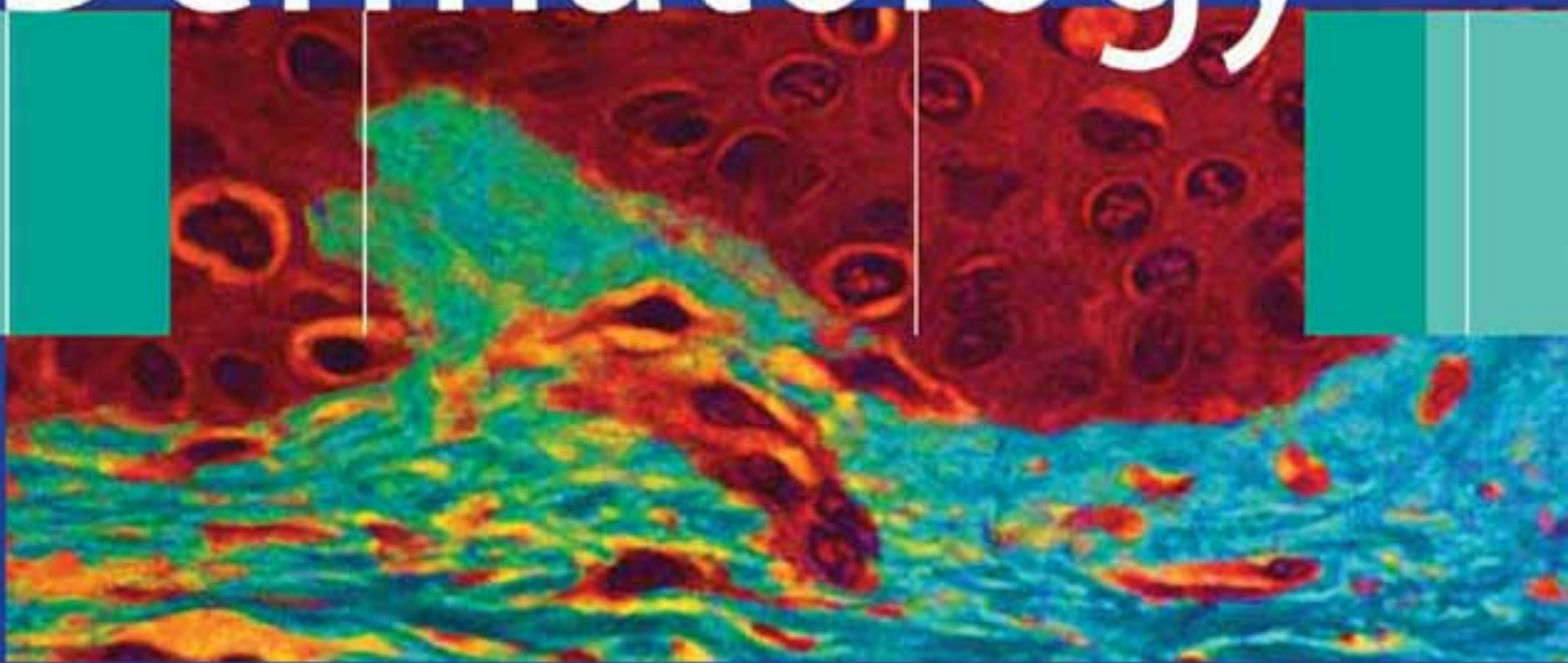


Cheryl M. Burgess *Editor*

# Cosmetic Dermatology



 Springer

Cheryl M. Burgess (Ed.)

**Cosmetic Dermatology**

Cheryl M. Burgess (Ed.)

# Cosmetic Dermatology

With 35 Figures and 33 Tables

 Springer

**Cheryl M. Burgess, M.D., F.A.A.D.**

2311 M Street  
NW Suite 504  
Washington, D.C. 20037  
USA

Library of Congress Control Number: 2004115994

ISBN 3-540-23064-5 Springer Berlin Heidelberg New York

This work is subject to copyright. All rights are reserved, whether the whole or part of the material is concerned, specifically the rights of translation, reprinting, reuse of illustrations, recitation, broadcasting, reproduction on microfilm or in any other way, and storage in data banks. Duplication of this publication or parts thereof is permitted only under the provisions of the German Copyright Law of September 9, 1965, in its current version, and permission for use must always be obtained from Springer. Violations are liable to prosecution under the German Copyright Law.

**Springer is a part of Springer Science+Business Media**

springeronline.com

© Springer-Verlag Berlin Heidelberg 2005

Printed in Germany

The use of general descriptive names, registered names, trademarks, etc. in this publication does not imply, even in the absence of a specific statement, that such names are exempt from the relevant protective laws and regulations and therefore free for general use.

Product liability: the publishers cannot guarantee the accuracy of any information about dosage and application contained in this book. In every individual case the user must check such information by consulting the relevant literature.

Editor: Marion Philipp

Desk Editor: Irmela Bohn

Production: ProEdit GmbH, 69126 Heidelberg, Germany

Cover: Frido Steinen-Broo, EStudio Calamar, Spain

Typesetting: K. Detzner, 67346 Speyer, Germany

Printed on acid-free paper 21/3150 ML 5 4 3 2 1 0

## Preface

Two years ago, this book was merely a concept, fueled by the clinical needs of a new and younger generation seeking cosmetic procedures and a desire to share my own clinical experiences with botulinum toxin and soft tissue augmentation. As the concept evolved, the number of topics did likewise, expanding the book's scope. With multiple topics, additional contributing authors were recruited. In contemplating the level of writing effort required, I had to ask myself: "How will this book differ from existing cosmetic dermatology textbooks?" Patients' changing demographics coupled with technological advancements and new FDA product approvals for dermatology have created an overwhelming need for cutting-edge information. This book attempts to fill the information deficit.

Today's demographics are transforming rapidly. Aging is no longer associated with frailty and impaired ability; growing old no longer means looking old. While the stigma associated with being "old" is decreasing, patient demand for cosmetic enhancements is increasing, particularly in the younger generation who seek interventions at the earliest signs of aging. Additionally, by 2050, the U.S. Census Bureau predicts non-Caucasian populations will comprise greater than 50% of the total population. Ethnic, racial, and gender differences present new challenges and necessitate changes in clinical techniques: practitioners' skills must accommodate demographic shifts lest clinical interventions falter.

This book's eight chapters focus on cutting-edge approaches to assessment and treatment of the earliest signs of aging. Topics selected represent areas where technology and improved understanding of cellular biology have advanced considerably in the past two decades. Chapters, although distinct, are unified by several important themes:

- Newer, noninvasive clinical interventions and therapeutics offer viable alternatives for younger patients seeking cosmetic enhancements. These entry-level procedures often accommodate patients' clinical needs as well as life styles (e.g., time away from work).
- With changing patient demographics, matching clinical technique to patients' unique skin type, tone, and color is crucial. When possible, recommendations reference the Fitzpatrick rating scale.
- Patients seeking cosmetic enhancements have definite expectations, and patient counseling is imperative. Managing patient expectations is medically ethical and essential. Apart from discussing obvious issues of procedures, contraindications, and potential adverse effects, dermatologists must convey a realistic assessment of predicted outcome and determine if patients have similar expectations. Although time-consuming, informed consent procedures cannot be short circuited.
- Cosmetic dermatology is a field with few established treatment algorithms. Unlike other medical specialties where clinical guidelines are standardized by expert consensus panels, dermatologists must evaluate each patient on a case-by-case basis and strategize accordingly. Detailed treatment planning must include patient participation.

The chapters are also united in another important but unique dimension: all authors are women and each has had one or more of the procedures discussed. Equally significant is the authors' diverse ethnic and racial mix: African American, Latino, Jewish, and Caucasian. Why female authors who are ethnically and racially diverse? These experiential characteristics add a depth of understanding and insight that transcend technique and credentials. Each author firmly believes her experiences strengthen therapeutic relationships with patients. Authors' personal self-selected dermatological procedures coupled with their gender, racial, and ethnic experiences resulted in each refining, modifying, and improving clinical techniques within their specialties, bringing an experiential clinical richness that otherwise would be lacking.

Chapter 1, "Anti-aging Medicine As It Relates to Dermatology," by Rafaela M. Quiroga, discusses the clinical science of anti-aging medicine emphasizing the physiological impact of free radical damage and the importance of diet, exercise, and lifestyle changes in the aging process. Jeannette Graf continues the discussion of anti-aging in Chap. 2, "Anti-aging Skin Care Ingredient Technologies," focusing on molecular changes at the cellular level and the impact of nutrients upon physiological processes. Topic discussion goes beyond antioxidants and free radical damage and focuses on the role of peptides, beta-glucan, polyphenols, and other molecular structures of cell life.

"Photoaging and Pigmentary Changes of the Skin" (Chap. 3), by Susan C. Taylor, begins by first differentiating clinical characteristics between intrinsic aging and photoaging and then proceeds to a comprehensive discussion of the clinical characteristics of photoaging and pigmentary changes in Asians, African Americans, and Caucasians.

The history of chemical peels dates back to the Egyptians and has become increasingly popular in the arena of anti-aging medicine. Chapter 4, "Chemexfoliation and Superficial Skin Resurfacing," by Paula E. Bourelly and Angela J. Lotsikas-Baggili, reviews chemical peeling agents and techniques. Since its introduction in 1995, microdermabrasion has gained popularity and is also covered.

In Chap. 5, "Botulinum Toxin," I cover the history, science, and treatment of botulinum toxin. Indications, patient selection, pretreatment considerations, postinjection considerations, complications, and adverse reactions are highlighted. Along with botulinum toxin, my specialty includes tissue augmentation. Tissue augmentation offers an alternative to invasive surgical procedures for facial aging and is the fastest growing segment among plastic and dermatologic procedures. In "Soft Tissue Augmentation" (Chap. 6), I discuss numerous augmentation options, ranging from natural to synthetic fillers, which confront practitioners. Treatment considerations surrounding permanent and temporary fillers are also highlighted.

Chapter 7, "Laser Skin Resurfacing," by Tina S. Alster and Seema Doshi, details ablative and nonablative technologies. Ablative technology has historically led to excellent clinical outcomes, particularly with one or a combination of the CO<sub>2</sub> and Er:YAG lasers, although these procedures usually require significant downtime. Younger patients desiring less aggressive methods of photo rejuvenation or procedures resulting in less downtime are good candidates for the rapidly evolving nonablative procedures. Results achieved with nonablative technology, however, are subtler and take several months. Side-effects profiles can be significant with both approaches, and the importance of clinical technique, postoperative treatment, and patient selection are detailed.

"Sclerotherapy," Chap. 8, by Jonith Breadon, first reviews physiological factors involved in the development of varicose veins, a condition affecting up to 60% of the population, which is associated with pain, lipodermatosclerosis, venous ulcerations, thrombophlebitis, and deep vein thrombosis. Jonith Breadon's discussion of specific techniques, treatment planning, and patient evaluation offers insights that even veteran practitioners will find useful.

Collectively, these eight chapters meet the needs of a diverse target audience. Those wishing information on a single topic only will find the chapters can be read independently. Dermatologists seeking to broaden their expertise will find the presentations up to date, well researched, and clinically relevant. The chapters

do not offer “how to” instruction, but practitioners will find a plethora of issues to consider that will assist them in clinical decision making. Dermatologists by no means have a monopoly on cosmetic enhancements. Other cosmetic specialties will find much useful information that will enrich their patient consultations and clinical practice. Finally, this book will benefit dermatology residents and medical students alike as these topics are core to most medical training curricula.

Many of today’s treatment interventions were nonexistent just 20 years ago. Like other medi-

cal specialists, today’s cosmetic dermatologists are practicing in a time when diagnostics and treatment advances are exploding at an exponential rate. It is truly an extraordinary time for dermatologists and their patients – a time filled with exciting challenges and options. And I hope this book in some small way conveys both the excitement and the challenge!

**Cheryl M. Burgess, M.D.**

November 2004

# Contents

<b>1</b>	<b>Medicine As It Relates to Dermatology</b> . . . . .	<b>1</b>	<b>5</b>	<b>Botulinum Toxin</b> . . . . .	<b>83</b>
	Rafaela M. Quiroga			Cheryl M. Burgess	
<b>2</b>	<b>Anti-aging Skin Care Ingredient Technologies</b> . . . . .	<b>17</b>	<b>6</b>	<b>Soft Tissue Augmentation</b> . . . . .	<b>93</b>
	Jeannette Graf			Cheryl M. Burgess	
<b>3</b>	<b>Photoaging and Pigmentary Changes of the Skin</b> . . . . .	<b>29</b>	<b>7</b>	<b>Laser Skin Resurfacing</b> . . . . .	<b>111</b>
	Susan C. Taylor			Tina Alster, Seema Doshi	
<b>4</b>	<b>Chemexfoliation and Superficial Skin Resurfacing</b> . . . . .	<b>53</b>	<b>8</b>	<b>Sclerotherapy</b> . . . . .	<b>127</b>
	Paula E. Bourelly, Angela J. Lotsikas-Baggili			Jonith Breadon	
				<b>Subject Index</b> . . . . .	<b>167</b>



# List of Contributors

**Tina Alster, M.D., F.A.A.D.**

(e-mail: Tina.alster@skinlaser.com)  
2311 M Street, NW Suite 200  
Washington, D.C. 20037, USA

**Jeannette Graf, M.D., F.A.A.D.**

(e-mail: JOG88@aol.com)  
88 Bayview Ave.  
Great Neck, NY 11021, USA

**Paula E. Bourelly, M.D.**

(e-mail: pbourelly@yahoo.com)  
2412 Norbeck Farm Place  
Olney, MD 20832, USA

**Angela J. Lotsikas-Baggili, M.D.**

(e-mail: lotsikaa@yahoo.com)  
1610 Grace Church Road  
Silver Spring, MD 20910, USA

**Jonith Breadon, M.D.**

2525 N. Lincoln Ave.  
Chicago, IL 60614, USA

**Rafaela M. Quiroga, M.D.**

(e-mail: rafaeladermdoc@hotmail.com)  
5353 Columbia Pike Suite #604  
Arlington VA 22204, USA

**Cheryl M. Burgess, M.D., F.A.A.D.**

(e-mail: Cheryl.burgess@  
ctr4dermatology.com)  
2311 M Street, NW Suite 504  
Washington, D.C. 20037, USA

**Susan C. Taylor, M.D.**

(e-mail: Drstaylor1@aol.com)  
932 Pine Street  
Philadelphia, PA 19107, USA

**Seema Doshi, M.D.**

Washington Institute of Dermatologic Laser  
Surgery, Washington, D.C., USA

# Anti-Aging Medicine As It Relates to Dermatology

Rafaela M. Quiroga

## Core Messages

- Anti-aging medicine physicians, scientists, and researchers are dedicated to the belief that the process of physical aging in humans can be slowed, stopped, or even reversed through existing medical and scientific interventions.
- Possible theories of the aging process include the free radical theory of aging, oxidation, cell senescence, and cleavage of telomere during DNA synthesis.
- A good diet slows the aging process and adds healthier years to life.
- A therapeutic guide for vitamin supplements and recommended anti-aging doses is provided.

## Contents

1.1	<b>Introduction</b> . . . . .	2
1.2	<b>The Clinical Science of Anti-Aging Medicine</b> . . . . .	2
1.3	<b>The Aging Process</b> . . . . .	2
1.4	<b>Free Radical Theory of Aging</b> . . . . .	3
1.4.1	Antioxidizing Processes . . . . .	3
1.5	<b>Diet and Nutrition</b> . . . . .	3
1.6	<b>Hormonal Regulation of Aging</b> . . . . .	4
1.6.1	Adrenopause . . . . .	5
1.6.2	Menopause . . . . .	5
1.6.3	Andropause . . . . .	5
1.6.4	Somatopause . . . . .	6
1.7	<b>Growth Hormone in the Aging Process</b> . . . . .	6
1.8	<b>Consequences of Reduced Growth Hormone Secretion on the Skin</b> . . . . .	6
1.9	<b>Can Human Growth Hormone Reverse the Effects of Aging?</b> . . . . .	8
1.9.1	<b>Growth Hormone Secretagogues</b> . . . . .	8
1.10	<b>Side Effects of Growth Hormone Therapy</b> . . . . .	9
1.11	<b>A Brief Guide to Anti-Aging Supplements and Growth-Hormone-Releasing Nutrients for the Skin</b> . . . . .	10
1.12	<b>Oral Antioxidant Nutrients</b> . . . . .	10
1.12.1	Vitamin C . . . . .	10
1.12.1.1	Food Sources . . . . .	11
1.12.1.2	Risks with High Doses . . . . .	11
1.12.2	Vitamin E . . . . .	11
1.12.2.1	Role in the Body and Consequences of Deficiency . . . . .	11
1.12.2.2	Recommended Daily Allowance . . . . .	11
1.12.2.3	Food Sources . . . . .	12
1.12.2.4	Risks with High Doses . . . . .	12
1.12.2.5	Interactions with Other Nutrients and Drugs . . . . .	12
1.12.3	Carotenoids . . . . .	12
1.12.3.1	Role in the Body and Consequences of Deficiency . . . . .	12
1.12.3.2	Recommended Daily Allowance . . . . .	13
1.12.3.3	Food Sources . . . . .	13
1.12.3.4	Risks with High Doses . . . . .	13
1.12.4	Selenium . . . . .	13
1.12.4.1	Role in the Body and Consequences of Deficiency . . . . .	13
1.12.4.2	Recommended Daily Allowance . . . . .	13
1.12.4.3	Food Sources . . . . .	13
1.12.4.4	Risks with High Doses . . . . .	14
1.12.4.5	Interactions with Other Nutrients . . . . .	14
1.13	<b>Glycemic Index</b> . . . . .	14
1.14	<b>Final Remarks</b> . . . . .	14
	<b>References</b> . . . . .	14

Old age is the most unexpected of all things that happen to man.

*Leon Trotsky*



## 1.1 Introduction

Changes in diet and increasing exercise, together with a regimen of antioxidants, nutritional supplements, and growth factors, can alter how the genes express themselves. Both factors can greatly enhance the healing capability of the skin and can improve the results of cosmetic surgeries.

Beyond the obvious advantages of a balanced diet and exercise there are the physiological ones that help people feel more alive with renewed and vital well-being.

## 1.2 The Clinical Science of Anti-Aging Medicine

Anti-aging medicine is practiced by physicians, scientists, and researchers dedicated to the belief that the process of physical aging in humans can be slowed, stopped, or even reversed through existing medical and scientific interventions. This specialty of medicine is based on the very early detection and prevention of age-related diseases. Physicians practicing anti-aging medicine seek to enhance the quality of life as well as its length, limiting the period of illness and disability toward the end of one's life. Anti-aging medicine encompasses lifestyle changes (diet and exercise); hormone replacement therapies, as needed, determined by a physician through blood testing (DHEA, melatonin, thyroid, human growth hormone, estrogen, testosterone); antioxidants and vitamin supplements; and testing protocols that can measure not only hormone levels and blood chemistry but every metabolic factor right down to the cellular level.

## 1.3 The Aging Process

Aging can be viewed as the accumulation of changes in cells and tissues resulting from a greater disorderliness of regulatory mechanisms that result in reduced robustness of the organism to encountered stress and disease. The notion of greater disorderliness in aging is illustrated by the erosion of the orderly neuroendocrine feedback regulation of the secretion of luteinizing hormone (LH), follicle stimulating hormone (FSH), adrenocorticotrophic hormone (ACTH) and growth hormone (GH). These changes are manifested as menopause, andropause, adrenopause, and somatopause.

Skin aging is part of the slow decline in appearance and function that appears to be attributed in large part to the drastic decline of hormones in the body after adulthood. At the cellular level, several processes are involved in the physiology of aging and the development of some age-related diseases. The process of apoptosis signifies the process of nontraumatic and noninflammatory cell death [1].

Dysregulation of apoptosis has been implicated in the increased incidence of cutaneous malignancies that are more prevalent in older individuals, such as basal cell carcinoma, squamous cell carcinoma, and malignant melanoma. Cell senescence limits cell divisions in normal somatic cells and may play a central role in age-related diseases. Telomeres are thought to play a role in cellular aging and might contribute to the genetic background of human aging and longevity. It has been speculated that the limited proliferation potential of human cells is a result of the telomere shortening that occurs during DNA synthesis at each cell division. Photoaging may accelerate the shortening of telomeres and push cells into senescence sooner. That could be the reason why various growth factors may affect the speed and quality of wound healing [2]. Biochemical insults also arise within aging cells, in part from the action of reactive oxygen species generated and scavenged incompletely throughout the cell cycle. Aging-associated changes also occur between and among cells via alterations in the intercellular matrix, the intercellular exchange of

trophic factors, the release of inflammatory cytokine mediators, and the degree of infiltration by other associated cell types. In addition, the quantity and distribution of various growth factors may affect wound healing [2]. Decline of DNA repair in combination with loss of melanin increases the risk of photocarcinogenesis and can also cause the decline of enzymatically active melanocytes (10–20% each decade) that contributes to increased sensitivity to ultraviolet (UV) radiation.

However, it is not known why free radical damage does not adversely affect all of the body's cells (e.g., gonadal germ cells) [3].

## 1.4 Free Radical Theory of Aging

Antioxidizing nutrients are believed to play a role in the prevention and treatment of a variety of chronic diseases. The proposed mechanism by which antioxidants protect cells from oxidative stress is by scavenging free radicals and halting lipid peroxidation chain reactions, which can cause DNA damage [4].

### 1.4.1 Antioxidizing Processes

Two forms of chemical reactions, oxidation and reduction, occur widely in nature. Oxidation is the loss of electrons, and reduction is the gain of electrons. Oxidation and reduction reactions always occur in pairs. Highly reactive molecules can oxidize molecules that were previously stable and may cause them to become unstable species, such as free radicals. A free radical is a chemical with an unpaired electron that can be neutral, positively charged, or negatively charged. Thus, without termination by an agent such as an antioxidant, a single free radical can damage numerous molecules. A certain amount of oxidative function is necessary for proper health. For example, oxidation processes are used by the body's immune systems to kill microorganisms [5].

Cells contain a number of antioxidants that have various roles in protecting against free radical reactions. The major water-soluble anti-

oxidant metabolites are glutathione (GSH) and vitamin C (ascorbic acid), which reside primarily in the cytoplasm and mitochondria. Many water-soluble enzymes also catalyze these reactions. Glutathione peroxidase catalyzes the reaction between GSH and hydrogen peroxide to form water and oxidized GSH, which is stable [6]. Vitamin E and the carotenoids are the principal lipid-soluble antioxidants. Vitamin E is the major lipid-soluble antioxidant in cell membranes that can break the chain of lipid peroxidation. Therefore, theoretically, it is the most important antioxidant in preventing oxidation of these fatty acids. Vitamin E is recycled by a reaction with vitamin C [7].

Despite the actions of antioxidant nutrients, some oxidative damage will occur, and accumulation of this damage throughout life is believed to be a major contributing factor to aging and disease [6].

## 1.5 Diet and Nutrition

A good diet slows aging and can improve overall success of surgical procedures and wound healing. Among other benefits, a good diet:

- Provides the food, water, and oxygen that cells need to reproduce, transmit information, and repair damage
- Assures the body of a continuous supply of usable energy, which improves emotional stability and energy levels
- Helps eliminate free radical damage, damage that can increase risk of cancer and other degenerative diseases
- Decreases the risk of cancer, arteriosclerosis, hypertension, heart disease, osteoporosis, senility, and depression
- Synchronizes the body, helping people function physically, mentally, and emotionally at peak efficiency
- Adds healthier years to life

1

The diet that will most support healthy longevity follows these principles: It's nontoxic. That means it contains a minimum of preservatives, additives, pesticides, antibiotics, food coloring, and chemical flavoring. The diet should contain enough nutrients to satisfy daily needs. Since most fresh fruits and vegetables lose much of their nutritional value within hours after being picked, it is necessary to supplement with vitamins and minerals.

*According to the American Journal of Public Health, studies show that less than one-third of Americans meet the U.S. government's Healthy People 2000 goal of eating five or more servings of fruits and vegetables per day; people eat only 1.2 servings of fruits and 3.1 servings of vegetables daily.*

Another element of the healthy diet beneficial for women should be soy proteins due to the phytoestrogens that regulate endogenous estrogen production, which is helpful in easing hot flashes and hormonal acne associated with menopause. Topical estrogen induces an increase in skin thickness through proliferation, resulting in decreased rhytids. Scientists at the University of Pennsylvania School of Medicine found that soybeans contain a protease inhibitor called the Bowman-Birk inhibitor, which is so versatile against various cancers that it has been dubbed "the universal cancer preventive agent."

Natural fats provide a concentrated form of energy and create the environment in which fat soluble vitamins can be digested; they also provide the essential fatty acids that the body uses to maintain its cellular structure. Examples of fat are "saturated," from dairy, meat, and fish products; "unsaturated," from vegetable and fish oils; "polyunsaturated," such as sunflower seed oil and sesame seed oil; and "hydrogenated," such as margarine and highly heated or reheated fats.

The American Heart Association and the National Cholesterol Education Project recommend that the "prudent" diet for everyone, regardless of gender, race, or age, should not exceed 300 mg of cholesterol daily and 65 mg total fat for the person who eats an average of 2,000 daily, inclusive of 22 g of saturated fat.

## 1.6 Hormonal Regulation of Aging

Aging involves a decline of GH, which causes the immune system response to decline and the amount of oxygen and free radicals to increase. The skin suffers from the consequences of the decline in GH, which is reduced nourishment and repair of cells in the different tissues. The overall functions of the skin decrease with aging. The decline is noted in cell replacement, sensory perception, thermal regulation, and chemical clearance. Also, there is a higher threshold for pain, predisposing to skin irritations, ulcerations, and wounds [8].

Additional changes of skin aging include flattening of the dermal-epidermal junction, which decreases the contact surface between the dermis and epidermis. This change may compromise communication and nutrient transfer between skin layers. There is a decrease in epidermal filaggrin, a protein required to bind keratin filaments into macrofibrils, that contributes to skin dryness and flaking. In addition, there is an increased dermal separation that may cause increased blistering or tearing.

The endocrine system regulates body composition, fat deposition, skeletal mass, muscle strength, metabolism, body weight, and physical well-being. Multiple endocrine changes evolve with aging in all species and, not surprisingly, some of the physiologic manifestations of aging are related to the effects of declining hormone levels. The central nervous system (CNS) regulates the pituitary gland, which secretes hormones to target tissues that, in turn, produce substances that feed back on the hypothalamic-pituitary axis. This feedback-control network can be assessed via novel entropy statistics.

In humans, aging is associated with a decrease in the gonadal production of estrogen in females (menopause) and testosterone in males (andropause), the adrenal production of dehydroepiandrosterone (DHEA) and DHEA sulfate (DHEA-S) (adrenopause), and a decrease in the activity of the GH/insulin-like growth factor (IGF) axis (somatopause). Replacing hormones that decline with age had been shown to have a

broad anti-aging and anti-disease effect on the skin and in the body. As a result, hormone replacement regimens are being developed as a strategy to delay or prevent some of the consequences of aging.

### 1.6.1 Adrenopause

The enzymatic machinery of the adrenal zona reticularis fails in aging men and women. However, the ability of the zona fasciculata to produce cortisol is preserved (based on ACTH infusion, insulin tolerance, and metyrapone testing). Mineralocorticoid and glucocorticoid receptors in the hippocampus are variably down regulated in aging humans. Excessive lifelong adrenal cortisol feedback on the brain may exacerbate the aging-associated loss in neuronal synapses and plasticity. Potential implications of aging skin includes a decrease in vascular responsiveness due to involution of the dermal vascular bed, which decreases thermoregulation and contributes to skin pallor; there is a decrease in subcutaneous fat and changes in distribution that may limit conductive heat loss that decreases the protective ability in bony areas such as the ischial tuberosities; and there is a delayed recovery of the stratum corneum's function as a barrier, which may increase the penetration of certain types of topical medications leading to systemic absorption [9].

### 1.6.2 Menopause

There is still no known biochemical signal that reliably indicates the onset of menopause. However, serum FSH levels tend to rise in regularly menstruating as well as premenopausal women (42–50 years of age). The pulsatility and orderliness of LH release also change before menstrual cyclicity falters [10]. Estrogen secretion in perimenopause is variable and includes intervals of increased production. A greater stimulation by FSH may increase follicular aromatase activity and induce estrogen excess while inhibin concentrations fall perimenopausally and contribute to heightened FSH release.

Physical complaints such as breast tenderness, irregular menstrual bleeding, dyspareunia, and hot flushes may precede the onset of anovulatory cycles in perimenopause in addition to emotional concerns such as disrupted sleep, fatigue, tension, and irritability, which are equally represented among menopausal women in North America [11]. Skin changes that may occur include hyperpigmentation as well as wrinkles, laxity, pallor, and pruritus. These changes are associated with estrogen deprivation, which leads to decreased skin elasticity and blood supply [12]. Histologically, although the stratum corneum is unaltered in thickness, there is apparently a slow replacement of neutral lipids adversely affecting the barrier function [13, 14].

### 1.6.3 Andropause

In the hypogonadal male, reduced libido is often accompanied by diminished well-being and/or depression that may be relieved by androgen replacement [15]. Cognitive decline, visceral obesity, osteopenia, and relative sarcopenia also accompany androgen deficiency in aging [16]. These conditions respond favorably to androgen supplementation, especially in men with very low testosterone levels [17]. Enhanced physical performance has not been established in this context. Few studies have examined whether testosterone supplementation enhances cognitive function in elderly men [18]. Although it appears that neoplastic transformation of prostate tissue is not elicited by physiologic testosterone repletion, proliferation of existing androgen-responsive carcinomas may be stimulated. Thus, a normal prostate-specific antigen (PSA) and prostatic digital examination should precede any androgen treatment in older individuals.

Skin decreases in elasticity, extensibility, and turgor. Appendages, including hair follicles, apocrine, and eccrine glands, are decreased in number. Pacinian and Meissner's corpuscles, responsible for pressure and light touch sensation, are similarly decreased. The epidermis may exhibit variable thickness, cell size, and shape with occasional nuclear atypia.



### 1.6.4 Somatopause

Gender markedly influences GH secretion in young adults. Premenopausal women exhibit a two-fold less rapid decline than men in daily GH production with increasing age. Young women also manifest less vulnerability to the suppressive effects of increased total body fat and reduced physical fitness on GH secretion [19]. An important ongoing clinical issue relates to the uncertain role of sex-hormone deficiency in the aging-related impoverishment of GH and IGF-I production in both women and men [20]. Preliminary data from clinical studies raise the possibility that combined GH and androgen repletion in older men can have an additive effect on increasing muscle mass [19].

Levels of the nutritional signaling peptide leptin, mostly produced in white adipose tissue, conveys signals to the hypothalamus about fat stores and, in response, hypothalamic efferents regulate food intake and energy expenditure. Leptin inhibits the hypothalamic release of the orexigenic (appetite-inducing) peptide neuropeptide Y (NPY) and activates the sympathetic nervous system. The latter stimulates lipolysis in adipose tissue via the beta-3 adrenergic receptor, cAMP accumulation, and increased activity of mitochondrial uncoupling protein (UCP)-3, thus generating heat (which is dissipated) rather than ATP (which is stored). Leptin-receptor signaling may be attenuated in aging [21].

The aging process causes certain areas of the face to undergo fat atrophy while others experience a persistence or hypertrophy of fat. Fat atrophy occurs in the periorbital, forehead, buccal, temporal, and perioral areas. Fat hypertrophy, however, is seen submentally, in the jowl, lateral nasolabial fold, lateral labiomental crease, and lateral malar areas. The suborbital area may display atrophic changes with concavities and evidence of the underlying orbital rim or hypertrophy with infraorbital fat accumulation and festooning [22].

### 1.7 Growth Hormone in the Aging Process

GH is the most abundant pituitary hormone. Although GH and prolactin are closely related, GH secretion depends upon hypothalamic stimulation, without which GH secretion falls to low levels and somatotrophs atrophy. Growth hormone-releasing hormone (GHRH), in full sequence a 44-amino-acid peptide, is the principal identified hypothalamic stimulator of pituitary GH synthesis and secretion, activating specific GHRH receptors on the surface of pituitary somatotrophs. GHRH and GHRH-related peptides have a very restricted distribution in the CNS but are also synthesized in gut, pancreas, and gonads, where their physiological roles are still uncertain. Somatostatin [somatotropin-release-inhibiting factor, (SRIF)], a group of 14- and 28-amino-acid peptides, is a potent noncompetitive inhibitor of GH secretion. As with LH and other pituitary hormones, the pattern of GH secretion is episodic, with six to eight pulses per day and very low levels between pulses. Some of these pulses are associated with meals, stress, exercise, or slow-wave sleep. The traditional view has been that the pattern of episodic GH secretion arises from the interaction of GHRH and SRIF secretion modulated by peripheral feedback by circulating IGF-I and other factors.

### 1.8 Consequences of Reduced Growth Hormone Secretion on the Skin

GH declines with age in every animal species that has been tested to date. In humans, the amount of growth hormone after the age of 21 to 31 falls about 14% per decade, so that the total 24-hour growth hormone production rate is reduced by half by the age of 60. In numerical values, humans produce on a daily basis about 500  $\mu\text{g}$  at 20 years of age, 200  $\mu\text{g}$  at 40, and 25  $\mu\text{g}$  at 80 [23]. The skin of adults with growth hormone deficiency (GHD) is thin, dry, and cool, rendering venous access difficult. These changes probably arise because of the loss of a direct anabolic influence of GH on skin cells exacer-

bated by reduced cardiac output. In addition, GH regulates eccrine sweat glands, and sweating is impaired in GHD, very likely contributing to poor exercise capacity.

Many of the undesirable changes that accompany aging mimic those manifest in the GHD syndrome, including central obesity, muscle atrophy, exercise intolerance, decreased metabolic rate, dyslipidemia, cardiovascular deterioration, osteopenia, thinning of skin, mild anemia, loss of vigor, sleep disturbances, and depression. Aging is thus a partial phenotype of adult GHD. This has prompted speculation that pituitary somatotroph activity may be a pacemaker of aging and has raised the possibility that GH supplementation might retard geriatric deterioration because replacement therapy reverses most features of GHD in young adults.

Most organic adult GHD arises from pituitary lesions. The loss of GH secretion associated with aging alone results from hormonal changes upstream of the pituitary. Pituitary responsiveness to GHRH persists in aging, although the magnitude of GH release may decline somewhat. The practical implication of this difference is that GH secretagogues should be useful for stimulating GH secretion in normal older people whereas they are ineffective in most organic forms of adult GHD. At any age, including advanced ages; individuals with organic GHD have significantly lower measures of basal and stimulated GH secretion than do age-matched normal subjects [24].

A careful study of the aging face reveals it to be more than just surface textural wrinkling or loose skin. Changes in three-dimensional topography are responsible for the distinctive phenotypic presentation of the face throughout life. These geometric alterations are secondary to apportioning in the fat compartments and result in the fat dysmorphism characteristic of senescence. Redistributing this fat can rebalance the facial fat compartments and mimic the facial structure present in youth [22].

There is no single sign or symptom that is pathognomonic of GHD in adulthood or provides any biological end point for diagnosis. A low serum IGF-I in adults suggests GHD, but a normal value does not exclude the disease. The

“gold standard” for establishing a biochemical diagnosis is the peak GH response to insulin-induced hypoglycemia in an insulin tolerance test (ITT). Other GH stimuli such as arginine, glucagon, L-dopa, and clonidine are used in provocative tests, but none is as powerful as the ITT [25]. Despite vast clinical experience with the ITT, controversy remains over what peak GH value constitutes a diagnostic cutoff. Most patients respond to insulin-induced hypoglycemia with a peak GH greater than 5 ng/ml. “Severe GHD” is currently defined by a peak GH less than 3 ng/ml [26]. Because of the lack of standardization of GH assays, each laboratory should ideally establish its own diagnostic threshold values rather than blindly accepting these recommended cutoffs. The diagnosis of GHD is increasingly likely when additional anterior pituitary hormones are found to be deficient, as GH is one of the first of such hormones to be lost in adult hypopituitarism of most causes. Hence, isolated adult GHD should be confirmed with two biochemical tests. Although an ITT is safe when carefully administered, it is contraindicated in the setting of documented ischemic heart disease and seizure disorders [26]. Some investigators do not perform the ITT in anyone over 65 years of age because of potential occult cardiovascular disease (CVD) [25]. In such cases, arginine (or arginine plus GHRH) is probably the best alternative.

Unfortunately, distinguishing organic GHD from the hyposomatomedinemia of aging is a challenge. Although GH secretion is lower at any age in patients with organic GHD than in age-matched normal subjects, the spread between these groups diminishes with advancing age such that GH levels differ by only 13% between elderly adults with GHD and their normal peers [27]. Thus, confirming GHD in an older person may not be possible, especially if only one or no additional pituitary hormones are deficient [25]. The situation is similar for morbidly obese patients in whom GH secretion may be suppressed to a similar degree as in organic GHD. Even among people in whom the diagnosis of normal, age-related, hyposomatomedinemia is clear, the question remains whether such individuals might benefit from restoration of GH to youthful levels.



## 1.9 Can Human Growth Hormone Reverse the Effects of Aging?

GH had proven tissue healing effects, and cells regenerate and repair faster, accelerating the process of wound healing in patients injured, severely burned, recovering from surgery, or severely malnourished. All these effects take place through new formation of collagen. The impact of GH treatment on body composition in adult GHD is unequivocal: fat mass and volume are decreased (by 7–15%), with the greatest reductions seen in abdominal visceral depots; lean body mass and skeletal muscle volume are increased (by 5–10%). Most studies showed [28, 29] little change in overall body weight but rather a shift from fat to lean mass [30, 31]. Although the increase in lean body mass can be partially accounted for by GH-induced water retention, observed elevations in total-body  $K^+$  demonstrate that GH also promotes genuine muscle growth. These favorable body composition changes are more pronounced in men than women and more so in young patients with low GH binding protein levels.

Studies of the effect of GH replacement on psychological and social end points in adults with GHD have universally reported a therapeutic benefit [32]. Improvements were found in subjective well-being, mood, energy, sleep, emotional reaction, behavior, pain perception, and overall quality of life [33].

Although adult growth hormone replacement therapy is controversial, the initial dose usually recommended is 150–300 ng SQ qhs (approximately 2–4 mg/kg per day). Older patients are started at the lower level of 150 ng, and dose titration should be done monthly or at longer intervals controlling IGF-1 level clinical response, side effects, and individual assessment. The goal dose is based on finding levels of IGF-1 at or slightly below the 50th percentile for age and gender unless side effects are significant. Cancer screening should be done periodically and routinely [34, 35].

At this time, the best therapy against aging is to limit the damage to the DNA with antioxidants, vitamins, and minerals, and try to increase the levels of GH naturally with diet, exercise, and growth hormone releasers.

### 1.9.1 Growth Hormone Secretagogues

Because the aging-related decline in GH secretion results from changes upstream of the pituitary, hormonal replacement can theoretically be achieved with GHRH or growth-hormone-releasing peptides (GHRPs). There are several conceptual advantages of these therapies over exogenous GH itself [32]. First, even when administered continuously, they preserve the physiological pulsatility of GH release, presumably mediated via intermittent endogenous somatostatin secretion. In addition, the normal negative feedback regulation by IGF-I upon GH release confers relative protection against over-treatment with these agents.

The only GH secretagogue presently approved for use as replacement therapy is GHRH (1–29)  $NH_2$  (Geref, Serono), which has been licensed to treat childhood GHD but is being tested in adults as well. Various GHRPs and nonpeptide GHRP mimetics are also under investigation in elderly subjects [32]. Only short-term trials have been published to date, sufficient to assess only hormonal effects. IGF-I has been raised to youthful levels in older individuals with once- or twice-daily subcutaneous injections of GHRH as well as with infusions or daily oral preparations of GHRPs. Data on body composition and functional end points are being compiled. Side effects resulting from inadvertent overtreatment with secretagogues should be less common than with exogenous GH because of the moderating effects of feedback regulation; studies to date have generally found this to be true. However, some patients do report typical GH-related symptoms of fluid retention as well as allergic reactions at injection sites. Current GH secretagogue formulations delivered transnasally and orally are limited and quite short-acting and therefore are unpredictable. For these compounds to become clinically useful, development of more potent preparations, adjuvants to enhance potency, or synergistic GHRH-GHRP combinations is necessary.

## 1.10 Side Effects of Growth Hormone Therapy

The side effects of GH therapy arise from the hormonal impact of overreplacement because rhGH is identical to the endogenous hormone and thus should not elicit hypersensitivity reactions, except in the very rare patients with congenital GH gene deletions. Fluid retention due to the antinatriuretic actions of GH is by far the most common untoward effect among adults with GHD receiving replacement therapy. In experimental trials, ~40% of subjects reported clinically apparent edema, ~20% developed joint swelling (especially in the hands) and/or noninflammatory arthralgias, and ~15% suffered from myalgias [36]. Arthralgias probably result from fluid accumulation in joint spaces as inflammatory changes and radiographic anomalies are not found. These side effects are generally mild and resolve within a few weeks of therapy. However, ~10% of subjects develop carpal tunnel syndrome. Increased hypertension is typically not reported even after up to 3 years of treatment. Gynecomastia and atrial fibrillation have occasionally been attributed to GH administration in elderly patients. All GH-related side effects are dose related, and older people are particularly susceptible to them.

As GH directly antagonizes insulin action, a theoretical risk of its use is hyperglycemia. This is a particularly important concern for the elderly as ~40% of people 65–74 years old and ~50% of those older than 80 years have impaired glucose tolerance or diabetes mellitus [36]. Careful studies specifically examining this risk in GHD adults have shown that GH replacement does, indeed, initially decrease insulin sensitivity. However, the effect is reversed within 3–6 months of therapy, and carbohydrate metabolism returns to baseline. This is presumably due to the counteracting effect of losing central body fat and thus increasing insulin sensitivity. Although GH-induced increases in basal insulin or glucose have been seen in some studies, these values generally remained within normal ranges and have never been associated with significant increases in hemoglobin A<sub>1c</sub>.

Warnings have been voiced that GH could have mitogenic properties. These theoretical concerns derive from highly controversial *in vitro* data obtained with a variety of cell lines from the observation that most human solid tumors express IGF-I receptors [37] and from epidemiological evidence that patients with acromegaly have increased incidences of colon and breast cancer [38, 39]. At present, the prudent course of action for patients receiving GH would be to adhere strictly to guidelines regarding prostate examinations and PSA levels in men and breast examinations and mammograms in women. Doctors should also inform high-risk patients of these reports. However, it is inappropriate to extrapolate conclusions drawn from patients with acromegaly who have grossly elevated GH levels to adults with GHD receiving only physiological restitution.

Reports of associations between circulating IGF-I concentrations and the development of prostate and breast cancer have further raised concerns about the long-term risks of GH therapy [40]. However, IGF-I levels in the groups with increased cancer incidences were higher than those that would be sought in carefully titrated physiological replacement therapy. Thus, the applicability of these observations to the latter situation is questionable. Furthermore, there is no strong evidence for increased incidences of prostate or breast cancer in patients with acromegaly, which argues against a causal relationship between IGF-I and these malignancies.

GH administration is currently contraindicated for patients with active malignancy, benign intracranial hypertension, and proliferative or preproliferative diabetic retinopathy [34]. Early pregnancy is not a contraindication, but GH therapy may be discontinued in the second trimester as a GH variant is secreted by the placenta.

One setting in which GH therapy has proved detrimental is in the critically ill. These individuals have impairments of both GH secretion and action. Hence, two randomized, multicenter trials were undertaken to determine whether GH treatment in several hundred intensive care unit patients might speed recovery [41].

Unexpectedly, there was a near doubling of mortality, from 20 to 38%, in both studies.

### 1.11 A Brief Guide to Anti-Aging Supplements and Growth-Hormone-Releasing Nutrients for the Skin

Updated recommendations, developed in a collaboration between the United States and Canada, incorporate three types of values: the estimated average requirement (EAR), the recommended dietary allowance (RDA), and the tolerable upper intake level (UL). Collectively, these values are referred to as dietary reference intakes (DRIs). EAR is the intake value that is estimated to meet the requirements of a defined indicator of adequacy in 50% of the population (note that this means that the needs of 50% of the population are not being met). RDA is the dietary intake level that is sufficient to meet the nutrient requirements of nearly all individuals in the group. UL is not intended to be a recommended level of intake but represents the highest level of intake that is unlikely to have any adverse health effects in most individuals. It is important to note that the UL is not meant to apply to individuals receiving supplements under medical supervision and should not be used to limit doses investigated in clinical trials [42]. DRIs for antioxidant nutrients were developed by considering the roles of antioxidant nutrients in decreasing the risk of diseases, including chronic diseases and other conditions, and by interpreting the current data on intakes in the United States and Canada.

### 1.12 Oral Antioxidant Nutrients

In light of new research on the importance of these vitamins to overall health, the Institute of Medicine (IOM) in Washington, D.C., recently released new dietary guidelines for intake of the antioxidant nutrients vitamin C, vitamin E, carotenoids, and selenium. In addition, a variety of other nutrients are believed to be involved in antioxidant processes. According to the IOM, a dietary antioxidant is defined as “a substance

in foods that significantly decreases the adverse effects of reactive species, such as reactive oxygen and nitrogen species, on the normal physiological function in humans” [43].

#### 1.12.1 Vitamin C

Vitamin C is the predominant plasma antioxidant. This water-soluble vitamin scavenges plasma free radicals and prevents their entry into low-density lipoprotein (LDL) particles [44]. Vitamin C regenerates active vitamin E and increases cholesterol excretion and improves endothelium-dependent vasodilation and reduces monocyte adhesion. Supplementation with vitamin C (1,000 mg) and vitamin E (800 IU) before the ingestion of a high-fat meal has been found to reverse endothelial dysfunction and vasoconstriction following the meal.

On the skin, the function of vitamin C is the production of collagen, which forms the basis for connective tissue in bones, teeth, and cartilage. It also plays an important role in wound healing, immunity, and the nervous system, and acts as a water-soluble antioxidant. Because vitamin C is water soluble, its antioxidant functions take place in aqueous body compartments. It also helps protect low-density lipoprotein cholesterol (LDL-C) against free radical damage. As an antioxidant, it helps protect against cancer [43], CVD [45, 46], and certain effects of aging [47].

Severe deficiency of vitamin C leads to scurvy, which includes symptoms of bleeding gums, joint pain, easy bruising, dry skin, fluid retention, and depression. Marginal deficiencies may play a role in the development of cancer [48, 49], CVD [50], hypertension [51], decreased immunity, diabetes [52], and cataracts [53]. The RDA for vitamin C is 75 mg/day for women and 90 mg/day for men. Smokers require an additional 35 mg/day due to increased oxidative stress and other metabolic differences. The UL for vitamin C is 2,000 mg/day [43]. It remains possible that higher vitamin C intake may be beneficial in the treatment or prevention of certain diseases, particularly cancer and respiratory disorders.

### 1.12.1.1 Food Sources

Important sources of vitamin C include citrus fruits, strawberries, kiwifruit, papaya, and vegetables such as red peppers, broccoli, and brussels sprouts. Vitamin C can easily be destroyed during cooking and storage; therefore, food handling and preparation can have a significant effect on vitamin C content.

### 1.12.1.2 Risks with High Doses

Vitamin C is relatively safe at high doses, but intake of doses higher than 2 g/day may result in diarrhea, nausea, stomach cramping, excess urination, and skin rashes [54]. More recently, 4 g/day has been said to be well-tolerated and safe, except in some patients with renal dysfunction [55]. In rare cases, daily 2-g doses have been associated with kidney stones [56]. Intake of greater than 1 g/day increases oxalate excretion without clinical consequence in normal healthy individuals but could lead to adverse consequences in those with underlying renal disease. Dietary needs of vitamin C are increased by smoking, pollutants, aspirin, alcohol, estrogen, antibiotics, and corticosteroids. It may also interact with various laboratory tests, causing false readings [7].

## 1.12.2 Vitamin E

Vitamin E is the name given to a group of eight fat-soluble compounds. The most abundant form of vitamin E is  $\alpha$ -tocopherol, and this is the only form that is active in humans [43]. However, research suggests that the mixed forms found in food may be more beneficial than the isolated  $\alpha$ -tocopherol form that is used in some supplements [7].

Vitamin E supplements are available in natural forms from soybean or wheat germ oil, indicated by a “d” prefix (also referred to as the stereoisomer RRR- $\alpha$  tocopherol), and synthetic forms manufactured from purified petroleum oil, indicated by a “dl” prefix (which includes

eight stereoisomers of  $\alpha$ -tocopherol, four 2R-stereoisomers, and four 2S-stereoisomers). The most active and available form of vitamin E is  $\alpha$ -tocopherol. Vitamin E is the predominant antioxidant in LDL. This vitamin also inhibits platelet activation and monocyte adhesion.

### 1.12.2.1 Role in the Body and Consequences of Deficiency

The primary role of vitamin E is to act as an antioxidant. Vitamin E is incorporated into the lipid portion of cell membranes and other molecules, protecting these structures from oxidative damage and preventing the propagation of lipid peroxidation [11]. Vitamin E appears to have protective effects against cancer [35], heart disease [4], and complications of diabetes [4]. It is necessary for maintaining a healthy immune system [57], and it protects the thymus and circulating white blood cells from oxidative damage. Also, it may work synergistically with vitamin C in enhancing immune function [5]. In the eyes, vitamin E is needed for the development of the retina and protects against cataracts and macular degeneration [58].

Vitamin E deficiency is rare and occurs mostly in people with chronic liver disease and fat malabsorption syndromes such as celiac disease and cystic fibrosis. It can lead to nerve damage, lethargy, apathy, inability to concentrate, staggering gait, low thyroid hormone levels, decreased immune response, and anemia. Marginal vitamin E deficiency may be much more common and has been linked to an increased risk of CVD and cancer [42].

### 1.12.2.2 Recommended Daily Allowance

Of the fatty acids, polyunsaturated fatty acids are most likely to undergo oxidation in the presence of oxygen or oxygen-derived radicals. The necessary amount of vitamin E depends on the amount of polyunsaturated fatty acids in the diet. The greater the amount of these fats in

1

the diet, the greater the risk they will be damaged by free radicals and exert harmful effects. Because it is impossible to obtain a high intake of vitamin E without consuming a high-fat diet, use of vitamin E supplements is often recommended [4].

### 1.12.2.3 Food Sources

The best sources of vitamin E are certain vegetable oils (including wheat germ oil, hazelnut oil, sunflower oil, and almond oil), wheat germ, whole grain cereals, and eggs.

### 1.12.2.4 Risks with High Doses

According to the IOM, vitamin E is relatively safe at doses as high as 1,000 mg/day [11]. Short-term administration of doses as high as 3,200 mg/day has not been found to be toxic, but adverse effects have been reported with extended intake of 1,100–2,100 mg/day of  $\alpha$ -tocopherol [11, 43]. Reported adverse effects include increased risk of bleeding, diarrhea, abdominal pain, fatigue, reduced immunity, and transiently raised blood pressure. Some research suggests that very high doses may be pro-oxidant (i.e., acting as free radicals), especially in smokers [45, 46].

### 1.12.2.5 Interactions with Other Nutrients and Drugs

Vitamin E exerts antioxidant effects in combination with other antioxidants, including  $\beta$ -carotene, vitamin C, and selenium. Vitamin C can restore vitamin E to its natural reduced form. Vitamin E is necessary for the action of vitamin A and may protect against some of the adverse effects of excessive vitamin A. Because inorganic iron destroys vitamin E, the two should not be taken simultaneously. Cholestyramine, mineral oil, and alcohol may reduce the absorption of vitamin E [44].

Based on the results of a single case report, there has been concern that coadministration

of vitamin E with anticoagulants (e.g., warfarin) may enhance their effects [44, 47]. However, a randomized clinical trial that investigated the effects of vitamin E administration in patients on long-term warfarin therapy found no significant change, and the researchers concluded that vitamin E may safely be given to patients receiving warfarin [48, 49].

## 1.12.3 Carotenoids

Carotenoids (also referred to as carotenes) are a group of more than 600 highly colored plant compounds; however, only 14 have been identified in human blood and tissue [50]. The most prevalent carotenoids in North American diets include  $\alpha$ -carotene,  $\beta$ -carotene, lycopene, lutein, zeaxanthin, and  $\beta$ -cryptoxanthin. Only three ( $\alpha$ -carotene,  $\beta$ -carotene, and  $\beta$ -cryptoxanthin) are converted to vitamin A and are considered pro-vitamin A carotenoids [11].

### 1.12.3.1 Role in the Body and Consequences of Deficiency

The only specific effect of carotenoids in humans is to act as a source of vitamin A in the diet, but they also have important antioxidant actions. The latter are based on the carotenoids' ability to quench singlet oxygen and trap peroxyl radicals, thereby preventing lipid peroxidation [50]. As a result, carotenoids protect against the development of cancer, CVD, and ocular disorders. Carotenoids also affect cell growth regulation and gene expression. Diets low in carotenoids may lead to increased risk of cancer and heart disease. Lycopene is the most potent antioxidant for quenching single oxygen and scavenging free radicals [51].

Isotretinoin currently is approved for the treatment of nodulocystic acne, and there have been reported benefits in using 10–20 mg three times a week for 2 months for the treatment of cutaneous aging [59].



### 1.12.3.2 Recommended Daily Allowance

Currently, there are no DRIs for carotene intake, as it is believed that the current state of research on these nutrients is not strong and consistent enough to support any recommendations. An intake of  $\beta$ -carotene 6 mg is needed to meet the vitamin A RDA of 1,000 mcg retinol equivalents (RE) [44]; RE is a measurement of vitamin A intake that allows for comparison of different forms of the vitamin. One IU of vitamin A is equivalent to  $\beta$ -carotene 0.6 mcg [60]. Due to insufficient data demonstrating a threshold above which adverse events will occur, no UL has been set for any carotenoid [6].

### 1.12.3.3 Food Sources

Primary sources of  $\beta$ -carotene include carrots, sweet potatoes, pumpkin, cantaloupe, pink grapefruit, spinach, apricots, broccoli, and most dark green leafy vegetables;  $\beta$ -carotene is not destroyed by cooking. Lycopene is abundant in tomatoes, carrots, green peppers, and apricots. Lycopene is concentrated by food processing and therefore may be found in high concentrations in foods such as processed tomato products (e.g., spaghetti sauce and tomato paste). Lutein is found in green plants, corn, potatoes, spinach, carrots, and tomatoes, and zeaxanthin is found in spinach, paprika, corn, and fruits.

### 1.12.3.4 Risks with High Doses

Carotenoids are believed to be safe at fairly high doses. Some areas of skin may become orange or yellow in color (carotenoderma) if high doses of  $\beta$ -carotene (30 mg/day or greater) are taken for long periods but will return to normal when intake is reduced [6]. This effect can be used therapeutically in clinical practice to treat patients with erythropoietic photoporphyria (a photosensitivity disorder). Such patients have been treated with doses of approximately 180 mg/day without reports of toxic effects [6]. Carotenes have enhanced bioavailabil-

ity and have been associated with an increased risk of lung cancer in smokers.

Interactions with other nutrients: Carotenoids require bile acids in order to be absorbed. Conversion of carotenoids to vitamin A requires protein, thyroid hormone, zinc, and vitamin C.

## 1.12.4 Selenium

### 1.12.4.1 Role in the Body and Consequences of Deficiency

The most important antioxidant mineral is selenium. Selenium is essential for the function of the antioxidant enzyme glutathione peroxidase, and it is also important for healthy immune and cardiovascular systems. Selenium's anti-inflammatory properties have been demonstrated by its ability to inhibit skin-damaging, UV-induced inflammatory cytokines [61]. Results from a Nutritional Prevention of Cancer trial conducted among individuals at high risk of nonmelanoma skin cancer demonstrated that selenium supplementation is ineffective at preventing skin cancer and basal cell carcinoma and that it probably increases the risk of squamous cell carcinoma and total nonmelanoma skin cancer.

### 1.12.4.2 Recommended Daily Allowance

The RDA of selenium for men and women is 55 mcg/day, and the UL is 400 mcg/day.

### 1.12.4.3 Food Sources

Dietary intakes depend on the content of the soil where plants are grown or where animals are raised. Good sources of selenium include organ meats and seafood. Because plants do not require selenium, concentrations of this antioxidant in plants vary greatly, and food tables that list average selenium content are unreliable for

1

plant foods. In the United States and Canada, the food distribution system ensures that regions with low selenium concentrations in the soil do not have low selenium dietary intakes [6].

#### 1.12.4.4 Risks with High Doses

The UL for selenium is 400 mcg/day; toxicity is noted at mean doses greater than 800 mcg/day, with a 95% confidence limit of 600 mcg/day [62]. Doses above this range result in early symptoms of selenosis, including fatigue, irritability, and dry hair [6, 63, 64]. More advanced symptoms include dental caries, hair loss, loss of skin pigmentation, abnormal nails, vomiting, nervous system problems, and bad breath [63].

#### 1.12.4.5 Interactions with Other Nutrients

The combination of selenium and vitamin E seems to have synergistic effects for the treatment of heart disease, ischemia, and cancer. Vitamin C may also produce synergistic effects, but large doses of vitamin C may result in decreased absorption [65].

### 1.13 Glycemic Index

Overeating carbohydrate foods can prevent a higher percentage of fats from being used for energy and lead to a decrease in endurance and an increase in fat storage due to insulin. High insulin levels suppress two important hormones: glucagon and GH. The best solution to utilize more fats is to moderate the insulin response by limiting the intake of refined sugar and keeping all other carbohydrate intake to about 40% of the diet. The glycemic index (GI) is a measure of how much insulin increases after eating carbohydrates. High GI foods include sugar and sugar-containing foods, bagels, breads and potatoes, cereals, and other foods containing sugar maltose, as well as oatmeal, bran muffins, pasta, and bananas. Carbohy-

drates with a lower GI index include pears, natural yogurt, lentils, grapefruit, peanuts, and fructose.

### 1.14 Final Remarks

When approaching the patient with aging skin, the aim is not to make the skin simply appear smoother or less wrinkled but to make the entire body and mind appear or feel younger.

### References

- Perez G, Tilly J (1997) Cumulus cells are required for the increased apoptotic potential in oocytes of aged mice. *Hum Reprod* 12:2781–2783
- Ashcroft G, Horan MA, Ferguson MW (1997) The effect of aging on wound healing: Immunolocalization of growth factors and their receptors in a murine incisional model. *J Anat* 190:351–365
- Banks D, Fossel M (1997) Telomeres, cancer, and aging. Altering the human life span. *JAMA* 278:1345–1348
- Sun Y (1990) Free radicals, antioxidant enzymes, and carcinogenesis. *Free Radic Biol Med* 8:583–599
- Winkler BS, Boulton ME, Gottsch JD, Sternberg P (1999) Oxidative damage and age-related macular degeneration. *Mole Vis* 5:32
- Institute of Medicine (2000) Dietary reference intakes for vitamin C, vitamin E, selenium, and carotenoids. National Academy Press, Washington, DC
- Christen S, Woodall A, Shigenaga MK et al (1997) Gamma-tocopherol traps mutagenic electrophiles such as NOx and complements alpha-tocopherol: physiologic implications. *Proc Natl Acad Sci* 94:3217–3222
- Yaar M, Gilchrist BA. Aging skin (1999) In: Freedberg IM, Eisen AZ, Wo HK, et al (eds) *Dermatology in general medicine*, 5th edn. McGraw-Hill, New York pp 1679–1706
- Gilchrist BA, Chiu N (2000) Aging and the skin, In: Beers MH, Berkow R (eds) *The Merck manual of geriatrics*. Merck, Whitehouse Station
- Pincus S, Mulligan T, Iranmanesh A, Gheorghiu S, Godschalk M, Veldhuis J (1996) Older males secrete luteinizing hormone and testosterone more irregularly, and jointly more asynchronously, than younger males. *Proc Natl Acad Sci USA* 93:14100–14105
- Scheiber M, Rebar R (1999) Isoflavones and postmenopausal bone health: a viable alternative to estrogen therapy? *Menopause* 6:233–241
- Cook MJ (1993) Perimenopause: an opportunity for health promotion, *J Obstet Gynecol Neonatal Nurse* 22(3):223–228

13. Lavker RM (1979) Structural alterations in exposed and unexposed aged skin. *J Invest Dermatol* 73(1): 59–66
14. Yaar M, Gilchrist BA (1999) Aging skin. In: Freedberg IM, Eisen AZ, Wo HK, et al (eds) *Dermatology in general medicine*, 5th edn. McGraw-Hill, New York 1697–1705
15. Wang C, Iranmanesh A, Berman N et al (1998) Comparative pharmacokinetics of three doses of percutaneous dihydrotestosterone gel in healthy elderly men – a clinical research center study. *J Clin Endocrinol Metab* 83: 2749–2757
16. Morley J, Perry HM (1999) Androgen deficiency in aging men. *Med Clin North Am* 83: 1279–1289
17. Snyder P, Peachey H, Hannoush P et al (1999) Effect of testosterone treatment on body composition and muscle strength in men over 65 years of age. *J Clin Endocrinol Metab* 84: 2647–2653
18. Bhasin S, Bagatell C, Bremner W et al (1998) Issues in testosterone replacement in older men. *J Clin Endocrinol Metab* 83: 3435–3448
19. Wideman L, Weltman J, Shah N, Story S, Veldhuis J, Weltman A (1999) Effects of gender on exercise-induced growth hormone release. *J Appl Physiol* 87: 1154–1162
20. Veldhuis J, Evans W, Shah N, Storey S, Bray M, Anderson S (1999) Proposed mechanisms of sex-steroid hormone neuromodulation of the human GH-IGF-I axis. In: Veldhuis J, Giustina A (eds) *Sex steroid interactions with growth hormone*. Springer-Verlag, Berlin Heidelberg New York 93–121
21. Accili D, Drago J, Lee E et al (1996) Early neonatal death in mice homozygous for a null allele of the insulin receptor gene. *Nat Genet* 12: 106–109
22. Donofrio LM (2000) Fat distribution: a morphologic study of the aging face. *Dermatol Surg* 26: 1107–1112
23. Abribat T et al (1994) Alteration of growth hormone secretion in aging: peripheral effects.” In: Bbercu BB, Walker RF (eds) *Growth hormone 2, basic and clinical aspects*. Springer-Verlag, Berlin Heidelberg New York
24. Reutens AT, Veldhuis JD, Hoffman DM et al (1996) A highly sensitive GH ELISA uncovers increased contribution of a tonic mode of GH secretion in adults with organic GH deficiency. *J Clin Endocrinol Metab* 81: 1591–1597
25. Shalet SM, Toogood A, Rahim A, Brennan BMD (1998) The diagnosis of GH deficiency in children and adults. *Endocr Rev* 19: 203–223
26. Growth Hormone Research Society (1998) Consensus guidelines for the diagnosis and treatment of adults with GH deficiency: Summary statement of the Growth Hormone Research Society Workshop on Adult Growth Hormone Deficiency. *J Clin Endocrinol Metab* 83: 379–381
27. Toogood AA, Nass RM, Pezzoli SS et al (1997) Preservation of GH pulsatility despite pituitary pathology, surgery, and irradiation. *J Clin Endocrinol Metab* 82: 2215–2221
28. Bengtsson BA, Johannsson G, Shalet SM, Simpson H, Sonken PH (2000) Treatment of growth hormone deficiency in adults. *J Clin Endocrinol Metab* 85: 933–942
29. Drake WM, Howell SJ, Monson JP, Shalet SM (2001) Optimizing GH therapy in adults and children. *Endocr Rev* 22: 425–450
30. Gibney J, Wallace JD, Spinks T et al (1999) The effects of 1 year of recombinant human growth hormone (GH) in adult GH-deficient patients. *J Clin Endocrinol Metab* 84: 2596–2602
31. Ezzat S, Fear S, Gaillard RC et al (2002) Gender-specific responses of lean body composition and non-gender-specific cardiac function improvement alter GH replacement in GH-deficient adults. *J Clin Endocrinol Metab* 87: 2725–2733
32. Cummings D, Merriam GR (1999) Growth hormone and growth hormone secretagogues in adults. In: Meikie AW (ed) *Contemporary endocrinology: hormone replacement therapy*. Humana, Totowa 61–88
33. Hernberg-Stahl E, Luger A, Abs R et al (2001) Healthcare consumption decreases in parallel with improvements in quality of life during GH replacement in hypopituitary adults with GH deficiency. *J Clin Endocrinol Metab* 86: 5277–5281
34. Growth Hormone Research Society (1998) Consensus guidelines for the diagnosis and treatment of adults with GH deficiency: Summary statement of the Growth Hormone Research Society Workshop on Adult Growth Hormone Deficiency. *J Clin Endocrinology Metab* 83: 379–381
35. Mericq V, Cassorla F, Garcia H et al (1995) Growth hormone (GH) responses to GH-releasing peptide and to GH-releasing hormone in GH-deficient children. *J Clin Endocrinol Metab* 80: 1681–1684
36. Harris MI (1990) Epidemiology of diabetes mellitus among the elderly in the United States. *Clin Geriatr Med* 6: 703–719
37. Lamberts SWJ, Van den Beld AW, Van der Lely AJ (1997) The endocrinology of aging. *Science* 278: 419–424
38. Ezzat S, Melmed S (1991) Clinical review 18: Are patients with acromegaly at increased risk for neoplasia? *J Clin Endocrinol Metab* 72: 245–249
39. Brunner JE, Johnson CC, Zafar S et al (1990) Colon cancer and polyps in acromegaly: Increased risk associated with family history of colon cancer. *Clin Endocrinol* 32: 65–71
40. Hankinson SE, Willett WC, Colditz GA et al (1998) Circulating concentrations of IGF-1 and risk of breast cancer. *Lancet* 351: 1393–1396
41. Takala J, Ruokonen E, Webster NR et al (1999) Increased mortality associated with GH treatment in critically ill adults. *N Engl J Med* 341: 785–792
42. Institute of Medicine (2000) *Dietary reference intakes for vitamin C, vitamin E, selenium, and carotenoids*. National Academy Press, Washington, DC
43. Block G (1991) Vitamin C and cancer prevention: the epidemiologic evidence. *Am J Clin Nutr* 53: 270S–282S



44. Kwiterovich PO Jr (1997) The effect of dietary fat, antioxidants, and pro-oxidants on blood lipids, lipoproteins, and atherosclerosis. *J Am Diet Assoc* (-Suppl 7) 97:531-541
45. Adams AK, Wermuth EO, McBride PE (1998) Antioxidant vitamins and the prevention of coronary heart disease. *Am Fam Physician* 60:895-904
46. Simon JA, Hudes ES, Browner WS (1998) Serum ascorbic acid and cardiovascular disease prevalence in US adults. *Epidemiology* 9:316-321
47. Richard MJ, Roussel AM (1999) Micronutrients and aging: intakes and requirements. *Proc Nutr Soc* 58:573-578
48. Pandey DK, Shekelle R, Selwyn BJ et al (1995) Dietary vitamin C and beta-carotene and risk of death in middle-aged men. The Western Electric Study. *Am J Epidemiol* 142:1269-1278
49. Loria CM, Klag MJ, Caulfield LE, Whelton PK (2000) Vitamin C status and mortality in US adults. *Am J Clin Nutr* 72:139-145
50. Sahyoun NR, Jacques PF, Russell RM (1996) Carotenoids, vitamins C and E, and mortality in an elderly population. *Am J Epidemiol* 144:501-511
51. Ness AR, Khaw KT, Bingham S, Day NE (1996) Vitamin C status and blood pressure. *J Hypertens* 14:503-508
52. Johnston CS, Thompson LL (1998) Vitamin C status of an outpatient population. *J Am Coll Nutr* 17:366-370
53. Mares-Perlman JA, Brady WE, Klein BE et al (1995) Diet and nuclear lens opacities. *Am J Epidemiol* 141:322-334
54. Levine M, Rumsey SC, Daruwala R et al (1999) Criteria and recommendations for vitamin C intake. *JAMA* 281:1415-1423
55. Meyers DG, Maloley PA, Weeks D (1996) Safety of antioxidant vitamins. *Arch Intern Med* 156:925-935
56. Auer BL, Auer D, Rodgers AL (1998) Relative hemoxaluria, crystalluria and hematuria after megadose ingestion of vitamin C. *Eur J Clin Invest* 28:695-700
57. Loudon GM (1988) *Organic chemistry*. Benjamin/Cummings, Menlo Park
58. Bulger EM, Helton WS (1998) Nutrient antioxidants in gastrointestinal diseases. *Gastroenterol Clin North Am* 27:403-419
59. Hernandez-Perez E, Khawaja HA, Alvarez TYM (2000) Oral isotretinoin as part of the treatment of cutaneous aging, San Salvador, El Salvador. *Dermatol Surg* 26:7
60. Goodman DS, Goodman DS (1984) Vitamin A and retinoids in health and disease. *N Engl J Med* 310:1023-1031
61. Greul AK et al (2002) Photoprotection of UV-irradiated human skin: an antioxidative combination of vitamins E and C, carotenoids, selenium and proanthocyanidins. *Skin Pharmacol Appl Skin Physiol* 15(5):307-315
62. Yang G, Zhou R (1994) Further observations on the human maximum safe dietary selenium intake in a seleniferous area of China. *J Trace Elem Electrolytes Health Dis* 8:159-165
63. Yang GQ, Wang SZ, Zhou RH, Sun SZ (1983) Endemic selenium intoxication of humans in China. *Am J Clin Nutr* 37:872-881
64. Yang GQ, Xia YM (1955) Studies on human dietary requirements and safe range of dietary intakes of selenium in China and their replication in the prevention of related endemic diseases. *Biomed Environ Sci* 8:187-201
65. Reavley N (1998) *The new encyclopedia of vitamins, minerals, supplements, and herbs*. M. Evans, New York

# Anti-Aging Skin Care Ingredient Technologies

Jeannette Graf

## Core Messages

- The impact of bioactive skin care ingredient technology, pharmaceutical methods, and drug delivery systems have resulted in the development of cosmeceuticals and the advancement of cosmeceuticals™ in anti-aging skin care ingredient technology.
- Anti-aging skin care ingredients are assessed: antioxidants, hydroxy acids, beta glucans, minerals, peptides, and growth factors.
- Topical antioxidants have both protective and rejuvenation benefits. Currently under research and development are spin traps (phenyl butyl nitrene).

2.5	Vitamin A–Retinoids . . . . .	22
2.6	B Vitamins . . . . .	23
2.7	Alpha-Hydroxy Acids (AHAs) . . . . .	23
2.8	Polyhydroxy Acids (PHAs) . . . . .	24
2.9	Beta-Hydroxy Acids (BHAs) . . . . .	24
2.10	Beta-Glucan . . . . .	24
2.11	Skin Respiratory Factors . . . . .	24
2.12	Copper . . . . .	25
2.13	Peptides . . . . .	25
2.14	Conclusion . . . . .	26
	References . . . . .	26

## 2.1 Introduction

The past decade has witnessed the progression of the field of cosmeceuticals moving toward one of cosmeceuticals™. The impact of advanced technologies as well as pharmaceutical methods and drug delivery systems has resulted in the field of cosmetic dermatology. This chapter will attempt to give the practitioner a base of current knowledge in the field of cosmetic dermatology. The skin care consumer has been faced with a literal flood of products into the marketplace designed to address various cosmetic concerns. As research and development of new bioactive ingredients and knowledge of existing ingredients continue to grow, and new technologies reflect increased stability and delivery of these ingredients to the skin, this trend will only continue to grow.

## Contents

2.1	Introduction . . . . .	17
2.2	Reassessing the Skin Care Regimen . . . . .	18
2.3	Aging Skin . . . . .	18
2.4	Antioxidants . . . . .	19
2.4.1	Spin Traps–Phenyl Butyl Nitrene . . . . .	19
2.4.2	Vitamin E . . . . .	19
2.4.3	Vitamin C . . . . .	20
2.4.4	Coenzyme Q10 . . . . .	21
2.4.5	Idebenone . . . . .	21
2.4.6	Lipoic Acid . . . . .	21
2.4.7	Polyphenols . . . . .	21
2.4.8	Selenium . . . . .	22
2.4.9	Carotenoids . . . . .	22

## 2.2 Reassessing the Skin Care Regimen

2

The cosmetic and beauty industry is one of the world's oldest professions, dating as far back as 1000 B.C. to the Picts, a tribe in Scotland. The use of ointments and oils was recorded on papyrus by the Ancient Egyptians, and cold cream is said to have been invented by the ancient Greek physician Galen. The quest for beautiful skin will bring many patients seeking expert advice to the dermatologist's office. The aim of this section is to try and simplify a topic that is constantly changing. Technologic advances of the past several decades have provided a great deal of information about skin structure and function as well as cellular and molecular mechanisms of aging.

The skin's appearance is dependent on many factors, including brightness and the way it reflects light. Healthy looking skin and how it reflects light is as important to younger-looking skin as is diminishing wrinkles. Lack of proper skin care can accelerate the aging process. It is therefore worthwhile to include a review of basic skin care, which comes down to cleansing and moisturizing.

The stratum corneum (SC) is a highly specialized structure whose brick and mortar composition is made up of terminally differentiated corneocytes (brick) intertwined within a specialized lipid matrix (mortar), which forms the skin's protective moisture barrier [1]. The SC is made up of dead corneocytes that are formed following apoptosis or planned death of migrating keratinocytes. The ability of the SC to retain moisture is through a variety of small-molecular-weight compounds collectively called the natural moisturizing factor (NMF) [2, 3]. The NMF functions as a humectant and consists of many compounds, including lactic acid, urea, and amino acids, which are breakdown products of filaggrin and cis-urocanic acid whose role is not clear but is believed to have a free-radical-scavenging role [4, 5]. The highest levels of NMF are found in the lowest regions of the SC where the greatest amount of moisture is retained.

The lipid matrix of the SC is made up of bipolar lipids in alternating hydrophilic and hydrophobic rows. The lipids consist of fatty acids, ceramides, and cholesterol, which form the SC mortar by surrounding the NMF thereby preventing moisture loss known as TEWL (transepidermal moisture loss.) Without this lipid bilayer, the hydrophilic NMF would evaporate and the resultant TEWL would clinically result in dry and aged-looking skin.

Cleansing is necessary in order to remove environmental dirt, microorganisms, makeup, and metabolic byproducts that can otherwise be damaging to the skin. Finding a cleanser appropriate for skin type that will not harm the moisture barrier while ensuring that a moisturizer is used to replenish and protect the moisture barrier is as important as any anti-aging ingredient.

## 2.3 Aging Skin

How skin ages depends on a number of factors. The primary factor that determines the way a person ages is underlying genetics. Other internal influences include diet, lifestyle, drug, and alcohol history. Smoking, a cause of premature aging of the skin, has been directly linked with elevations in matrix metalloproteinase-1 (MMP-1), which is a zinc-dependent protease responsible for degradation of dermal collagen [6]. Environmental exposures, including weather changes and pollutants, have a direct impact on skin aging, with the most profound degradative changes caused by chronic UV exposure with resultant photoaging.

Chronically aged skin that loses the scaffolding of the dermal structural proteins elastin and collagen in addition to epidermal thinning appears loose and wrinkled. There is atrophy of adnexal structures with a decrease of oil-secreting glands and the skin's moisture retaining ability, resulting in dryness and scaling. Continued loss of elasticity results in sagging, jowliness, and deep furrows. Photoaging compounds the structural changes by accelerating aging with even more pronounced wrinkling. There are more epidermal changes with pig-

mentary alterations of mottling and wrinkling than seen in chronologically aged skin alone.

The question of how and why we age has been the subject of much thought and discussion. As we learn more about aging and cell-signaling pathways, the approach to aging evolves. If humans are built with internal repair mechanisms, why do we age with degenerative changes? Many scientists are now starting to view physical aging as a disease process. The cellular and molecular mechanisms involved in aging reveal an intricate series of signals, markers, and pathways, all of which are programmed to monitor and control the lifespan of a cell as it ages. By studying these molecular events and pathways, the field of anti-aging will be furthered by the use of cosmeceuticals™.

## 2.4 Antioxidants

The use of antioxidants in any anti-aging skin care regimen is essential in order to combat and prevent further damage. Vitamins have been used to combat free radical damage for many years. Unfortunately, they get used up rather quickly since it takes one vitamin to neutralize one free radical. Enzymes are more efficient free radical scavengers; however, they depend on the presence of a healthy cellular environment and certain trace minerals to synthesize them. There is growing evidence of the synergy that exists in using combinations of antioxidants along with sunscreens. Some antioxidants have protective benefits while others work as protectants in addition to stimulating age-reversal changes.

### 2.4.1 Spin Traps—Phenyl Butyl Nitron

We are familiar with free radical damage that occurs with oxidative stress by sun, environmental pollutants, and cigarette smoking. However, free radicals are formed as result of normal oxygen metabolism and therefore are a byproduct of normal physiologic function. Damaging free radicals are created when an aberrant electron “spins” out of its orbit leaving a

highly unstable molecule. The very newest antioxidants, which are known as “spin traps,” have the ability to catch or trap the aberrant electron as it starts to spin out of control and return it to its orbit before it can do any damage. Although the use of spin traps in dermatology is in its infancy, these compounds show a great deal of promise.

Spin traps were originally used as a way to measure free radical activity both in vivo and in vitro through their ability to form stable complexes [7, 8]. Their uses in degenerative diseases associated with aging have been a subject of study due to their ability to trap and neutralize free radicals. The most well-known spin trap is phenyl butyl nitron (PBN) [9]. Numerous studies by Dr. J. Carney and his associates have been performed that have demonstrated the anti-inflammatory, neuroprotective, age-reversing effects of PBN. Interestingly, it is not so much their capacity to neutralize free radicals that is responsible for the protective behavior of spin traps but, rather, their ability to modulate proinflammatory cytokines [10].

### 2.4.2 Vitamin E

Topically applied vitamin E plays an enormous role in protecting the skin from free radical damage. Vitamin E is the most abundant antioxidant found in skin, and it is produced in human sebaceous glands in its alpha- and gamma-tocopherol forms. These tocopherols are part of a natural protective mantle that has been described and is, in fact, the first line of protection against environmental stress. As the vitamin E levels of the skin diminish, the production of alpha- and gamma-tocopherols occurs in the sebaceous glands and is delivered to the skin's surface via sebum [11]. Oxidative damage occurs when the rate of depletion of vitamin E exceeds the rate of production. The important role of sebaceous glands and sebum in the production and delivery of vitamin E to the skin may explain the often-made observation that oily skin tends to age more slowly than drier skin. Perhaps those with oily skin have a higher vitamin E level and therefore more natural protection than those with dry skin.

2 The very properties that make alpha-tocopherol such a powerful antioxidant causes it to break down in the presence of oxygen or upon exposure to light. For that reason, alpha-tocopherol acetate, which is the more stable esterified form, is used in cosmetics. Since alpha-tocopherol acetate is not an antioxidant and has no antioxidant activity, it must first convert to its active alpha-tocopherol form. Years of debate questioned the ability of alpha-tocopherol acetate to be delivered to the skin and bioconverted to an active form. Finally, in 1990, the bioconversion of alpha-tocopherol acetate to free alpha-tocopherol was able to be demonstrated [12]. In addition, formulation enhancement using certain delivery systems has demonstrated the ability to deliver significant levels to the skin followed by bioconversion once in the skin.

The use of vitamin E in skin care has anti-aging benefits based on its moisturization properties but mostly on its protective capabilities. Dr. Lester Packer documented the depletion of vitamin E levels in skin following UV radiation [13]. In addition, he was able to document significantly higher levels in the skin following the application of a cream containing 5% tocopherol acetate over 10 days. He also demonstrated the antioxidant role of vitamin E against the oxidative stress caused by ozone [14, 15].

The protective role of vitamin E extends to skin care preparations by enhancing their stability and shelf life. A change in color or texture is a sure sign that a cosmetic product is oxidizing and should not be used. Patients ought to be told that the breakdown of the product will continue as it is applied to their skin. When cosmetic products contain ingredients that are easily oxidized, such as vitamins or natural extracts, the use of alpha-tocopherol in conjunction with ascorbyl palmitate acts as a powerful antioxidant system preventing oxidation. In addition, the combination of alpha-tocopherol and ascorbyl palmitate can prevent the formation of carcinogenic nitrosamines [16].

The enhanced ability of vitamin E as a moisturizer with its added benefits of skin smoothness and softness is attributed partly to its ability to penetrate the skin and provide cumulative benefits [16]. Vitamin E enhances the pho-

toprotective effects of sunscreen, and when combined with vitamin C, the two are even stronger as photoprotectants [17, 18].

### 2.4.3 Vitamin C

Vitamin C is a major water soluble antioxidant that plays a vital role in photoprotection as well as in collagen synthesis. The body reservoir of vitamin C decreases with age, and habits such as smoking decrease reserves even more. Vitamin C is not produced in the body and must be consumed entirely through diet and oral supplementation. Likewise, in the skin where vitamin C plays a vital role in photoprotection and aging, it must be topically supplemented since, unlike vitamin E, it is not produced in the skin.

The role of vitamin C in photoprotection has been demonstrated by the dramatic reduction of vitamin C in skin following UV radiation. In addition, a combination of both vitamins E and C work synergistically to enhance their photoprotective effects. This reinforces the benefit derived from enhancing photoprotection by combining antioxidants with sun-protection products [17, 18].

Vitamin C is an essential cofactor for the hydroxylation of proline and lysine, a necessary step in collagen synthesis. In fact, fibroblasts in cell culture will selectively secrete collagen when vitamin C is added in a dose-dependent fashion. Its role in collagen synthesis is probably responsible for the wrinkle-reducing and skin-firming effects that vitamin C has on aged skin [19, 20, 21]. Vitamin C also appears to reduce signs of photoaging. In addition, topical vitamin C increases levels of tissue inhibitors of collagen-degrading matrix metalloproteinase1 (MMP-1) [22].

The ability of topical vitamin C to reduce hyperpigmentation has been demonstrated and has found its way into various skin-lightening products. Vitamin C is able to lighten hyperpigmented skin through the inhibition of the enzyme tyrosinase [23].

Many forms of vitamin C have been used in various topical formulations in efforts to stabilize this highly unstable molecule. However, any form of vitamin C that is applied to the skin

must convert to the L-ascorbic acid form in order to be recognized by the body and deliver a benefit. Stabilizing vitamin C was an impossibility until 1988 when Dr. Sheldon Pinnell from Duke University, one of the pioneers of topical vitamin C research, was able to stabilize ascorbic acid in solution. The same study also showed the presence of ascorbic acid in the skin days after the application with an increase in the level of collagen as well, proving the penetration and benefit of the topically applied vitamin C [24, 25].

There are so many different vitamin C variations used in skin care that rather than naming each one, the process can be simplified by dividing them in either water soluble (L-ascorbic acid and magnesium or sodium ascorbyl phosphate), fat-soluble esters (ascorbyl palmitate, ascorbyl tetra-isopalmitate), or anhydrous systems. Unfortunately, the long-term stability of topical vitamin C preparations remains a concern. The most stable vitamin C preparations remain anhydrous or completely water free.

#### 2.4.4 Coenzyme Q10

Coenzyme Q<sub>10</sub> (CoQ<sub>10</sub>) is a powerful free radical inhibitor that inhibits lipid peroxides from forming in plasma membranes. CoQ<sub>10</sub> plays a very important role in cellular energy production and works in the mitochondrial adenosine triphosphate (ATP) energy-producing pathway of the cell [26]. The presence of CoQ<sub>10</sub> in the mitochondria may play a role in preventing oxidative stress induced cellular apoptosis since it is in the mitochondria where the final apoptotic signal is dispatched.

As we age, CoQ<sub>10</sub> levels diminish, as does cellular energy production, which may improve by adding CoQ<sub>10</sub>. The vast majority of information about CoQ<sub>10</sub> is based on its oral use. Topically, it has demonstrated antioxidant activity as well as inhibition of collagenase expression in UV-irradiated human fibroblasts. Topical application of CoQ<sub>10</sub> has been reported to show a reduction in wrinkles; however, more studies need to be done.

#### 2.4.5 Idebenone

Idebenone is a powerful synthetic analog of CoQ<sub>10</sub>, which shows a great deal of promise. In a study comparing the photoprotective properties of topical idebenone to those of vitamin E, kinetin, CoQ<sub>10</sub>, vitamin C, and lipoic acid, idebenone consistently demonstrated the highest level of antioxidation and photoprotection [27]. At the present time while this chapter is being written, idebenone is not yet available for topical use. However, it will soon be available under the brand name Prevage (Allergan, Irvine, CA, USA).

#### 2.4.6 Lipoic Acid

Lipoic acid is a very powerful antioxidant that has the unusual advantage of being both water and fat soluble and is an important cofactor in mitochondrial dehydrogenases. It has a great deal of anti-inflammatory activity, which is one of the reasons that Dr. Nicholas Perricone has credited lipoic acid as one of the major antioxidants in skin care. Studies have shown the ease with which lipoic acid is able to penetrate the skin, after which it converts into its active by-product dihydrolipoic acid (DHLA) [28, 29].

Topical application of 3% lipoic acid has demonstrated its ability to decrease UVB-induced erythema, which demonstrates its photoprotective and anti-inflammatory properties. Also, a 12-week study demonstrated that using a topical cream containing 5% alpha-lipoic acid was quite effective in treating signs of photoaging [30, 31].

#### 2.4.7 Polyphenols

Green tea polyphenols have been included in a growing number of skin care products for their antioxidant and anti-inflammatory effects [32]. These polyphenolic compounds are called epicatechins, and the most powerful member of this group is called epigallocatechin-3-gallate (EGCG). Studies have demonstrated the ability of EGCG pretreated skin to inhibit erythema,



myeloperoxidase activity, and inflammation following UVB irradiation [33, 34]. Studies have also demonstrated UV-radiated skin pretreated with green tea polyphenols shows a histologic decrease in sunburn cells [35, 36]. In addition, pretreated skin had less DNA damage as evidenced by fewer UV-induced DNA pyrimidine dimers formed than in untreated skin.

Another polyphenol that differs from those found in green tea are the procyanidins. Procyanidins are powerful free radical scavengers whose richest source is from the seeds of red grapes. Grapeseed extract is rich in polyphenols, and studies have reported it to have higher antioxidant activity than both vitamins C and E [37, 38]. In fact, in mice, grapeseed polyphenols have demonstrated greater inhibition of lipid peroxidation than green tea polyphenols [39]. The role of polyphenols, whether from green tea or grapeseed extract, has a great deal of potential as part of a growing natural anti-aging skin care market. With all natural ingredients, however, it is important to standardize extraction methods as well as assays for their activity.

### 2.4.8 Selenium

Selenium is an essential trace element with antioxidant, anti-inflammatory, and anticarcinogenic activities. As an anti-aging skin care ingredient, selenium's protective ability lies in its essential role as a cofactor in the formation of the important protective enzyme glutathione peroxidase [40]. Selenium's anti-inflammatory properties have been demonstrated by its ability to inhibit skin damaging UV-induced inflammatory cytokines [41]. Selenium as a topical ingredient does not penetrate skin well and must be used in its selenomethionine form in order to be bioavailable.

### 2.4.9 Carotenoids

Carotenoids are dietary antioxidants, which include lycopene, lutein, and beta-carotene. The sources of these natural free-radical-scavenging compounds include leafy green vegetables,

carrots, and tomatoes. Carotenoids have free-radical-scavenging properties and inhibit lipid peroxidation as well [42]. Most studies associated with carotenoids have used them in their oral form. However, there have been reports of the photoprotective effects by topically applied carotenoids [42]. In cell culture study on human skin fibroblasts, there was a decrease in the level of UVB-induced thiobarbituric acid-reactive substances by pretreatment with carotenoids. In the study, carotenoids were delivered to fibroblasts through liposomes 20 min prior to UV radiation, and measurements were taken 1 h later [42]. Although carotenoids work best synergistically, by themselves, lycopene was the strongest photoprotectant followed by lutein then beta-carotene [43].

Formulating with these compounds has been tricky since they are pigments and influence the color of the cosmetic in the jar as well as on the skin. However, newer technologies are being developed that are resulting in colorless carotenoids.

## 2.5 Vitamin A–Retinoids

The essential role of retinoids in the normal development and keratinization of skin dates back to 1925 when Wolbach and Howe described abnormal keratinization in vitamin-A-deficient enzymes. The topical use of retinoids has been more extensively studied than any other compound in dermatology. Retinoids play an important role in skin development and regulate the growth and differentiation of keratinocytes [44]. The ability of topical retinoids to reverse photoaging as well as chronologic aging makes the use of a retinoid a staple in any cosmetic regimen [45, 46].

Topical vitamin A has the ability to diminish the signs of aging by decreasing fine lines and wrinkling. In addition, there is a normalization and enhancement of elasticity [47]. Improvement of skin tone and texture is a benefit of vitamin A, which enhances skin lightening when used in conjunction with skin lighteners.

Vitamin A is a lipid-soluble molecule whose structure has been amenable to formulation

variability resulting in several structurally different forms. The first generation, or nonaromatic form, includes all-trans retinoic acid (tretinoin) and its 9-cis-isomer and 13-cis-isomer (isotretinoin) forms [44, 48]. The other topical forms are polyaromatic isomers of retinoic acid, or arotinoids, which include adapalene and tazarotene [49]. Retinoic acid regulates the growth, differentiation, and normalization of skin by recognizing and binding to specific retinoic acid receptors (RARs) and retinoic X receptors (RXRs), which are ligand-activated transcription factors. These receptors bind to regulatory regions of DNA where they activate gene transcription. Within each receptor family there exist subtypes and multiple isoforms belonging to each subtype.

Vitamin A derivatives used cosmetically in nonprescription products include retinol, retinaldehyde, retinyl palmitate, and retinyl esters. Retinol and retinaldehyde, an intermediate product in the conversion of retinol to all-trans retinoic acid, are natural forms of vitamin A [44]. The most common nonprescription forms used are retinol and retinyl palmitate. In order to be of any benefit, each must convert to the all-trans retinoic acid form in order to bind ligands. Retinol has been shown to penetrate the skin more effectively than retinaldehyde, retinyl palmitate, and even retinoic acid [50]. This was determined by measuring 4-hydroxylase activity, which is directly related to the level of all-trans retinoic acid in the skin [51]. Since each of the vitamin A derivatives must bioconvert to all-trans retinoic acid, the 4-hydroxylase level has become a marker of the bioavailability and effectiveness of these ingredients.

Retinol is the most abundant form of vitamin A in the skin; however, it is extremely sensitive to light and air during formulation in skin care. If retinol is not handled in the correct conditions, it will quickly oxidize, and an irritating, harmful product will result.

## 2.6 B Vitamins

Panthenol (provitamin B<sub>5</sub>) is the stable analog of pantothenic acid that has been used in skin care, nail products, and most especially in hair products through its enhanced moisturization benefits. Pantothenic acid enhances wound healing through cell proliferation and protein synthesis and quickly penetrates the skin. Known for its moisturizing and soothing effects, it can play a role in anti-aging skin care through its enhanced cell proliferation and healing abilities [52, 53].

Nicotinamide (niacinamide) is another B vitamin that has entered the skin care arena. Most studies of this vitamin have focused on the anti-inflammatory effects of nicotinamide and its benefit in acne treatment. The role of nicotinamide as a potential anti-aging ingredient has yet to be explored; however, one possible role is in the biosynthesis of ceramides and other stratum corneum lipids [54].

## 2.7 Alpha-Hydroxy Acids (AHAs)

About 25 years before glycolic acid made its dramatic entry into the cosmetic skin care market in the early 1990s, lactic acid had been described as part of the skin's NMF and was used with great success in skin moisturizers. In addition, Drs. Van Scott and Yu described the effectiveness of lactic acid in treating ichthyosis and disorders of keratinization. The combined use of topical retinoids as well as glycolic acid as an ingredient in cosmetic skin care products and in in-office peeling products has revolutionized the anti-aging skin care market [55].

The effects of alpha-hydroxy acids (AHAs) are determined by their pH and concentration levels. Although these naturally occurring organic acids are often referred to as fruit acids because they are found in many common fruits such as citrus fruits (citric acid), apples (malic acid), and grapes (tartaric acid), the two most widely used AHAs are not components of fruit. Glycolic acid is a sugar cane derivative, and lactic acid is derived from milk.



There have been a number of beauty benefits associated with the use of AHAs in facial skin care, and they have the ability to reduce the cohesion of dead corneocytes to the skin, giving the skin a smoother, less wrinkled, and less mottled appearance. It is ideal to couple these products with topical retinoids and lightening agents to enhance these effects. The effectiveness of AHAs in reversing the signs of aging were also coupled with problems of stinging, burning, and irritation, which were usually associated with a pH less than 3.5.

## 2.8 Polyhydroxy Acids (PHAs)

The polyhydroxy acids (PHAs) are the next generation of AHAs. They provide the anti-aging, skin-smoothing benefits of the AHAs without the potentially irritating side effects of burning and stinging. PHAs include gluconolactone and lactobionic acid, which are structurally larger molecules than AHAs allowing for slower skin penetration and thus fewer side effects [56, 57].

In addition to the exfoliative benefits of AHAs, PHAs provide additional benefits of enhanced stratum corneum barrier function and moisturization with humectant properties. This makes for enhanced skin compatibility and use for most skin types, including sensitive skins. PHAs are also protective since most of them contain antioxidant properties.

## 2.9 Beta-Hydroxy Acids (BHAs)

The most frequently used beta-hydroxy acid is salicylic acid. It is found in most over-the-counter (OTC) products and has been used primarily in the treatment of acne. Part of its effectiveness as an acne treatment may stem from its lipid solubility and ability to penetrate sebum [58]. More recently, salicylic acid has been used in the treatment of photoaging with in-office peels of 20–30%. These can be quite helpful in patients who are unable to tolerate alpha-hydroxy acids since irritancy levels tend to be less with salicylic acid. In addition, it can be quite useful to combine or alternate both AHAs and

BHAs since their mechanisms of action differ, and using both may be quite beneficial.

## 2.10 Beta-Glucan

Beta-glucans were first described in 1941 and belong to a class of compounds known as biological response modifiers. Although isolated from different sources, including oat, barley, and reishi mushrooms, the most biologically active are isolated from cell membranes of baker's yeast (*Saccharomyces cerevisiae*) [59]. The ability of Beta-glucans to stimulate and activate macrophages has resulted in multiple applications, including wound healing, infectious disease, oncology, and dermatology [60].

In the epidermis, where macrophage-derived cells include both keratinocytes and Langerhans cells, beta-glucans act to stimulate the protective qualities of these cells as our first line of defense. Topical beta-glucans can accelerate wound healing and increase resistance to infection by enhancing macrophage-mediated phagocytosis [61]. Studies have also demonstrated that beta-glucans have photoprotective properties similar to those of vitamin E by their ability to sustain levels of reduced glutathione in the skin following UV radiation [62]. Beta-glucans are extremely soothing and calming to the skin through their reinforcement of skin macrophages, which have implications in minimizing irritancy potential of products.

The potential uses of beta-glucans in dermatology are numerous. In personal-care products for shaving, where nicks and cuts, razor burn, irritation and folliculitis are problematic, the protective, wound-healing, anti-irritating effects of beta-glucans can be quite helpful. The photoprotective effects of beta-glucans as well as their ability to soothe, moisturize, and protect the skin from potential irritation that can occur with other treatment products, makes them quite useful in anti-aging skin regimens [63].

## 2.11 Skin Respiratory Factors

Skin respiratory factors (SRF), also called tissue respiratory factors (TRF), have been used in

cosmetics for their ability to renew and revitalize the skin. These ingredients revitalize cellular metabolism through the stimulation of cell respiration. The ability of an ingredient to stimulate cell respiration and cellular metabolism can be determined by Warburg assay, which measures oxygen uptake in living cell homogenates. As cell respiration and metabolism increase, cell energy increases, as evidenced by increased cellular ATP levels measured in the cell suspension [64].

Although a number of botanical ingredients with the ability to enhance cell respiration have been isolated, the most abundant source is baker's yeast [65]. However, unlike beta-glucans, which are isolated from the cell walls of baker's yeast, compounds that stimulate cellular respiration are extracted from the cytoplasm. These cytoplasmic elements generally contain mitochondrial components of the cell, which can enhance cellular energy [66].

As skin ages, it exhibits a certain amount of physiologic fatigue, which is compounded by oxidative stress and environmental factors. This fatigue, which increases with age, is paralleled by the progressive decrease in cellular energy and metabolism as well as diminished cellular function. The addition of ingredients to anti-aging skin care that contain mitochondrial cytoplasmic yeast extracts can result in the stimulation of cellular respiration followed by enhanced cellular metabolism, vitality, and increased cell renewal.

## 2.12 Copper

Products containing copper have gained increasing popularity in the anti-aging skin care market over the past several years. In humans, copper binds to the high-affinity tripeptide glycyl-L-histidyl-L-lysine (GHK) to form a copper-GHK complex [67]. This copper-GHK complex plays a vital role in human tissue repair, and its ability to accelerate wound healing has been demonstrated both *in vitro* and *in vivo*. In addition, copper is a vital cofactor in the activation of the powerful antioxidant enzyme superoxide dismutase [68, 69].

The ability of the copper-GHK complex to stimulate the production of both collagen and glycosaminoglycans in a dose-dependent fashion has been demonstrated in cell-culture studies of human fibroblasts. Other observations include the fact that the copper-GHK complex may also play a role in angiogenesis during wound healing. The role of copper-GHK as an anti-aging ingredient may be explained by its role in wound healing and its ability to stimulate extracellular matrix proteins.

A number of clinical studies have been performed using copper-GHK-containing products. Significant clinical improvements in photoaged skin were demonstrated in patients treated with facial and eye creams containing the copper-GHK complex [70, 71]. These improvements include a decrease in skin wrinkling, laxity, and roughness. These changes, as well as the lack of irritancy, give copper an important role in the anti-aging skin care market.

## 2.13 Peptides

Initially, peptides were derived from much larger molecules, which were enzymatically cleaved in order to isolate active fragments for use in skin care. Proteolytically cleaved peptides are still relatively large molecules. Advances in peptide chemistry were made with the advent of molecular biology. Molecular biology has enabled us to learn the exact amino acid sequences of molecules such as the matrix proteins type IV collagen and laminin. Knowing the amino acid sequence of these molecules enables the production of peptides that are five to ten amino acids in size.

The advantages of using tiny peptide fragments is in their specificity. In fact, much of the future of medicine including dermatology is in the use of peptides that will be able to stimulate or inhibit certain processes through receptor recognition. Currently, two of the most well-known peptides being used in skin care are palmitoyl pentapeptides, also known as Matrixyl; and acetyl hexapeptide-3, also known as Argireline.

Matrixyl is a pentapeptide that has been used as a procollagen analog to stimulate collagen production in skin. This procollagen pentapeptide sequence was first described in 1993 as being able to promote synthesis of types I and III collagen and fibronectin when added to fibroblast cell cultures [72]. The sequence Lys-Thr-Thr-Lys-Ser (KTTKS) has a fatty acid moiety called palmitoyl added to it in order to enhance its penetration in to the skin. Sederma (Le Perray en Yvelines, France), the company that holds the patents to pal-KTTKS (Matrixyl), sponsored a study that was presented as a poster at the 2002 World Congress of Dermatology in Paris, France. In this 4-month study, pal-KTTKS was able to decrease skin roughness by 27%, wrinkle volume by 36%, and wrinkle depth by 27%. Skin biopsies demonstrated increased density and thickness of elastin fibers in the dermis with improvement in type IV collagen. Studies performed by Sederma over 6 months using a cream containing 4% Matrixyl were impressive. Wrinkle depth decreased by 68% over 6 months, and wrinkle density decreased by 28%, 31%, and 47% over 2, 4, and 6 months, respectively. According to testing, in order to be effective at wrinkle reduction, Matrixyl must be used at a minimum concentration of 2% and ideally between 4 and 8%.

Argirelene has been marketed as having a relaxing effect on muscles and has therefore been touted as an alternative to Botox. Argirelene's mechanism of action has been studied in vitro and appears to inhibit vesicle docking by inhibiting formation of the soluble N-ethylmaleimide-sensitive fusion attachment protein receptor complex (SNAP) [73, 74]. By inhibiting SNAP formation, Argirelene inhibits the release of catecholamines, including epinephrine and norepinephrine, in vitro. Clinical studies are rather limited at this time, and penetration in vivo has yet to be determined. One study using Argirelene around the eye area found a 17% improvement in periorbital rhytides after 15 days and a 27% improvement after 30 days. According to studies from the company, Argirelene should be used at a 10% concentration for optimal results.

## 2.14 Conclusion

The field of anti-aging cosmetic ingredients has progressed from that of cosmeceuticals to cosmoleculars™. Much work still needs to be done, including developing assays in vitro that emulate actual chronologically aged skin. Thus far, all aged skin that is studied in cell culture is aged by UV irradiation, which is a photoaging model. In addition, when looking at collagen-promoting behaviors, fibroblast cell cultures do not emulate skin; skin is not in a state of active wound healing and fibroblast expansion under normal circumstances.

The use of growth factors in skin care, though sold in many products, is still quite early in its development. There is only one growth factor that is FDA approved for clinical use in wound healing, and that is platelet-derived growth factor (PDGF). It took approximately 35 years for the approval of PDGF, and yet many other growth factors are being used in skin care. Far more work needs to be done to prove they penetrate the skin as they are quite large. After proving skin penetration, safety must be of primary concern since there are multiple receptors that are up- and down-regulated. We do know what some of these receptors are; however, there are many more that remain unknown. Therefore, much more work needs to be done in this area.

As our knowledge and technology continue to grow, so will our use of peptide fragments and DNA oligopeptides. This is the cosmolecular™ connection of skin care still in its infancy but which points to an exciting future.

## References

1. Elias PM (1983) Epidermal lipids, barrier function and desquamation. *J Invest Dermatol* 80 (Suppl 1): 44-49
2. Jacobi O (1959) About the mechanism of moisture regulation in the horny layer of the skin. *Proc Scient Sect Toil Goods Assoc* 31: 22-26
3. Blank IH (1952) Factors which influence the water content of the SC. *J Invest Dermatol* 18: 430-433
4. Angelin JH (1976) Urocanic acid a natural sunscreen. *Cosmet Toil* 91: 47-49

5. Baden HP, Pathak MA (1967) The metabolism and function of urocanic acid in the skin. *J Invest Dermatol* 48: 11–17
6. Lahmann C et al (2001) Matrix metalloproteinase-1 and skin ageing in smokers. *Lancet* 24: 935–936
7. Floyd RA (2000) Nitron inhibition of age associated oxidative damage. *Ann NY Acad Sci* 899: 222–237
8. Floyd RA et al (2002) Nitrones, their value as therapeutics and probes to understanding aging. *Mech Ageing Dev* 123(8): 1021–1031
9. Carney and Floyd (1991) Protection against oxidative damage to CNS by alpha-phenyl-tert-butyl nitron (PBN) and other spin-trapping agents: A novel series of nonlipid free radical scavengers. *J Molec Neurosci* 3(1): 47–57
10. Pogrebniak HW (1992) Spin trap salvage from endotoxemia: the role of cytokine down-regulation. *Surgery* 112(2): 130–139
11. Jens J et al (1999) Sebaceous gland secretion is a major physiologic route of vitamin E delivery to skin. *J Invest Dermatol* 113: 1006–1010
12. Norkus, Edward P (1990) Bioconversion of vitamin E acetate to free tocopherol, New York Medical College
13. Packer Lester (1991) Protective effects of Vitamin E acetate against UVB/UVA radiation, University of California
14. Trevithick J R (1993) Reduction of sunburn damage to skin by topical application of vitamin E acetate, *Scanning Microsc* 7(4): 1269–1281
15. Thiele JJ et al (1997) Ozone-exposure depletes vitamin E and induces lipid peroxidation in murine stratum corneum. *J Invest Dermatol* 108: 753–757
16. Djerassi D (2001) The role of vitamins in high performance cosmetics. *Cosmetics and Toiletries Manufacturers Worldwide*
17. Darr D et al (1996). Effectiveness of antioxidants (vitamin C and E) with and without sunscreens as topical photoprotectants. *Acta Derm Venereol* 76: 264–268
18. Chan AC (1993) Partners in defense, vitamin E and vitamin C. *Can J Physiol Pharmacol* 71: 725–731.
19. Phillips CL et al (1992) Ascorbic acid and transforming growth factor- $\beta$ 1 increase collagen biosynthesis via different mechanisms: coordinate regulation of pro-alpha 1(I) and pro-alpha 1(III) collagens. *Arch Biochem Biophys* 295: 397–403.
20. Geesin JC et al (1988) Ascorbic acid specifically increases type I and type III procollagen messenger RNA levels in human skin fibroblast. *J Invest Dermatol* 90: 420–424.
21. Phillips CL et al (1994). Effects of ascorbic acid on proliferation and collagen synthesis in relation to the donor age of human dermal fibroblasts. *J Invest Dermatol* 103: 228–232.
22. Nussgens BV et al (2001) Topically applied vitamin C enhances the mRNA level of collagens I and III, their processing enzymes and tissue inhibitor of matrix metalloproteinase 1 in the human dermis. *J Invest Dermatol* 116: 853–859.
23. Takashima H et al (1971) Ascorbic acid esters and skin pigmentation. *Am Perfum Cosmet* 86: 29–36.
24. Pinnell SR (2001) Topical l-ascorbic acid: Percutaneous absorption studies. *Dermatol Surg* 27: 137–142
25. Pinnell, Sheldon R (1988) New stabilized ascorbic acid solution—percutaneous absorption and effect on relative collagen synthesis. *Journal of Cutaneous Aging & Cosmetic Dermatology* 1(2)
26. Hoppe U, et al (1999) Coenzyme Q<sub>10</sub>, a cutaneous antioxidant and energizer. *Biofactors* 9: 37
27. DiNardo J et al (2004) Antioxidants compared in a new protocol to measure protective capacity against oxidative stress—part II, American Academy of Dermatology, Washington D.C.
28. Moini H et al (2002) Antioxidant and prooxidant activities of alpha-lipoic acid and dihydrolipoic acid. *Toxicol Appl Pharmacol* 182(1)84–90
29. Podda M (2001) Activity of alpha-lipoic acid in the protection against oxidative stress in skin. *Curr Prol Dermatol* 29: 43–51
30. Rijnkels JM et al (2003) Photoprotection by antioxidants against UVB-radiation-induced damage in pig skin organ culture. *Radiat Res* 159(2): 210–217
31. Beitner H (2003) Randomized, placebo-controlled, double blind study on the clinical efficacy of a cream containing 5% alpha-lipoic acid related to photoageing of facial skin. *Br J Dermatol* 149(4): 841–849
32. Katiyar SK et al (2000) Green tea and skin. *Arch Dermatol* 136: 989–989
33. Katiyar SK et al (1999) Prevention of UVB-induced immunosuppression in mice by the green tea polyphenol (-)-epigallocatechin-3-gallate may be associated with alterations in IL-10 and IL-12 production. *Carcinogenesis* 20: 2117–2124
34. Zhao JF et al (1999) Green tea protects against psoralen plus UVA-induced photochemical damage to skin. *J Invest Dermatol* 113: 1070–1075
35. Katiyar SK, Elmets CA (2001) Green tea polyphenolic antioxidants and skin photoprotection. *Int J Oncol* 18: 1307–13013
36. Katiyar SK (2001) Green tea polyphenol (-)-epigallocatechin-3-gallate treatment to mouse skin prevents UVB-induced infiltration of leukocytes, depletion of antigen-presenting cells, and oxidative stress. *J Leukoc Biol* 69: 719–726
37. Bagchi D et al (2000) Free radicals and grape seed proanthocyanidin extract: importance in human health and disease prevention. *Toxicology* 148: 187–197
38. Bagchi D et al (1997) Oxygen free radical scavenging abilities of vitamins C and E, and a grape seed proanthocyanidin extract in vitro. *Res Commun Mol Pathol Pharmacol* 95: 179–189
39. Zhao J et al (1999). Anti-tumor-promoting activity of a polyphenolic fraction isolated from grape seeds in the mouse skin two-stage initiation-promotion protocol and identification of procyanidin B<sub>5</sub>-3'-gallate as the most effective antioxidant constituent. *Carcinogenesis* 20: 1737–1745

40. Serwin AB, Chodyncka B (2001) The role of selenium in skin. *Wiad Lek (Poland)* 54(3-4): 202-207
41. Greul AK et al (2002) Photoprotection of UV-irradiated human skin: an antioxidative combination of vitamins E and C, carotenoids, selenium and proanthocyanidins. *Skin Pharmacol Appl Skin Physiol* 15(5): 307-15
42. Cesarini JP et al (2002) Immediate effects of UV radiation on the skin: modification by an antioxidant complex containing carotenoids. *Photodermatol Photoimmunol Photomed* 19(4): 182-189
43. Eichler O et al (2002) Divergent optimum levels of lycopene, beta-carotene and lutein protecting against UVB irradiation in human fibroblasts. *Photochem Photobiol* 75(5): 503-506
44. Roos TC et al (1998) Retinoid metabolism in the skin. *Pharmacol Rev* 50(20): 315-333
45. Kligman AM et al (1986) Topical tretinoin for photoaged skin. *J Am Acad Dermatol* 15: 836-859
46. Varani J et al (2000) Vitamin A antagonizes decreased cell growth and elevated collagen-degrading matrix metalloproteinases and stimulates collagen accumulation in naturally aged human skin. *J Invest Dermatol* 114: 480-486
47. Djerassi D (2001) The role of vitamins in high performance cosmetics. *Cosmetics and Toiletries Manufacturers Worldwide*
48. Fisher GJ et al (1998) Retinoic acid receptor-gamma in human epidermis preferentially traps all-trans retinoic acid as its ligand rather than 9-cis retinoic acid. *J Invest Dermatol* 110: 297-300
49. Prystowsky JH (2001) Topical retinoids. In: Wolverton, SE (ed) *Comprehensive dermatologic drug therapy*. Saunders, Philadelphia pp 578-594
50. Duell EA et al (1997) Unoccluded retinol penetrates human skin in vivo more effectively than unoccluded retinyl palmitate or retinoic acid. *J Invest Dermatol* 109: 301-305
51. Duell EA (1996) Retinoic acid isomers applied to human skin in vivo each induce a 4-hydroxylase that inactivates only trans-retinoic acid. *J Invest Dermatol* (106): 316-320
52. Weiser H (1987) Wound healing effects of topical application of panthenol on mammalian skin. *Hoffmann-La Roche*
53. Lacroix B (1988) Effect of pantothenic acid on fibroblast cell cultures. *Res Exp Med* 188: 391-396
54. Tanno O et al (2000) Nicotinamide increases biosynthesis of ceramides as well as other stratum corneum lipids to improve the epidermal permeability barrier. *Br J Dermatol* 143: 524-531
55. Johnson AW (2002) Hydroxy acids. *Skin moisturization. Cosmetic Science and Technology Series* 25: 323-352
56. Grimes P et al (2004) The use of polyhydroxy acids (PHAs) in photoaged skin. *Cutis* 73 (Suppl 2): 3-13
57. Edison BL et al (2004) A polyhydroxy acid skin care regimen provides antiaging effects comparable to an alpha-hydroxy acid regimen. *Cutis* 73 (Suppl 2): 14-17
58. Leveque JL, Saint-Leger D (2002) Salicylic acid and derivatives. *Skin moisturization. Cosmetic Science and Technology Series* 25: 353-363
59. Zulli, F et al (1998) Improving skin function with CM-glucan, a biological response modifier from yeast. *Int J Cosmet Sci* 20(2): 79-86
60. Leibovich SJ, Danon D (1980) Promotion of wound repair in mice by application of glucan. *J Reticuloendothel Soc* 27: 1-11
61. Czop JK, Austen KF (1985) A beta-glucan inhibitable receptor on human monocytes: its identity with the phagocytic receptor for particulate activators of the alternative complement pathway. *J Immunol* 134: 2588-2593
62. Zulli F et al (1995) Photoprotective effects of CM-glucan on cultured human cells. *Euro Cosmetics* 11: 46-50
63. Elmets CA (1992) Photoprotective effects of sunscreens in cosmetics on sunburn and Langerhans cell photodamage. *Photodermatol Photoimmunol Photomed* 9: 113
64. Hersh T (2003) Reparatives for chemosurgery and laser therapy. *United States Patent*: 6,630,442
65. Keller SJ et al (1991) Isolation and characterization of a tissue respiratory factor from bakers yeast. *J Cell Biol* 304: 21
66. Bentley JP et al (1990) Peptides from live yeast cell derivative stimulate wound healing. *Arch Surg* 125: 641-646
67. Pickart L, Lovejoy S (1987) Biological effects and the mechanism of action of the plasma copper-binding growth factor glycy-l-histidyl-l-lysine. *Methods Enzymol* 147: 314-328
68. Harris ED (1992) Copper as a cofactor and regulator of copper, zinc superoxide dismutase. *J Nutr* 122: 636-640
69. Pickart L et al (1986) Gly-l-his-l-lys: copper (II) - A human plasma factor with superoxide dismutase-like and wound-healing properties, In: Rolitio (ed) *Superoxide and superoxide dismutase in chemistry, biology and medicine*. Elsevier, Amsterdam pp 555-558
70. Leyden JJ et al (2002) Skin care benefits of copper peptide containing facial creams. *Amer Acad Derm Poster Abstract*
71. Leydon JJ et al (2002) Skin benefits of copper-peptide-containing eye creams. *Amer Acad Derm Poster Abstract*
72. Katayama K et al (1993) A pentapeptide from type I procollagen promotes extracellular matrix production *J Biol Chem* 268: 9941-9944
73. Gutierrez LM et al (1997) A peptide that mimics the c-terminal sequence of SNAP-25 inhibits secretory vesicle docking in chromaffin cells. *J Biol Chem* 272: 2634-2639
74. Blanes-Mira C et al (2004) Small peptides patterned after the N-terminus domain of SNAP25 inhibit SNARE complex assembly and regulated exocytosis. *J Neurochem* 88(1): 124-135



# Photoaging and Pigmentary Changes of the Skin

Susan C. Taylor

## Core Messages

- Several mechanisms and mediators appear to control human aging, including longevity genes, cell death mediated by telomere shorting, and free radical activation.
- Clinical characteristics such as pigmentary changes and photoaging overshadow those of intrinsic aging. Pigmentary changes are major components of photoaging in the major skin types, including Asian, African American, and Caucasian.
- Intrinsic aging is marked by atrophy of the epidermis and dermis whereas photoaging is marked by dysplasia of epidermal cells, melanocyte heterogeneity, and elastosis of the dermis.
- Features of photoaging, including pigmentary changes, may be prevented by limiting ultraviolet (UV) light exposure.
- Use of sunscreen to block both UVA and UVB light is an important preventative measure.
- Antioxidants most likely play a role in the prevention of photoaging.

## Contents

3.1	<b>Introduction</b> . . . . .	29
3.2	<b>Mechanisms of Aging</b> . . . . .	31
3.3	<b>Clinical Characteristics of Photoaging and Pigmentary Changes</b> . . . . .	33
3.3.1	Asian Skin . . . . .	34
3.3.2	African American Skin . . . . .	36
3.3.3	Caucasian Skin . . . . .	38
3.4	<b>Histology of Photoaged Skin</b> . . . . .	41
3.4.1	The Pigmentary System in Photoaged Skin . . . . .	43
3.5	<b>Overview of Prevention of Photoaging and Pigmentary Changes of the Skin</b> . . . . .	44
3.6	<b>Overview of Treatment of Photoaging and Pigmentary Changes of the Skin</b> . . . . .	45
3.7	<b>Summary</b> . . . . .	48
	<b>References</b> . . . . .	49

## 3.1 Introduction

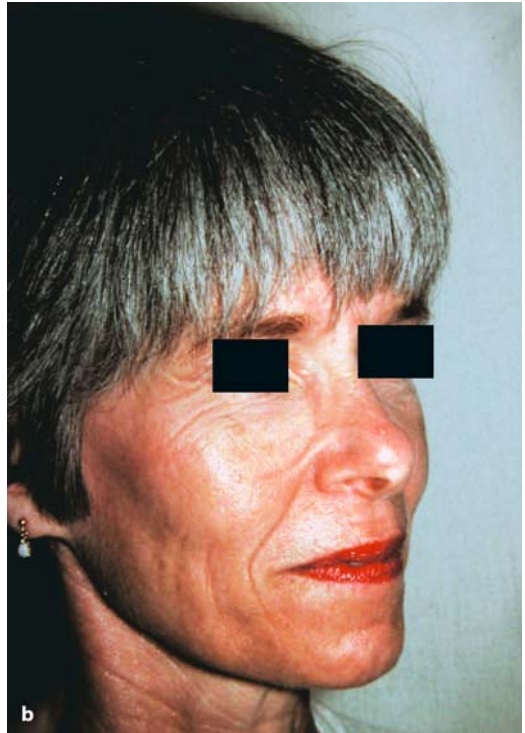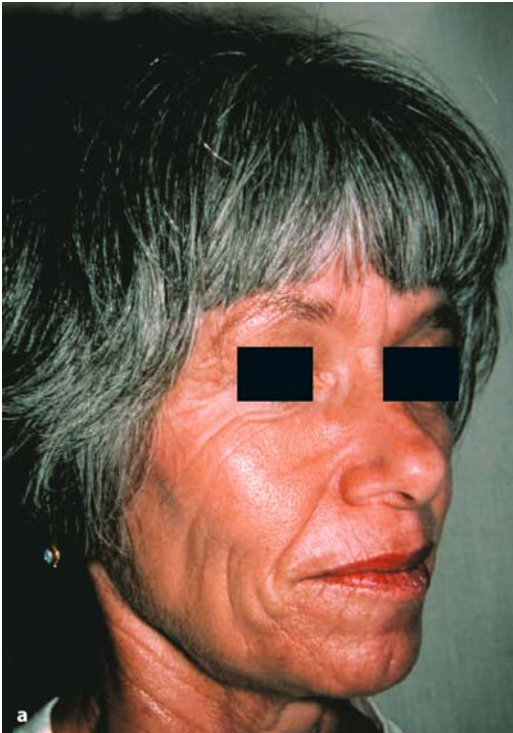The inevitable process of aging begins at the time of birth. With maturity, the features of intrinsic or chronological aging become apparent. The cutaneous manifestations of chronological aging are manifold and include a smooth, pale appearance of the skin with fine wrinkling and loss of hydration [1]. The characteristics of intrinsic aging are often overshadowed by those of photoaging. Photoaging, aging of the skin induced by repeated exposures to ultraviolet (UV) light, leads to dramatic changes in the skin. These differences are highlighted by twin studies performed by New York City plastic surgeon Dr. Darrick E. Antell in which one twin with a significant sun exposure

history displayed dramatic wrinkling compared with her sun-protected twin (Fig. 3.1a,b). Clinical characteristics of photoaging include fine and coarse wrinkling, roughness, dryness, telangiectasia, cancerous lesions, precancerous lesions, and pigmentary alterations. Pigmentary alterations are a major component of photoaged skin and may be observed all skin types [2]. Pigmentary alterations associated with photoaged skin are of several varieties, including hypermelanosis as well as hypomelanosis. Mottled hyperpigmentation, ephelides, lentigines, and pigmented seborrheic keratoses are the primary lesions of hypermelanosis. Guttate hypomelanosis, presenting as white spots, is the primary manifestation of hypomelanosis associated with aged skin.

Intrinsic aging occurs universally in individuals of all racial and ethnic groups and with all skin types. In contrast, there is variability in the severity and manifestations of photoaging in

Asians, African Americans, and Caucasians. Epidermal melanin content and melanosomal distribution mediates the damaging effect of UV light and accounts for much of the difference. The mean protective factor for UVA and UVB (which is equivalent to endogenous sun protection factor) differs quite substantially between whites and blacks [3]. Additionally, individual sun exposure habits strongly influence the degree of photodamage, with those individuals with greater sun exposure experiencing greater photodamage. Racial and ethnic variability in photoaging is noted in relation to the degree of wrinkling of the skin as well as with the type of pigmentary lesions that develop.

Both intrinsic aging and photoaging are complex processes. Histological characteristics of intrinsic aging and photoaging have been studied via electron and light microscopy. Furthermore, an understanding of the underlying mechanisms responsible for aging is being



**Figs. 3.1a,b.** The manifestations of photoaging after repeated exposures to ultraviolet light are highlighted by twin studies performed by New York City plastic surgeon Dr. Darrick E. Antell in which one twin with a significant sun-exposure history displays dramatic wrinkling (a) compared with her sun-protected twin (b)

achieved. This includes genetic as well as environmental factors. Advances in both invasive and noninvasive therapeutic modalities for the treatment of photoaging have led to the burgeoning field of cosmetic dermatology. These aspects will be discussed in this chapter, with an emphasis on the pigmentary changes of photoaging.

### 3.2 Mechanisms of Aging

In the past decade, scientific research has made astounding progress in elucidating the mechanism of aging of the human body, including the integument. As one might expect, aging appears to be due to a composite of genetic as well as environmental factors. There appear to be several mechanisms and mediators that control the multiple components of the human aging process. For example, in several lower species, the genes controlling longevity have been successfully identified; corresponding genes are now being investigated in humans. Derangements in the genes that control premature aging syndromes have been identified and provide insight into the mechanism of aging. Chromosomal structures responsible for cell senescence are known to play a crucial role in both intrinsic and photoaging. Furthermore, the role of free radicals in the aging process has been long recognized. Finally, the likely molecular mechanism whereby UV light produces cellular damage leading to photoaging has been elucidated. Each of these components, as outlined below, will lead to a more complete understanding of the complex process of aging in humans.

Although a gene that controls the overall aging process has not been identified in humans, in organisms such as fungi, yeast, and fruit flies, 35 genes that determine life span have been cloned [4]. These genes are responsible for many different functions, suggesting that there are multiple mechanisms of aging. In the lower organisms studied, Jazwinski identified four principle processes responsible for aging, which include: metabolic control, resistance to stress, gene dysregulation, and genetic stability. Some of the longevity genes identified respond

to stresses such as ultraviolet radiation, oxidative damage, starvation, and temperature extremes. There are conceivably many ways to impact these genetic processes and improve longevity, such as caloric restriction, which may potentially affect metabolic control and stress. Many human homologs of the longevity genes found in lower organisms have been identified and are currently being studied [5]. It is proposed that manipulation of these genes might improve human longevity.

The fact that genes play a crucial role in aging is supported by genetic disorders in which the aging process is greatly altered, such as in Werner's syndrome. Werner's syndrome, a disorder of premature aging, is characterized by many features, including an aged appearance, premature canities, alopecia, skin atrophy, cataracts, arteriosclerosis, and death before age 50. Evaluation of individuals with this syndrome has provided insight into one possible genetic mechanism of aging. The Werner's syndrome gene, which was cloned by Yu, has been identified as a DNA helicase [6]. Defective DNA metabolism as a result of the Werner's syndrome mutation is felt to be responsible for premature aging in these individuals. In progeria, another genetic disorder of accelerated aging, a misregulation of mitosis has been identified as the mechanism of premature aging [7]. An analysis of fibroblast mRNA levels in progeria patients revealed misregulation of structural, signaling, and metabolic genes. Thus, several different genes may be responsible for various aspects of aging.

Much attention has been given to genetically programmed cell death as the final common pathway to aging. Cellular senescence, the inability of cells to divide indefinitely (cell death), occurs as a result of intrinsic aging as well as photoaging. Cell senescence is controlled by telomeres. Telomeres are the repeating DNA base sequences thymine-thymine-adenine-guanine-guanine-guanine (TTAGGG) at the ends of chromosomes [8]. They are thousands of base pairs long and protect the ends of each chromosome from damage. Shortening of the telomere has been demonstrated in older adults, compared with younger individuals, and in individuals with premature aging as in



Werner's syndrome, thus supporting the importance of telomeres in aging [9, 10]. With each round of cell division, telomeres become shorter and shorter until a point is reached when the cell is no longer able to divide and cell death occurs. There is a folded structure at the very end of the telomere that consists of an array of 150–200 single-stranded bases referred to as the 3' overhang [11]. The 3' overhang is configured in a folded loop that serves a protective function [12]. As the chromosome replicates, a critical point is reached when the overhang is exposed and digested [13]. Cell signaling occurs (by the ataxia telangiectasia mutated kinase protein and the p53 tumor suppressor protein) causing senescence of cells, such as fibroblasts and apoptosis of lymphocytes [14]. In addition to repeated replication, as occurs in intrinsic aging producing telomere shortening and disruption, acute DNA damage as occurs in photoaging also leads to activation of the same mediators, telomere shortening, and cell senescence. Acceleration of aging occurs with UV damage that, in addition to shortening and disrupting telomeres, causes increased cell division to repair DNA thus leading to even further shortening of telomeres. Telomerase, a ribonucleoprotein identified in tumor cells makes telomeric sequences to replace shortened telomeres [15]. Bodnar demonstrated an extension of life span by the introduction of telomerase into retinal epithelial cells and fibroblasts [16]. In an experimental model utilizing DNA oligonucleotides, which mimic the telomere 3' overhang, Gilchrest's group demonstrated that treatment with oligonucleotides may mimic telomere disruption signals without affecting the cell's own DNA and thus enhance the DNA repair process [17].

Although the free radical theory of aging has received much attention recently with the increasing popularity and commercialization of antioxidant products, it is a theory that dates back over 40 years [18]. The theory is that aging is caused by free radicals or reactive oxygen species, which are molecules with an unpaired electron. Free radicals that include singlet oxygen ( $^1\text{O}_2$ ), superoxide ( $\text{O}_2^-$ ), hydrogen peroxide ( $\text{H}_2\text{O}_2$ ), and hydroxyl radical (HO) strongly attract electrons from DNA, cell membranes, and

proteins, which leads to damage of those components. The damage done by free radicals contributes to aging. Both intrinsic and extrinsic aging generate free radicals through either internal oxidative metabolism or through external environmental factors, including pollution, cigarette smoking, and UV radiation [19]. A common pathway involving telomeres links free radicals to aging. Free radicals target the guanine residues that make up 50% of the telomere overhang structure [20].

The likely molecular mechanism explaining photoaging was elucidated by Fisher [21]. The basic tenant is that in photoaging, UV light generates free HOs, which stimulate matrix metalloproteinases (MMP) that then degrade extracellular matrix components. More specifically, cell surface receptors, including epidermal growth factor receptor and cytokine receptor, on keratinocytes and fibroblasts are activated by UV light. Three mitogen-activated protein kinase (MAP) pathways are then activated: extracellular signal-regulated kinase (ERK), cJun amino-terminal kinase (JNK), and p38. These pathways converge in the cell nucleus, and two transcription factor components, cFos and cJun, combine to form activator complex 1 (AP-1). AP-1 then simulates the transcription of MMP genes to produce collagenase, 92-kd gelatinase, and stromelysin-1. These enzymes degrade collagen, elastin, and other extracellular matrix components. With repeated UV exposure, more dermal damage occurs that cannot be fully repaired, leading over time to photoaged skin.

In his elegant series of experiments, Fisher irradiated white skin with UV lights and then evaluated it by a variety of techniques [21]. A single exposure to UV irradiation increased the expression of the three MMPs previously discussed compared with nonirradiated skin, which did not. Degradation of type I collagen fibrils was increased by 58% in the irradiated skin compared with nonirradiated skin. UV irradiation also induced tissue inhibitor of matrix metalloproteinases-1, which partially inhibited MMPs. Of note, pretreatment of skin with tretinoin inhibited the induction and activity of MMPs by 70–80% in connective tissue as well as the outer layers of irradiated skin.

Kang recently demonstrated that the generation of free radicals by UV light was impaired by the antioxidant genistein and the antioxidant precursors n-acetyl cysteine [22].

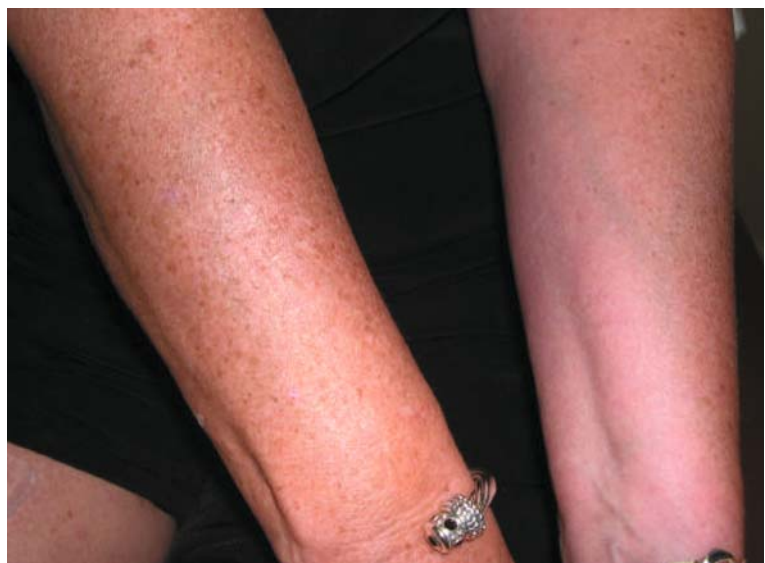### 3.3 Clinical Characteristics of Photoaging and Pigmentary Changes

The clinical characteristics of photoaged skin are more pronounced compared with those observed in intrinsic aging (Table 3.1). It is these changes that are of cosmetic concern to many individuals as they overshadow those associated with intrinsic aging. In intrinsic aging, the skin has a pale appearance with fine wrinkling. It has been demonstrated that the dermis thins by 20% with intrinsic aging, with the most

prominent thinning after the eighth decade [23, 24]. Additionally, melanocytes also decrease during adulthood, with an estimated decrease of 10% per decade [25]. As expected, pigmentary changes are not a prominent feature of intrinsically aged skin compared with photoaged skin (Fig. 3.2). Environmental factors that contribute to aging, such as pollution and smoking, produce marked wrinkling of the skin but not pigmentary abnormalities. There are several different manifestations of pigmentary alterations associated with photoaged skin. These include mottled hyperpigmentation, solar lentigines, diffuse hyperpigmentation, pigmented seborrheic keratoses, and guttate hypopigmentation. Some manifestations of photoaging are more prominently displayed in certain racial groups compared with others. These differences will be discussed below and are highlighted in Table 3.2.

**Table 3.1.** Clinical characteristics of intrinsic aging and photoaging

Clinical characteristic	Intrinsic aging	Photoaging
Pigmentation	Pale, white, hypopigmentation	Mottled, confluent, and focal hyperpigmentation
Wrinkling	Fine lines	Deep furrows
Hydration	Dry and flakey	Dry and rough
Growths	Benign	Cancerous and benign



**Fig. 3.2.** Pigmentary changes are not a prominent feature of intrinsically aged skin as seen on the sun-protected flexor arm compared with the pigmentation displayed on the sun exposed extensor arm of the same woman

**Table 3.2.** Pigmentary characteristics of photoaging in Asian, African American and Caucasian skin

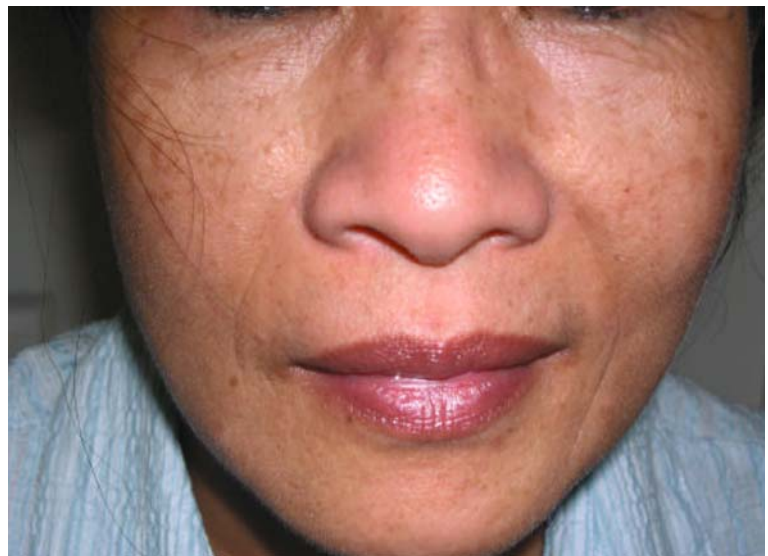Clinical Feature	Asian	African American	Caucasian
Ephelides	+	-	++
Lentigines	++	-	++
Mottled hyperpigmentation	+	+	++
Seborrheic keratoses	++	+	-
Dermatosis papulosa nigra	-	++	-

### 3.3.1 Asian Skin

Many Asians residing in the Far East are exposed to sunlight year round and are therefore very susceptible to photodamage and accompanying photoaging. Several studies of Asian populations demonstrate pigmentary changes as a major component of photoaging. These include facial hyperpigmentation, solar lentigines, and pigmented seborrheic keratoses (Fig. 3.3). In a study by Goh, the characteristics of photoaging in an Asian population in Singapore, which consisted of Chinese, Indonesians, and Malaysians, was described [26]. The population consisted of 1,500 subjects with skin types III and IV. In this population, hyperpigmentation was noted to be an early and prominent feature of photodamage. In contrast, coarse and fine

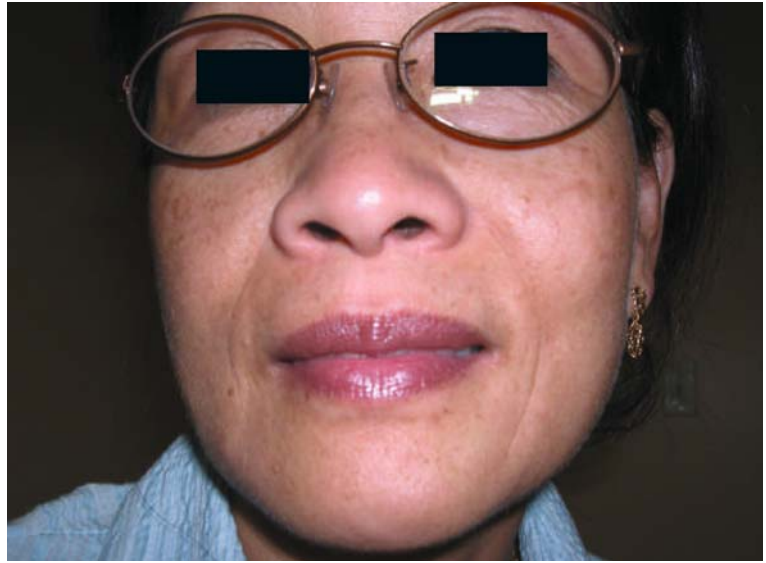wrinkling were found to be late and inconspicuous features of photoaging.

Characteristics of cutaneous photodamage in another Asian population consisting of 407 Korean men and women ages 30–92 years were investigated by Chung [27]. Chung identified wrinkling and dyspigmentation as the primary characteristics of photoaging in that population. Figure 3.4 is an example of both dyspigmentation and wrinkling in an Asian woman. In this study, the number of wrinkles increased as the age of the individual increased. This was the case as well for dyspigmentation. In the Korean population, dyspigmentation appeared as two distinct types of lesions: hyperpigmented macules on sun-exposed skin were described, as well as pigmented seborrheic keratoses. The number of pigmentary lesions increased as the age of the individual increased. Gender differ-

**Fig. 3.3.**

Asian populations demonstrate pigmentary changes as a major component of photoaging, including facial hyperpigmentation, solar lentigines and pigmented seborrheic keratoses

**Fig. 3.4.**  
Dyspigmentation and periorbital wrinkling in an Asian woman



ences in the type of pigmentary lesions were also noted. In Koreans greater than 60 years of age, seborrheic keratoses were more common in men than in women. In those 50 years of age and older, hyperpigmented macules were found more frequently in women than in men. Women in the fourth decade had an average of 4.3 hyperpigmented macules, which increased to 23.5 by the sixth decade and 25.1 by the eighth decade. Men in the fourth decade had an average of 0.1 seborrheic keratoses, which increased to 4.6 by the sixth decade and 13.6 by the eighth decade.

Additionally, Chung established the association between sun exposure and the development of wrinkling in the Korean population [27]. Previously, wrinkling was not felt to be a major feature of photoaging in Asian populations. Chung demonstrated wrinkling in 19.2% of Koreans with a daily exposure of 1–2 h compared with 64.6% of those who had more than 5 h/day. Sun exposure of more than 5 h/day was associated with a 4.8-fold increased risk for wrinkling compared with 1–2 h/day. The pattern of wrinkling in both sexes was similar, but there was a greater risk for development of wrinkles in women than in men after controlling for age, sun exposure, and smoking. In this study, with regard to both wrinkles and dyspig-

mentation, increased severity became apparent at 50 years of age, and there was a statistically significant association between wrinkling grades and dyspigmentation grades. The effect of excessive sun exposure and cigarette smoking on wrinkling was found to be multiplicative in this Korean population. Sun exposure of more than 5 h/day and a smoking history of more than 30 pack-years (when controlled for age and gender) were associated with a 4.2-fold increased risk for wrinkling compared with a 2.2-fold increase for nonsmokers with 1–2 h/day of sun exposure. There was, however, no significant association observed between smoking and dyspigmentation.

Kwon reported the prevalence of pigmented seborrheic keratoses in 303 Korean males ages 40–70 years [28]. Seborrheic keratoses occurred on sun-exposed areas of the skin, with the majority of lesions concentrated on the face and the dorsa of the hands. Similar to Chung's report, the prevalence of seborrheic keratoses in Kwon's study was shown to increase by age, with 78.9% of Korean men having seborrheic keratoses at age 40, 93.9% at age 50, and 98.7% at 60 and older. The mean overall prevalence of seborrheic keratoses in was 88.1%. Both chronological aging and cumulative sun exposure were independent variables for the develop-

ment of seborrheic keratoses. Those Koreans with a lifetime cumulative sun exposure of more than 6 h/day had two times the risk of developing seborrheic dermatoses than those with less than 3 h/day. In summary, in Asian skin, in addition to wrinkling, hyperpigmented macules, solar lentiginos, and seborrheic keratoses were the major pigmentary alterations as demonstrated in several studies.

### 3.3.2 African American Skin

It is well established that melanin confers protection from UV light. Kaidbey demonstrated increased photoprotection by melanin in black compared with white skin [29]. The mean protective factor for UVB for black epidermis was 13.4 compared with 3.4 for white epidermis. Similarly, the mean protective factor for UVA for black epidermis was 5.7 compared with only 1.8 for white epidermis. Given the photoprotective effect of melanin, one would anticipate that African Americans would display fewer changes associated with photoaging compared with those individuals with white skin. Hence, African American women often appear younger than Caucasian women of the same age (Fig. 3.5a,b). Additionally, the onset of the cutaneous manifestations of photoaging reportedly occurs at a later age in African Americans compared with whites [30]. As would be expected, photoaging in African Americans is more pronounced in individuals with lighter skin hues [31]. Long-term sun exposure to African American skin does not produce the readily apparent characteristics of photoaging observed in white skin. For example, wrinkling beside the lateral canthi of the eyes and at the corners of the mouth occurs less often in African Americans compared with whites [32]. Montagna also found that shrinkage and reduction of dermal volume leading to sagging of the facial skin occurred less precipitously in the facial skin of young and middle-aged black women.

Photoaging features most often apparent in the African American population include fine wrinkling, skin textural changes, benign cutaneous growths, and pigmentary abnormalities [33]. Although not well characterized, there are

several pigmentary abnormalities observed in African American skin. Hyperpigmentation assumes several forms. Focal areas of hyperpigmentation, either mottled or more confluent, impart an uneven skin tone, which is a common cosmetic complaint for African American women in particular (Fig. 3.6). Another not uncommonly observed type of hyperpigmentation is a generalized darkening of the facial skin compared with the sun-protected areas (Fig. 3.7). It is known that skin pigmentation increases with exposure to both UVA and UVB radiation. Whereas the production of melanin from the stimulation of UVB is of short duration, that due to cumulative UVA exposure appears to be much longer lasting [34]. UVB-induced pigmentation disappears with epidermal turnover within a month, in contrast to UVA pigmentation that may last several months to a year. The difference is likely related to the basal localization of UVA-induced pigment. Long-term UVA-stimulated pigmentation may very well explain the general darkening of the sun-exposed skin frequently observed in African Americans.

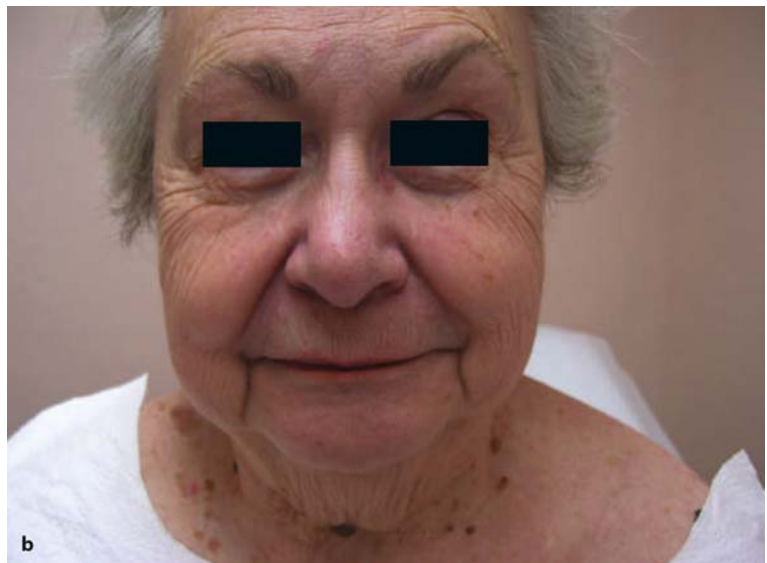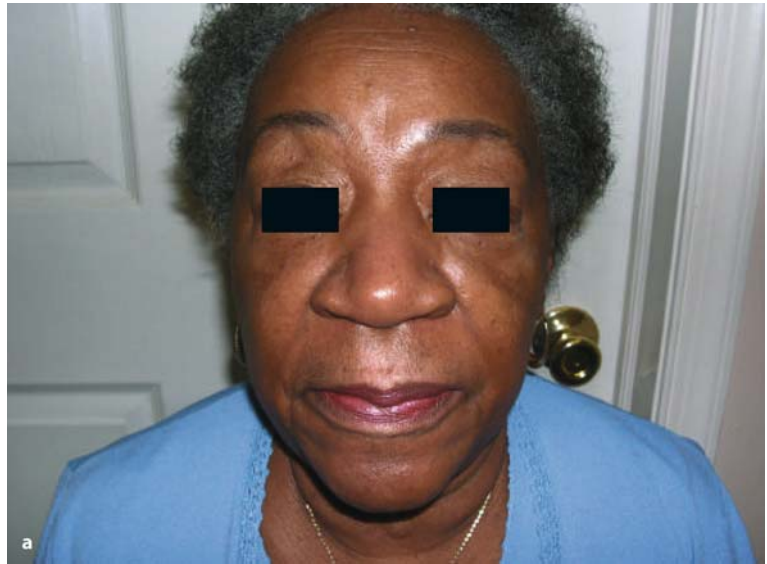Solar lentiginos are not a primary component of photoaging in African American skin. This is undoubtedly related to the photoprotective effect of melanin, as discussed previously. Although not formally studied as in Asian skin, it has been observed that benign pigmented lesions are a frequent component of aging in African Americans. Seborrheic keratoses are noted on sun-exposed as well as sun-protected skin. Dermatitis papulosa nigra (DPN), a type of seborrheic keratosis, is prominent only on the sun-exposed facial skin of both African American men and women. It is theorized that chronological aging and cumulative sun exposure are variables for the development of DPNs.

Disorders of hypomelanosis are readily apparent in African Americans, given the contrast between the normally pigmented skin and the contrasting white area. Guttate hypomelanosis is characterized by multiple, small, depigmented macules on the anterior surface of the legs, lower abdomen, and arms [35]. The macules are circular with well-defined borders. The differential diagnosis in this group would include vitiligo.



**Figs. 3.5a,b.**

An African American woman who appears younger than a Caucasian woman of the same age



In summary, in African American skin, discrete and confluent hyperpigmentation, seborrheic keratoses, dermatosis papulosa nigra, and idiopathic guttate hypomelanosis are the major pigmentary alterations demonstrated.

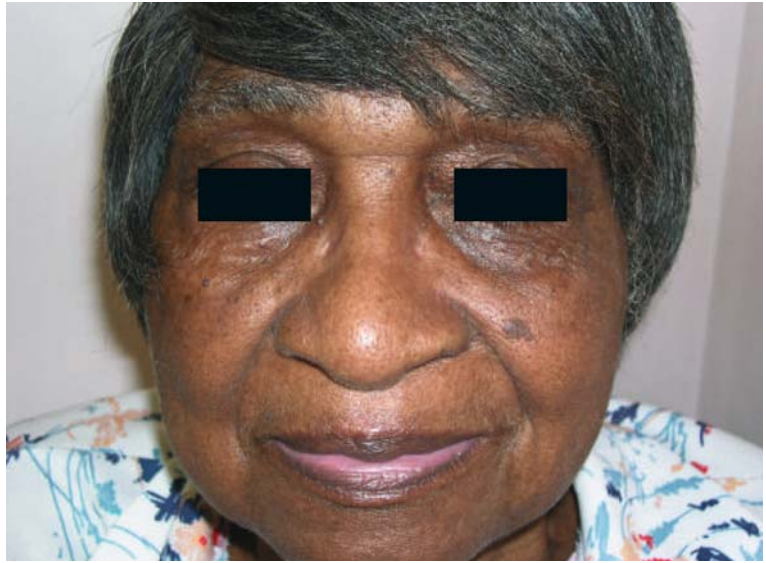### 3.3.3 Caucasian Skin

Wrinkling and dyspigmentation are commonly observed features of photoaging in Caucasian skin (Fig. 3.8). Warren studied photoaging in Caucasian women ages 45–51 with skin types I–III who resided in an area of intense sunlight: Arizona [36]. The investigators, after viewing photographs of nine Caucasian women who had received more than 12 h/week of sun expo-

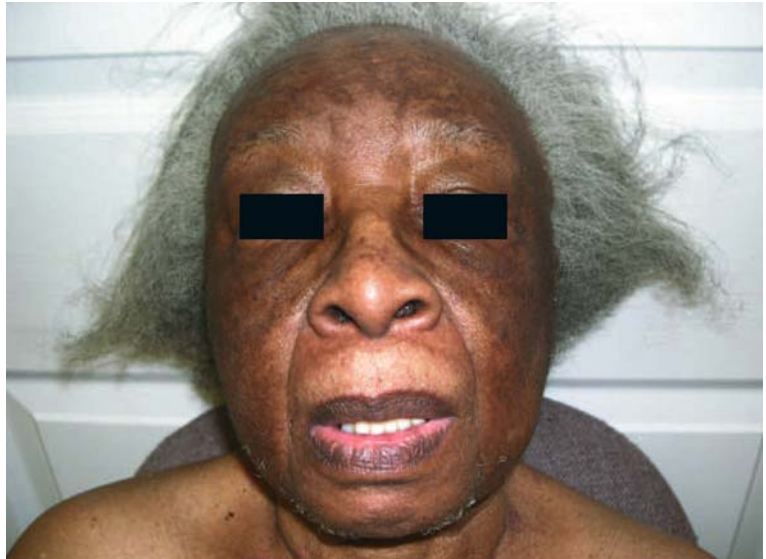

**Fig. 3.6.**

Focal areas of hyperpigmentation, either mottled or confluent, impart an uneven skin tone to the faces of many African American women

**Fig. 3.7.**

A generalized darkening of the facial skin compared with the sun-protected areas of the upper chest and shoulders in this African American woman

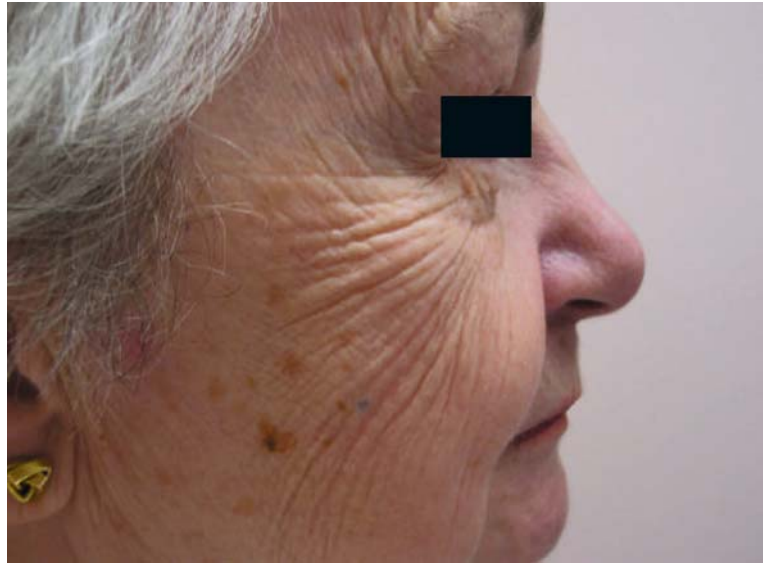


sure for 10 years' duration, estimated their mean age to be 58.2 years. This contrasts with an estimated mean age of 53.7 years for 13 Caucasian women who had experienced less than 2 h/week of sun exposure. Additionally, the women with more sun exposure had more wrinkles in the crow's feet area as well as on the remainder of the face compared with those with less exposure. In the study, the total length of all furrows

and lines (wider than 0.5 mm and longer than 5.0 mm) was summed for each group. Sun exposure increased the total wrinkle length with the women with greater exposure for a total wrinkle length of 75.7 cm compared with the low-exposure group, with 53.5 cm total wrinkle length.

Dyspigmentation is a major component of photoaging observed in white skin [37]. Dyspigmentation not readily observable becomes

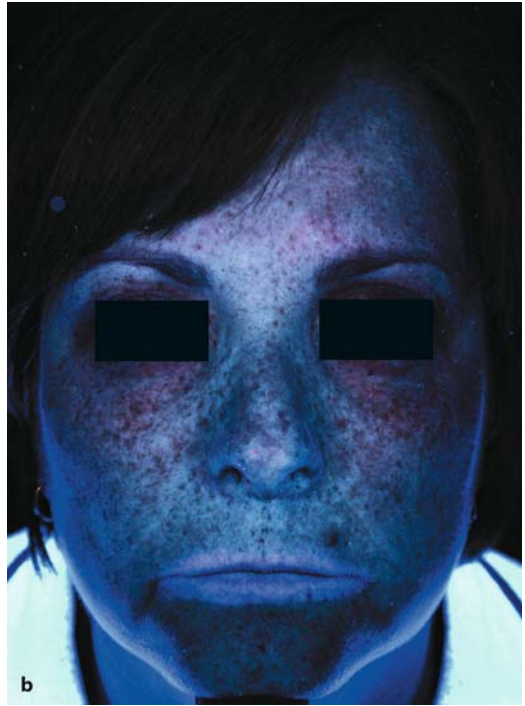
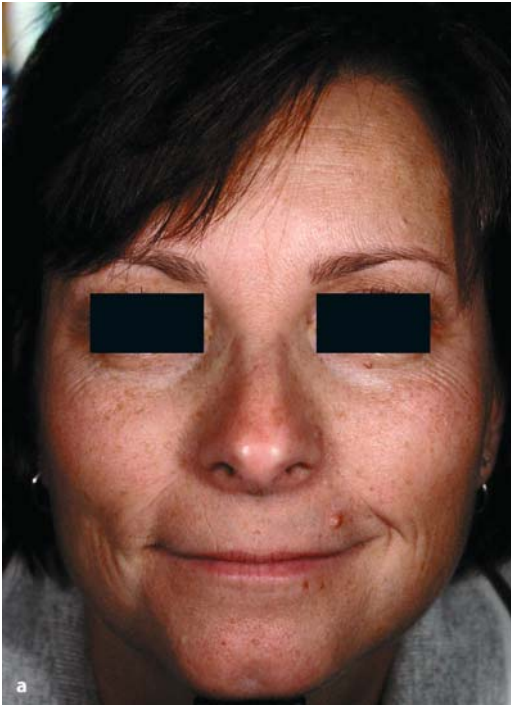
**Fig. 3.8.**  
Wrinkling and dyspigmentation are commonly observed features of photoaging in Caucasian skin



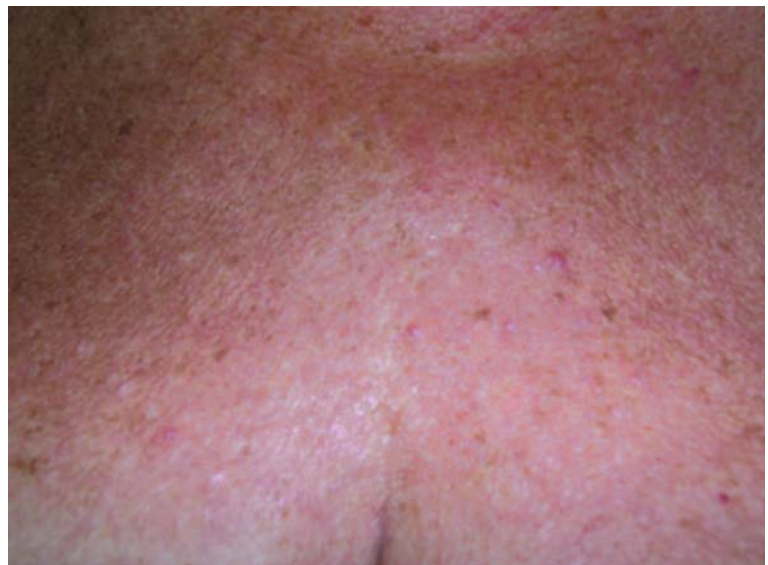significantly more prominent under Wood's light examination or UV photography. Discrete and mottled hyperpigmentation under normal and UV photography is seen in Fig. 3.9a,b, which are courtesy of George Faraghan, Faraghan Medical, Philadelphia, PA, USA. One of the manifestations of dyspigmentation in photoaged white skin is mottled, irregular areas of pigmentation [38]. The mottled appearance correlates with areas of hyperpigmentation with irregular distribution of melanocytes along the basement membrane. This is associated with a heterogeneous distribution of melanosomes within the keratinocytes and adjacent areas of hypopigmentation with decreased melanocytes and melanosomes [39].

Another manifestation—freckles, or ephelides—are small, brown macules on sun-exposed skin that darken and increase in number with more intense sun exposure during the summer months. They appear in fair-skinned individuals and genetically predisposed children. Pigmented seborrheic keratoses occur as a manifestation of aged skin but seemingly occur less frequently on sun-exposed white skin compared with Asian skin. Likewise, dermatosis papulosa nigra also appear to occur less often in white skin compared with African American skin.

Solar or actinic lentigines appear during the fourth through sixth decades in sun-exposed skin. They are a readily apparent sign of photoaging in white skin and appear on the face, chest, extensor forearms, and dorsa of the hands (Fig. 3.10). There is variation in their size, ranging from several millimeters to over a centimeter, as well as in the regularity of their borders. The incidence of solar lentigines increases with age, affecting more than 90% of whites older than 50 years [37]. They are related to a tendency to freckling and sunburns after the age of 20 years [40]. They are usually numerous and may be accompanied by adjacent patchy hypopigmentation, which involves a decrease in the number of melanocytes associated with a reduction in the production of mature melanosomes. This results in a mottled appearance of the skin [41]. Lentigines darken significantly after exposure to sunlight [42]. The differential diagnosis of lentigines includes other pigmented lesions, including lentigo maligna, pigmented actinic keratoses, pigmented basal cell carcinomas, and flat or macular seborrheic keratoses. Whereas solar lentigines occur in all skin types, the reticulated black solar lentigo occurs primarily in sun-exposed skin of very fair-skinned whites [43]. It resembles a spot of ink on the skin with irregular margins and a retic-



**Fig. 3.9a,b.** Discrete and mottled hyperpigmentation under normal photography (a) and ultraviolet (UV) photography (b). Photographs are courtesy of George Faraghan, Faraghan Medical Photography, Philadelphia, PA, USA



**Fig. 3.10.** Solar lentigines and other pigmentary manifestations of photoaging on the chest of a Caucasian woman

ular pattern. Black solar lentigines are considered a rare variant of actinic lentigines. They are few in number in contrast with the large number of lentigines, and they must be distinguished from melanoma.

Hypomelanosis is observed in Caucasian skin, although it may not be as readily apparent in white skin. Guttate hypomelanosis is characterized by multiple, small, depigmented macules on the anterior surface of the legs, lower abdomen, and arms [44]. The macules are circular with well-defined borders. In summary, in white skin, in addition to wrinkling, ephelides, lentigines, and mottled hyperpigmentation were the major pigmentary alterations demonstrated in several studies.

### 3.4 Histology of Photoaged Skin

Several investigators have evaluated the histological changes associated with photodamaged skin in various racial groups and utilizing various techniques [45, 46, 47, 48]. Characteristics identified are different from those found in intrinsic or chronological aging [23]. In intrinsic aging, there is both epidermal and dermal atrophy, with flattening of the dermal-epidermal junction. Epidermal atrophy is due to the reduction of keratinocytes in the rete ridges, as well as melanocytes and Langerhans cells. There is loss of the undulating pattern of the dermal-epidermal junction. Dermal atrophy is attributed to loss of fibroblasts, elastic fibers, vasculature, and appendages. In adults, the amount of collagen decreases by 1% per year due to decreased collagen synthesis and increased collagenase mRNA [49, 50]. A loss of elastic fibers occurs with fragmentation of elastin fibers. The loss of skin appendages is due to a decrease in the number of hair follicles and in eccrine and apocrine gland size. There is also a decrease in the number of melanocytes in the hair bulb.

Montagna reported the histology of photodamaged facial skin of 200 Caucasian women ages 21–55 who resided in an area of intense sunlight: Arizona [45]. Changes were noted throughout all layers of the skin, including the stratum corneum, epidermis, and dermis. The

stratum corneum of photodamaged skin was compact and laminated. The corneocytes were plump, with amorphous material between and at times inside the corneocytes. The transition between the stratum lucidum and the stratum corneum was often indistinct. The stratum lucidum was thicker compared with normal epidermis, with two or more cell layers. Large vesicles containing proteinous material were noted. Numerous changes were noted in the epidermis, as well. These included cell heterogeneity, vacuolization, dysplasia, and necrosis. The epidermal cells were noted to be in disarray, with atypical shape, size, and/or staining as well as loss of polarity. Necrotic cells were observed in the epidermis, with single dying or dead cells. The epidermis contained intercellular and intracellular vacuoles in the basal and spinous layers. These vacuoles distorted both basal cells and melanocytes. Large, pale, staining cells were present in the spinous layer. Fewer Langerhans cells were present in severely photodamaged skin compared with normal skin. Dyskeratotic or stem cells were present in the basal layer. The periodic acid-Schiff (PAS) positive basement membrane was distinctly crinkly as it followed the extensions of the basal cells. Empty vesicles formed a foamy layer beneath the basement membrane. In regard to pigmentary changes of photodamaged skin, basal and suprabasal keratinocytes contained more melanosomes in both photoaged and normal skin. In darkly pigmented areas of the skin, melanosomes were present in all of the keratinocytes and corneocytes. In the papillary and lower intermediate dermis, elastic fiber masses were noted. Areas with advanced elastosis were found to be next to areas with fewer elastotic changes. In areas with enlarged, knotted, elastic fibers and rounded elastotic masses, fragmentation of fibers was observed. The lower papillary and upper intermediate dermis of sun-exposed skin had numerous reticulin fibers accompanying the fibers of the elastotic masses. Small collagen fibers were noted in the papillary dermis. The Grenz zone that replaced the papillary dermis consisted of small fibers horizontally oriented. Elastotic material appeared to crowd out the collagenous fibers.



Warren's group also studied photoaging in Caucasian women [46]. They evaluated histology, actinic elastosis, and collagen in four groups of Caucasian women ages 45–51 with skin types I–III who resided in Arizona. The groups were divided according to age (younger versus older) and sun exposure (low versus high). Skin color, erythema, and darkness were evaluated using the CIE  $L^*$ ,  $a^*$ ,  $b^*$  color scale. No differences in skin color with respect to skin redness and darkness were identified among the four groups. However, other histological characteristics of photoaging were identified. The older women had a statistically significant more elastosis than the younger women. Additionally, elastosis was more significant in the older women with high sun exposure compared with the older low-sun-exposure group. The older high-sun-exposure group had more elastin and decreased dermal collagen than the older low-sun-exposure group. A grenz zone was present in the dermis of all older women regardless of sun exposure. There were no changes in epidermal thickness related to solar exposure.

Electron microscopic characteristics of photoaging in white skin were evaluated by Toyoda [48]. He demonstrated both qualitative and quantitative differences between photoaged and intrinsically aged facial skin. There were several characteristics of sun-exposed facial skin that were statistically significant compared with sun-protected skin. Some of these differences included increased keratinocyte and melanocyte heterogeneity, electron lucent degeneration of epidermal and peri-infundibular keratinocytes, melanocytes with vacuolar structures, dermal melanophages, reduplication of the basal lamina of the epidermis, degenerated microfibrils, solar elastosis, active mast cells, and decrease in normal microfibril bundles. Regarding melanocyte damage, irregularly shaped nuclei and electron-dense cytoplasm in sun-exposed skin compared with sun-protected skin were noted. Semiquantitative evaluation revealed a significant increase in melanocytic heterogeneity in sun-exposed skin. Vacuolar structures in melanocytes were identified, and the degree of vacuolization was commensurate to the severity of the degeneration of keratinocytes. It is likely that these

changes are responsible for the development of pigmentary changes and cancerous changes.

Histological evaluation of photoaged black and Asian skin has also been performed [47, 51]. Compared with white skin, striking differences were noted in individuals with black skin. In one group of Asians from Thailand, marked similarities were noted between white skin and Asian skin [47]. Montagna performed a histological analysis of sun-exposed skin of 19 black and 19 white women [51]. He reported dramatic racial differences in the skin of whites and blacks after long-term sun exposure. Overall, the epidermis of black skin showed only minor changes compared with the profound alterations that occurred in white skin. Histological analysis of the skin of many of the 19 black women analyzed revealed an entirely normal epidermis. In the others, vacuoles and dyskeratosis were present in the keratinocytes of the malpighian layer. These alterations were reported to be similar to those observed in white skin. However, white epidermis showed more dramatic changes, with many focal areas of atrophy and/or necrosis. In contrast, atrophy was observed in only one of the 19 black women ages 22–50, and it was mild in that case. The stratum lucidum in undamaged skin, white or black, consisted of one or two thin layers, and the stratum granulosum rarely exceeded three layers. However, in white skin, on exposure to UV light, the stratum lucidum was distorted. It was swollen, with increased cell layers. In contrast, the stratum lucidum in black skin rarely showed any sign of alteration and remained compact and unaltered.

Montagna's data demonstrated that the entire epidermis of blacks, including the stratum granulosum, lucidum, and corneum, contained melanosomes in both the younger and older age groups. In white skin, only a few melanosomes were seen in the basal layer. Melanophages in black dermis were more numerous and larger than in white dermis. Melanophages were observed to become progressively smaller in the deeper dermis. The melanophages in black skin contained membrane-bound complexes of melanosomes.

Black skin reportedly has a thick and compact dermis with an indistinct intermediated

layer in contrast to the distinct layer in white facial skin. In black dermis, there was close stacking of the collagen bundles, which ran parallel to the surface of the epidermis. Collagen fiber bundles in the dermis were smaller than those found in white skin. In contrast to white skin in which they were sparse, there were many collagen fiber fragments in the dermal interstices.

Elastosis, a hallmark of photoaging in white skin, was not observed in the specimens of any of the black subjects. In contrast, in white skin, variable amounts of moderate-to-extensive elastosis were observed. White skin always had more elastic fibers in the dermis compared with black skin. Dermal changes were observed in the older black subjects. There was an increase in the number and thickness of elastic fibers in the reticular dermis. Elastic fibers, configured in single strands in younger black subjects, appeared in thicker braid-like configurations in 50-year-old subjects. Elaunin fibers in black skin did not form the candelabra-like structures found in white skin but were configured in a parallel or angular array to the epidermis. Oxytalan fibers in older black women were intact in contrast to those of older white women.

Kotrajara studied photodamage and the effect of topical treatment in a population of 61 Asian women of Thai descent. These women, with skin type IV, had a history of substantial UV exposure [47]. Histology revealed epidermal atrophy, atypia, and dysplasia. The keratinocytes in the basal layer of the skin had dense clusters of highly melanized melanosomes. There was an overall increase in melanin in the keratinocytes. Many large, pigment-laden melanophages were identified in the dermis, including the reticular dermis, of the majority of the women. Additionally, in the dermis, marked elastosis presenting as twisted fibers in various stages of amorphous degeneration were noted. Elastotic tissue almost completely replaced the collagen network.

### 3.4.1 The Pigmentary System in Photoaged Skin

The aging process, both intrinsic and extrinsic, produces a variety of responses by melanocytes. These processes are both inhibitory and stimulatory. It has been established that the number of dopa-positive melanocytes decreases with age by approximately 10–20% per decade [52, 53]. The decrease in melanocyte number occurs in both sun-exposed and sun-protected areas of the skin. This, along with a loss in the skin's vasculature, would explain the pale appearance of intrinsically aged skin. However, with long-term sun exposure, the density of melanocytes increases and is approximately two-fold higher than in sun-protected skin [25]. The molecular events underlying the action of UV radiation on melanocytes are largely unknown [38]. In vitro, multiple exposures to UV radiation inhibit melanocyte growth [54, 55]. Melanocytes irradiated with UVB are known to be blocked in the G<sub>1</sub> phase of replication. However, the situation in vivo is different. After UV exposure, melanocyte density increases, as demonstrated by Quevedo. In his study, the number of melanocytes increased when buttock skin was irradiated with UV light [52]. Melanocytes are thus influenced by a number of factors, some of which increase their number and production of melanin. These factors include cytokines and growth factors, which are stimulated with UV exposure and include interleukins 1, 6, and 8, TNF-alpha, TGF-beta, BFGF, growth factor, endothelin derivatives, and nerve growth factor [56, 57, 58, 59]. These cytokines and growth factors have a direct effect on melanocyte proliferation and survival and play a role in the pathogenesis of pigmentary changes of photoaged skin [38]. Additionally, inflammatory mediators formed during UV exposure, such as leukotriene C<sub>4</sub>, stimulate growth of melanocytes and modifications in the normal melanocyte phenotype [60].

Histological features of the pigmentary change associated with photoaging, including mottled hyperpigmentation, ephelides, solar lentigines, seborrheic keratoses, and guttate hypopigmentation, have been investigated. Areas



of mottled hyperpigmentation correlate with an irregular distribution of melanocytes along the basement membrane. Melanocytes display increased dopa-positivity, and there is a heterogeneous distribution of melanosomes within the keratinocytes [39]. Ephelides display hyperpigmentation of the basal cell layer without elongation of the rete ridges. It has been demonstrated by light and electron microscopy that ephelides have fewer melanocytes than adjacent, paler skin [38]. However, the melanocytes of ephelides, which are large and strongly dopa-positive, produce eumelanosomes and hence darker eumelanin whereas in adjacent, paler skin, melanocytes often produce pheomelanosomes and lighter pheomelanin [39].

Solar lentigines, a hallmark of photoaged skin, are characterized histologically by an increase in melanocytes and melanin synthesis. There is hyperpigmentation of the basal cell layer with elongation of the rete ridges. The rete ridges are club shaped or have bud-like extensions [61]. There is an overall increase in the number of melanocytes. Electron microscopic studies demonstrate an increase in the activity of melanocytes, as well. The melanocytes are normal with no cytological atypia, although the nuclei are irregularly shaped [38]. Large numbers of melanosomes are observed in keratinocytes as well as in the stratum corneum. Braun-Falco suggested that in the lentigo, there may be a possible abnormality in the lysosomal degradation of pigment granules within the epidermal keratinocyte [62]. A reticulated black solar lentigo, a black macule with an irregular outline, histologically displays lentiginous hyperplasia with elongation of the rete ridges and hyperpigmentation of the basal layer with skip areas [43]. Melanocytes are not especially numerous, but they show thicker and more prominent dendrites.

Pigmented seborrheic keratoses, another lesion observed in photoaged skin, has variable amounts of melanin pigmentation. Melanocytes are present in the basal layers of seborrheic keratoses and in suprabasal locations. Melanosomes are transferred to epidermal keratinocytes and are found predominantly in the keratosis. Guttate hypomelanosis of aging is characterized histologically with flattening of the der-

mal-epidermal junction and a 10–55% reduction in the number of dopa-positive keratinocytes [37]. Ultrastructurally, the melanosomal content of the epidermal keratinocytes is variable with some containing numerous melanosomes and others containing only immature melanosomes.

### 3.5 Overview of Prevention of Photoaging and Pigmentary Changes of the Skin

It is now well established that UV exposure is the basis of photoaging in all skin types. The pigmentary aspect of photoaging as well as all other manifestations may be prevented by limiting exposure to UV light. This may be achieved through sun avoidance and the use of protective clothing, hats, and sunglasses. The judicious use of sunscreen to block both UVA and UVB is an important preventative measure for photoaging. Thus, the selection of a broad spectrum sunscreen with ingredients that block the action spectrum of UVA (oxybenzone, avobenzone) and UVB (paraaminobenzoic acid, octyl methoxycinnamate, and octyl salicylate) or a physical blocker containing titanium dioxide or zinc oxide is essential.

Antioxidants most likely play a role in prevention of photoaging as well. The mechanism by which this occurs has been demonstrated in vivo by Kang [63]. In the first part of the experiment, UV irradiation was demonstrated to increase the levels of the free radical hydrogen peroxide in the skin. Next, the action of antioxidants on free radicals was evaluated. It was demonstrated that the antioxidants genistein (an isoflavone found in soybeans) and N-acetyl cysteine (NAC) (an amino acid derivative that is converted into the antioxidant glutathione) were not able to block UVB and thus did not have sunscreen properties. Instead, genistein and NAC interrupt the UV signaling cascade in human skin that leads to photoaging. Genistein was found to block the activation of epidermal growth factor-receptor (EGF-R) and the MAP kinase pathway, which leads ultimately to the formation of MMPs and the breakdown of ex-

tracellular matrix components. NAC did not block activation of EGF-R but, instead, increased the levels of reduced glutathione in human skin. UV also stimulates the ERK pathway, and genistein and NAC both inhibited UV induction of ERK activity. As for the other pathway, UV stimulates JNK phosphorylation. NAC did not effect UV induction of JNK phosphorylation, but genistein did block the phosphorylation of JNK. Genistein and NAC inhibited the induction of cJun protein and inhibited the UV induction of collagenase mRNA. Thus, the UV signaling cascade in human skin that leads to photoaging is interrupted by genistein and NAC.

The antioxidants ascorbic acid and alpha-tocopherol are used in a variety of products that claim to prevent photoaging. The effects of three forms of topically applied tocopherol were studied on UV-radiation-induced free radical formation in a mouse model [64]. Tocopherol sorbate was shown to significantly decrease the UV-radiation-induced radical flux in skin. It was also found to be significantly more protective against skin photoaging than alpha-tocopherol and tocopherol acetate. Translation from an animal model to human skin is inferred. Ascorbic acid is also a popular ingredient in anti-aging medications. Topical vitamin C was studied in a porcine skin model [65]. Animals treated with topical ascorbic acid exhibited fewer sunburn cells than did those animals treated with vehicle after exposure to UVA and UVB, and there were decreases in erythema in vitamin-treated areas. It must be noted that an in vitro model does not prove similar results in human skin. In currently available products, there is uncertainty as to the actual amount of antioxidant contained therein and in the stability of the antioxidant. Furthermore, the percutaneous absorption through human skin of the antioxidant is often unknown. Remembering that the theoretical role of the antioxidants is a preventative one, Traikovitch determine the efficacy of topical ascorbic acid in the treatment of mild-to-moderate photodamage in the facial skin of 19 subjects over a 3-month period [66]. He demonstrated a significant improvement in skin surface textural changes after the use of ascorbic acid versus the control group. The

problem with this study is that the mechanism of action of the antioxidant, ascorbate, is in the prevention of photoaging as opposed to the treatment of photoaging. Therefore, it seems unlikely that an antioxidant will treat existing photodamage.

### 3.6 Overview of Treatment of Photoaging and Pigmentary Changes of the Skin

There are three categories of treatment types for photoaging and pigmentary changes:

- Therapeutic modalities to improve pigmentary changes induced by UV light, which can be divided into topical agents and procedural agents
- Topical agents, which include retinoids, hydroquinones, and combination therapies
- Procedural agents, which include chemical peels, microdermabrasion, lasers, intense pulse light, and cryotherapy

There are a myriad of therapeutic modalities that can improve the pigmentary components of photoaging. These modalities may be divided into topical agents and procedural agents. Topical agents include retinoids, hydroquinones, and combination therapies. Procedural agents for the treatment of pigmentary abnormalities include chemical peels, microdermabrasion, lasers, intense pulse light, and cryotherapy. Some of the therapeutic modalities are better suited for certain skin types (Table 3.3). A brief overview of these agents will be provided with an emphasis on published clinical trials that support the efficacy of the particular modality. A more exhaustive review of each modality appears throughout this book.

The leading topical agents for the treatment of photoaged skin, including pigmentary abnormalities, are the retinoids. In double-blind controlled trials, it has been demonstrated that

**Table 3.3.** Treatment of pigmentary characteristics of photoaging in Asian, African American, and Caucasian skin

Treatment modality	Asian	African American	Caucasian
Sunscreen	++	++	++
Antioxidants	++	++	++
Retinoids	++	++	++
Hydroquinones	++	++	++
Chemical peels	+	+	++
Microdermabrasion	++	++	++
Cryotherapy	+	–	++
Laser	+	–	++
Intense pulse light	+	+	+

the three retinoids available in the United States, tretinoin, adapalene, and tazarotene, effectively lighten pigmentary abnormalities associated with photoaging. Weiss demonstrated lightening of lentigines and other hyperpigmented areas on the face and forearms of 30 subjects who applied 0.1% tretinoin cream daily compared with vehicle for 4 months [67]. As an extension of that trial, Ellis demonstrated further improvement in hyperpigmentation as well as the other parameters of photoaging over a 6-month period with topical tretinoin applied daily to the face and forearm [68]. Rafal evaluated the efficacy of topical tretinoin in the treatment of lentigines associated with photoaging [69]. Tretinoin in a 0.1% concentration was applied to the faces of 58 subjects in this 10-month study. Clinical lightening of solar lentigines was noted in 83% of the treated facial lesions compared with 29% of controls. Histological analysis revealed a 35% decrease in epidermal pigmentation in the treated group compared with a 34% increase in the vehicle-treated group. Griffiths examined the efficacy of 0.1% tretinoin cream for 4 weeks in 45 Asians with hyperpigmented lesions on the face and hands [70]. Each subject had at least four lentigines on the face and/or hands. Hyperpigmented lesions were lighter or much lighter in 90% of the patients receiving tretinoin compared with 33% of controls. Histology demonstrated a 41% decrease in epidermal pigmentation in the treated group compared with a 37% increase in the control group. There was a statistically significant correlation between decrease in histologic

epidermal pigment and clinical lightening of the pigmented lesions. In a primarily African American population, Bulengo-Ransby demonstrated improvement in pigmentation with 0.1% topical tretinoin cream. This improvement was not with photoaging-associated pigmentation but with that seen in postinflammatory hyperpigmentation. Fifty-four subjects were treated for 40 weeks with a daily application of 0.1% tretinoin cream [71]. Significant improvement was demonstrated in the tretinoin group, with 91% of that group demonstrating lighter or much lighter pigmentation compared with 57% of the vehicle group. Epidermal melanin content decreased 23% in the tretinoin group compared with 3% of vehicle group.

Adapalene gel in either a 0.1% or 0.3% concentration was used for 9 months in the treatment of both actinic keratoses and solar lentigines in 90 subjects [72]. One month of adapalene use resulted in significant lightening of solar lentigines compared with the control group. At 9 months, nearly 60% of subjects had lightening of the lentigines compared with 36% of the control group.

The efficacy of tazarotene cream at a concentration of 0.1% for the treatment of facial photodamage was evaluated in 563 subjects over an initial 24-week period followed by a 28-week extension [73]. Improvement in pigmentary appearance was the first change to be noted in the tazarotene group, with mottled hyperpigmentation showing a statistically significant improvement over vehicle after 2 weeks of therapy. Lentigines and irregular dyspigmenta-

tion improved over 4 weeks. Pigmentation continued to improve as treatment continued.

Hydroquinones are the mainstay of treatment for most disorders of hyperpigmentation. However, there is a paucity of trials examining the efficacy of hydroquinone in the treatment of photoaged skin, including solar lentigines, mottled hyperpigmentation, and diffuse hyperpigmentation. Clinical studies using hydroquinone for the treatment of various other pigmentary abnormalities have been published. These include studies of postinflammatory hyperpigmentation and melasma. Results applicable to photoaging may be inferred from these trials. Sanchez and Vasquez, among others, demonstrated significant improvement in melasma using 3% hydroquinone in the treatment of 46 women with melasma [74]. Ruiz-Maldonado recommended hydroquinone in the concentration of 2–4% for the treatment of postinflammatory hyperpigmentation for 3 to 6 months [75]. Glenn demonstrated that 6% hydroquinone solution produced a statistically significant lightening in various pigmentary disorders compared with 3% hydroquinone [76]. The pigmentation associated with photoaging requires the application of the hydroquinone twice daily directly to the area of involvement for 3 months.

The efficacy of combination therapy in the treatment of solar lentigines and hyperpigmentation has been reported for the combination of tretinoin/hydroquinone and the combination of 4-hydroxyanisole/tretinoin. Experience with the combination of 5% hydroquinone and tretinoin (0.1–0.4%) was reported by Yoshimura in 136 Asian subjects who applied the combination to face, trunk, and lower extremities for treatment of hyperpigmentation, including lentigines [77]. After 8 weeks, 82% of the patients had a good to excellent result. However, postinflammatory hyperpigmentation was observed in some patients. Fleischer reported the results of the combination of 2% 4-hydroxyanisole and 0.01% tretinoin in the treatment of solar lentigines and related hyperpigmented lesions in two double-blind multicenter trials of 24 weeks' duration [78]. The combination product, a vehicle, and each of the active ingredients individually were applied to

solar lentigines on the forearm, dorsum of the hands, and the face twice daily. The combination product was statistically superior in the lightening of lentigines to each of its active components or vehicle.

Cryotherapy is an often-used procedural modality for the treatment of pigmentation in photoaged skin, particularly for lentigines. The mechanism of action of cryotherapy is the destruction of melanocytes on exposure to cold temperatures. Cold temperatures may be obtained through the use of liquid nitrogen or, less commonly, carbon dioxide or nitrous oxide, which are applied to the skin via direct contact or with a spray device. Two studies support the efficacy of cryotherapy in the treatment of solar lentigines. Almond-Roesler reported the successful treatment of solar lentigines by brief, gentle cryosurgery using a Kryomed device in 20 patients [79]. Lentigines on the hands of 80–100% of the subjects demonstrated lightening. Zouboulis reported resolution of lentigines in 6 subjects treated with nitrous oxide [80]. In addition to the destruction of melanocytes comprising the lentigo, adjacent and subadjacent melanocytes may be destroyed or injured, resulting in lesional and/or perilesional depigmentation, hypopigmentation, or hyperpigmentation. In a study using liquid nitrogen cryotherapy to lentigines on the dorsum of the hands in ten subjects, 50% of the treatment group experienced hypopigmentation at 6 months posttreatment [81]. Therefore, given the unpredictability of the response with cryotherapy, this modality is limited to the treatment of solar lentigines in lightly pigmented individuals.

Laser selection and techniques and intense pulse light for treatment of photoaging is discussed extensively in Chap. 3. Briefly, many lasers have the capability of treating pigmentation associated with photoaging but not in all skin types. The superficially located melanin pigment in solar lentigines lends them to treatment with the rapid-firing Q-switched lasers, including the Q-switched ruby, alexandrite, and Nd:YAG. Inappropriate destruction of melanocytes remains a potential problem for darker skin types. Therefore, laser therapy is infrequently used in darker skin types. Kopera re-

ported the fading of 196 solar lentigines in eight women after treatment with the Q-switched ruby laser [82]. One treatment resulted in lesion improvement without adverse results. Rosenbach treated 21 lentigines in 11 patients with the Q-switched alexandrite laser [83]. Sixteen lesions had a good, excellent, or complete response. In that study, patients with skin types IV were included, and no hypopigmentation or hyperpigmentation was reported. Chan reported treating 34 Asian patients with solar lentigines with three types of Nd:YAG 532 lasers: the Versapulse Q-switched Nd:YAG 532, the Versapulse longpulse Nd:YAG 532 nm, and a conventional Q-switched Nd:YAG 532 [84]. Improvement in the lentigines was graded on a 10-point scale and ranged from 4.50–4.78. A range of adverse events occurred with all three lasers, including hyperpigmentation, hypopigmentation, and erythema. However, the adverse events were most pronounced with the Versapulse Q-switched Nd:YAG 532. The resurfacing lasers, the CO<sub>2</sub> and Er:YAG, will treat both wrinkles and pigmentary changes associated with photoaging. Again, they are not appropriate for darker skin types given the risks of post-inflammatory hyperpigmentation.

Intense pulse light has been utilized for the treatment of lentigines and vascular lesions associated with photoaging. The experience of intense pulse light in the treatment of photoaging in Asian skin has been reported by Negishi, who determined the effectiveness of photorejuvenation for Asian skin types IV-V using intense pulse light [85]. Ninety-seven patients received three to six treatments using 550 nm and 570 nm cutoff filters. A rating of good or excellent was given to more than 90% of patients for pigmentation. No long-term adverse events were reported. Kawada examined the efficacy of intense pulse light in the treatment of lentigines in Asian subjects [86]. Forty percent of those patients with lentigines demonstrated a 50% improvement with treatment.

Superficial exfoliation of the upper layer of the skin is a strategy used to treat pigmentary disorders of photoaging. This is achieved with either microdermabrasion or chemical peeling agents. Cotellessa examined the efficacy of treatment with microdermabrasion of lenti-

gines on the faces of 20 subjects [87]. Forty percent had complete remission, 50% partial remission, and 10% no response after a total of eight treatments administered every 2 weeks. The addition of trichloroacetic acid to microdermabrasion did not substantially improve the results in that study.

Superficial, medium, and deep chemical peels may be employed for the treatment of pigmentary abnormalities associated with photoaging. The specific agents used include glycolic acid (35–70%), salicylic acid (20–30%), trichloroacetic acid (10–25%), and combination peels, including Jessner's solution (14% salicylic acid, 14% lactic acid, 14% resorcinol in 95% alcohol) and trichloroacetic acid, glycolic acid and trichloroacetic acid, and CO<sub>2</sub> and trichloroacetic acid. Lugo-Janer treated lentigines on the hands of 25 subjects with 30% trichloroacetic acid [88]. An improvement of 50% or more was reported in 47% in the trichloroacetic acid treated group. Improved efficacy was noted with the addition of liquid nitrogen cryotherapy with 71% of subjects displaying 50% improvement. Improved efficacy was reported in lighter skin types than darker skin types. Similarly, a study by Li demonstrated improvement in lentigines after treatment with 35% trichloroacetic acid [89].

### 3.7 Summary

Photoaging induced by repeated exposures to UV light produces dramatic changes in the skin. These changes include fine and coarse wrinkling, precancerous and cancerous growths, and pigmentary alterations, to name just a few. Pigmentary alterations are a major component of photoaged skin in all skin types. However, there is variability in the severity and manifestations of photoaging between Asians, African Americans, and Caucasians due to epidermal melanin content and melanosomal distribution. The pigmentary alterations most commonly associated with photoaged skin are mottled, focal, and confluent hyperpigmentation; ephelides; lentigines; pigmented seborrheic keratoses; and dermatosis papulosa nigra. Advances in invasive and noninvasive ther-



apeutic modalities for the treatment of photoaging have lead to the burgeoning field of cosmetic dermatology.

## References

1. Yaar M, Gilchrist BA (2001) Ageing and photoaging of keratinocytes and melanocytes. *Clin Exp Dermatol* 26: 583–591
2. Ortonne JP (1990) Pigmentary changes of the ageing skin. *Br J Dermatol* 122(Suppl): 21–28
3. Kaidbey KH, Agin PP, Sayre RM, Kligman AM (1979) Photoprotection by melanin: a comparison of black and Caucasian skin *J Am Acad Dermatol* 1: 249–260
4. Jazwinski SM (2000) Aging and longevity genes. *Acta Biochim Pol* 47(2): 269–279
5. Barzilai N (2001) Searching for human longevity genes: the future history of gerontology in the post-genomic era. *J Gerontol A Biol Sci Med Sci* 56(2): M83–M87
6. Yu CE, Oshima J, Wijsman EM, Hisama F, Alisch R (1996) Positional cloning of the Werner's syndrome gene. *Science* 272: 258–262
7. Ly DH, Lockhart DJ, Lerner RA, Schultz PG (2000) Mitotic misregulation and human aging. *Science* 287: 2486–2491
8. Blackburn EH (1991) Structure and function of telomeres. *Nature* 350: 569–573
9. Harley B, Futcher AB, Greider CW (1990) Telomeres shorten during ageing of human fibroblasts. *Nature* 345: 458–460
10. Schulz VP, Zakian VA, Ogburn CE, McKay J, Jarzbowicz AA, Edland SD, Martin GM (1996) Accelerated loss of telomeric repeats may not explain accelerated replicative decline or Werner's syndrome cells. *Hum Genet* 97: 750–754
11. Greider CW, Blackburn EH (1985) Identification of a specific telomere terminal transferase activity in Tetrahymena extracts. *Cell* 43 (Suppl 2): 405–413
12. Griffith JD, Comeau L, Rosenfield S, Stansel RM, Bianchi A, Moss H, de Lange T (1999) Mammalian telomeres end in a large duplex loop. *Cell* 97: 503–514
13. deLange T (2002) Protection of mammalian telomeres. *Oncogene* 21: 532–540
14. Karlseder J, Broccoli D, Dai Y, Hardy S, deLange T (1999) p53 and ATM dependent apoptosis induced by telomeres lacking TRF2. *Science* 283: 1321–1325
15. Pescott JC, Blackburn EH (1999) Telomerase: Dr. Jekyll or Mr. Hyde. *Curr Opin Genet Dev* 9: 368–373
16. Bodnar AG, Ouellette M, Frolkis M, Holt SE, Chiu CP, Morin GB, Harley CB, Shay JW, Lechtsteiner S, Wright WE (1998) Extension of life-span by introduction of telomerase into normal human cells. *Science* 279: 349–352
17. Eller MS, Puri N, Hadshiew IM, Venna SS, Gilchrist BA (2002) Induction of apoptosis by telomere 3' overhang-specific DNA. *Exp Cell Res* 276: 185–193
18. Harman D (1956) Aging: a theory based on free radical and radiation chemistry. *J Gerontol* 11: 298–300
19. Fridovich I (1989) Superoxide dismutases. An adaptation to a paramagnetic gas. *J Biol Chem* 264: 7761–7764
20. Gilchrist BA (2003) Skin Aging 2003: Recent advances and current concepts. *Cutis* 72 (Suppl 3): 5–10
21. Fisher GJ, Wang ZQ, Datta SC, Varani J, Kang S, Voorhees JJ (1997) Pathophysiology of premature skin aging induced by ultraviolet light. *N Engl J Med* 337: 1419–1428
22. Kang S, Chung JH, Lee JH, Fisher GJ, Wan YS, Duell EA, Voorhees JJ (2003) Topical N-acetyl cysteine and genistein prevent ultraviolet-light-induced signaling that leads to photoaging in human skin in vivo. *J Invest Dermatol* 120: 835–841
23. Yaar M, Gilchrist BA (1999) Aging of skin. In: Freedberg IM, Eisen AZ, Wolff K, Austen KE, Goldsmith LA, Katz SI, Fitzpatrick TB (eds) *Dermatology in general medicine*. McGraw-Hill, New York, pp 1697–1706
24. deRigal J, Escoffier C, Querleux B, Faivre B, Agache P, Leveque JL (1989) Assessment of aging of the human skin by in vivo ultrasonic imaging. *J Invest Dermatol* 93: 621–625
25. Gilchrist BA, Blog FB, Szabo G (1979) Effects of aging and chronic sun exposure on melanocytes in human skin. *J Invest Dermatol* 73: 141–143
26. Goh SH (1990) The treatment of visible signs of senescence: the Asian experience. *Br J Dermatol* 122: 105–109
27. Chung JH, Lee SH, Youn CS, Park BJ, Kim KH, Park KC, Cho KH, Eun HC (2001) Cutaneous photodamage in Koreans. *Arch Dermatol* 137: 1043–1051
28. Kwon OS, Hwang EJ, Bae JH, Park HE, Lee JC, Youn JI, Chung JH (2003) Seborrheic keratosis in the Korean males: causative role of sunlight. *Photodermatol Photoimmunol Photomed* 19: 73–80
29. Kaidbey KH, Agin PP, Sayre RM, Kligman AM (1979) Photoprotection by melanin: a comparison of black and Caucasian skin. *J Am Acad Dermatol* 1: 249–260
30. Halder RM, Grimes PE, McLaurin CI, Kress MA, Kenney JA (1983) Incidence of common dermatoses in a predominantly black dermatology practice. *Cutis* 133: 1296–1299
31. Halder RM (1998) The role of retinoids in the management of cutaneous conditions in blacks. *J Am Acad Dermatol* 39: S98–S103
32. Montagna W, Carlisle K (1991) The architecture of black and white facial skin. *J Am Acad Dermatol* 24: 929–937
33. Taylor SC, DeYampert NM (2004) Treatment of Photoaging in African American and Hispanic Patients. In: Rigel DS, Weiss RA, Lim HW, Dover JS (eds) *Photoaging*. Marcel Dekker, New York, pp 365–377
34. Moyal D, Fourtanier A (2004) Acute and chronic effects of UV on skin. In: Rigel DS, Weiss RA, Lim HW, Dover JS (eds) *Photoaging*. Marcel Dekker, New York, pp 15–32



35. Cummings K, Cottel W (1966) Idiopathic guttate hypomelanosis. *Arch Dermatol* 93:184-186
36. Warren R, Gartstein V, Kligman AM, Montagna W, Allendorf RA, Ridder GM (1991) Age, sunlight, and facial skin: A histologic and quantitative study. *J Am Acad Dermatol* 25:751-760
37. Ortonne JP (1990) Pigmentary changes of the ageing skin. *Br J Dermatol* 122:21-28
38. Castanet J, Ortonne J-P (1997) Pigmentary changes in aged and photoaged skin. *Arch Dermatol* 133:1296-299
39. Breathmach AS, Nazzaro-Porro M, Passi S, Picardo M (1991) Ultrastructure of melanocytes in chronically sun-exposed skin of elderly subjects. *Pigment Cell Res* 4:71-79
40. Garbe C, Buttner P, Weiss J, Soyerf HP, Stocker U, Kruger S, Roser M, Weckbecker J, Panizzon R, Bahmer F (1994) Associated factors in the prevalence of more than 50 common melanocytic nevi, atypical melanocytic nevi and actinic lentiginoses: multicenter case-control study of the Central Malignant Melanoma Registry of the German Dermatological Society. *J Invest Dermatol* 102:700-705
41. Holzle E (1992) Pigmented lesions as a sign of photodamage. *Br J Dermatol* 127 (Suppl 41):48-50
42. Adhoute H, Grossman R, Cordier M, Soler B (1994) Chromametric quantification pigmentary changes in the solar lentigo after sunlight exposure. *Photodermatol Photoimmunol Photomed* 10:93-96
43. Bologna JL (1992) Reticulated black solar lentigo ('ink spot' lentigo). *Arch Dermatol* 128:934-940
44. Cummings K, Cottel W (1966) Idiopathic guttate hypomelanosis. *Arch Dermatol* 93:184-186
45. Montagna W, Kirchner S, Carlisle K (1989) Histology of sun-damaged human skin. *J Am Acad Dermatol* 21:907-18
46. Warren R, Gartstein V, Kligman AM, Montagna W, Allendorf RA, Ridder GM (1991) Age, sunlight, and facial skin: A histologic and quantitative study. *J Am Acad Dermatol* 25:751-760
47. Kotrajaras R, Kligman AM (1993) The effect of topical tretinoin on photodamaged facial skin: the Thai experience. *Br J Dermatol* 129:302-309
48. Toyoda M, Bhawan J (1995) Electron-microscopic observations of cutaneous photoaging versus intrinsic aging. *J Geriatr Dermatol* 3(5):131-143
49. Shuster S, Black MM, McVitie E (1975) The influence of age and sex on skin thickness, skin collagen and density. *Br J Dermatol* 93:639-643
50. Burke EM, Horton WE, Pearson JD, Crow MT, Martin GR (1994) Altered transcriptional regulation of human interstitial collagenase in cultured skin fibroblasts from older donors. *Exp Gerontol* 29:37-53
51. Montagna W, Carlisle K (1991) The architecture of black and white facial skin. *J Am Acad Dermatol* 24:929-937
52. Quevedo WC, Szabo G, Verks J (1969) Influence of age and UV on the population of dopa-positive melanocytes in human skin. *J Invest Dermatol* 52:287-290
53. Snell RS, Bischoff PG (1963) The melanocytes and melanin in human abdominal wall skin: a survey made at different ages in both sexes and during pregnancy. *J Anat* 97:361-376
54. Friedmann PS, Gilchrist BA (1987) Ultraviolet radiation directly induces pigment production by cultured human melanocytes. *J Cell Physiol* 133:88-94
55. Barker D, Dixon K, Medrano EE, Smalara D, Im S, Mitchell D, Babcock G, Abdel-Malek ZA (1995) Comparison of the responses of human melanocytes with melanin contents to ultraviolet B irradiation. *Cancer Res* 55:4041-4046
56. Mckenzie RC, Park ES, Brown WR, Shivji GS, Sauder DN (1994) Effect of ultraviolet-inducible cytokines on melanoma growth in vivo: stimulation of melanoma growth by interleukin-1 and -6. *Photodermatol Photoimmunol Photomed* 10:74-79
57. Halaban R, Langdon R, Birchall N, Cuono C, Baird A, Scott G, Moellmann G, McGuire J (1988) Basic fibroblast growth factor from human keratinocytes is a natural mitogen for melanocytes. *J Cell Biol* 107:1611-1619
58. Yada Y, Higuchi K, Imokawa G (1991) Effects of endothelins on signal transduction and proliferation in human melanocytes. *J Biol Chem* 266:18352-18357
59. Imokawa G, Yada Y, Miyagishi M (1992) Endothelins secreted from human keratinocytes are intrinsic mitogens for human melanocytes. *J Biol Chem* 267:24675-24680
60. Medrano EE, Farooqui JZ, Boissy RE, Boissy YL, Akadiri B, Nordlund JJ (1993) Chronic growth stimulation of human adult melanocytes by inflammatory mediators in vitro: implications for nevus formation and initial steps in melanocyte oncogenesis. *Proc Natl Acad Sci USA* 90:1790-1794
61. Hodgson F (1963) Senile lentigo. *Arch Dermatol* 87:197-207
62. Braun-Falco O, Schoefinius HH (1971) Lentigo seniles. *Hautarzt* 22:277-283
63. Kang S, Chung JH, Lee JH, Fisher GJ, Wan YS, Duell EA, Voorhees JJ (2003) Topical N-Acetyl cysteine and genistein prevent ultraviolet-light-induced signaling that leads to photoaging in human skin in vivo. *J Invest Dermatol* 120:835-841
64. Jurkiewicz BA, Bissett DL, Buettner GR (1995) Effect of topically applied tocopherol on ultraviolet radiation-mediated free radical damage in skin. *J Invest Dermatol* 104:484-488
65. Darr D, Combs S, Dunston S, Manning T, Pinnell S (1992) Topical vitamin C protects porcine skin from ultraviolet radiation-induced damage. *Br J Dermatol* 127:247
66. Traikovich SS (1999) Use of topical ascorbic acid and its effect on photodamaged skin topography. *Arch Otolaryngol Head Neck Surg* 125:1091-1098
67. Weiss JS, Ellis CN, Headington JT, Tincoff T, Hamilton TA, Voorhees JJ (1988) Topical tretinoin improves photoaged skin: A double-blind vehicle-controlled study. *JAMA* 259:527-532

68. Ellis CN, Weiss JS, Hamilton TA, Headington JT, Zeligson AS, Voorhees JJ (1990) Sustained improvement with prolonged topical tretinoin (retinoic acid) for photoaged skin. *J Am Acad Dermatol* 23: 629–637
69. Rafal ES, Griffiths CE, Ditre CM, Finkel LJ, Hamilton TA, Ellis CN, Voorhees JJ (1992) Topical tretinoin treatment for liver spots associated with photodamage. *NEJM* 326: 368–374
70. Griffiths CE, Goldfarb MT, Finkel LJ, Roulia V, Bonawitz M, Hamilton TA, Ellis CN, Voorhees JJ (1994) Topical tretinoin (retinoic acid) treatment of hyperpigmented lesions associated with photoaging in Chinese and Japanese patients: A vehicle-controlled trial. *J Am Acad Dermatol* 30: 76–84
71. Bulengo-Ransby SM, Griffiths CE, Kimbrough-Green CK, Finkel LJ, Hamilton TA, Ellis CN, Voorhees JJ (1993) Topical Tretinoin (retinoic acid) therapy for hyperpigmented lesions caused by inflammation of the skin in black patients. *New Engl J Med* 328: 1438–1443
72. Kang S, Goldfarb MT, Weiss JS, Metz RD, Hamilton TA, Voorhees JJ, Griffiths CEM (2003) Assessment of adapalene gel for the treatment of actinic keratoses and lentigines: a randomized trial. *J Am Acad Dermatol* 49: 83–90
73. Phillips TJ, Gottlieb AB, Leyden JJ, Lowe NJ, Lew-Kaya DA, Sefton J, Walker PS, Gibson JR (2002) Efficacy of 0.1% tazarotene cream for the treatment of photodamage. *Arch Dermatol* 138: 1486–1493
74. Sanchez JL, Vasquez M (1982) A hydroquinone solution in the treatment of melasma. *Int J Dermatol* 21: 55–58
75. Ruiz-Maldonado R, Orozco-Covarrubias M, de la Luz (1997) Post inflammatory Hypopigmentation and hyperpigmentation. *Semin Cutan Med Surg* 16: 36–43
76. Glenn M, Grimes PE, Pitt E, Chalet M, Kelley AP (1991) Evaluation of clinical and light microscopic effects of various concentrations of hydroquinone. *Clin Res* 39: 83A
77. Yoshimura K, Aoyama T, Iga T (2000) Experience with a strong bleaching treatment for skin hyperpigmentation in Orientals. *Plast Reconstr Surg* 105: 1097
78. Fleischer AB, Schwartzel EH, Colby SI, Altman DJ, and the Depigmenting solution study group (2000) The combination of 2% 4-hydroxyanisole (Mequinol) and 0.01% tretinoin is effective in improving the appearance of solar lentigines and related hyperpigmented lesions in two double-blind Multi-center clinical studies. *J Am Acad Dermatol* 42: 459–467
79. Almond-Roesler B, Zouboulis CH (2000) Successful treatment of solar lentigines by brief gentle cryosurgery using a Kryomed device. *Br J Dermatol* 143: 216–218
80. Zouboulis ChC, Rosenberger AD, Adler Y, Orfanos CE (1999) Treatment of solar lentigo with cryosurgery. *Acta Derm Venereol* 79: 489–490
81. Hexel DM, Mazzuco R, Bohn J, Borges J, Gobbato DO (2000) Clinical comparative study between cryotherapy and local dermabrasion for the treatment of solar lentigo on the back of hands. *Dermatol Surg* 26: 247–462
82. Kopera D, Hohenleutner U, Landthaler M (1997) Quality-switched ruby laser treatment of solar lentigines and Becker's nevus: a histopathological and immunohistochemical study. *Dermatology* 194: 338–343
83. Rosenbach A (2002) Treatment of medium-brown solar lentigines using an alexandrite laser designed for hair reduction. *Arch Dermatol* 138: 547–548
84. Chan HH (2004) Treatment of Photoaging in Asian Skin. In: Rigel DS, Weiss RA, Lim HW, Dover JS (eds) *Photoaging*. Marcel Dekker, New York, pp 343–364
85. Negishi K, Tezuka Y, Kushidata N, Wakamatsu S (2001) Photorejuvenation for Asian skin by intense pulsed light. *Dermatol Surg* 27: 627–632
86. Kawada A, Shiraish H, Asai M, Kameyama H, Sangen Y, Aragene Y, Tezuka T (2002) Clinical improvement of solar lentigines and ephelides with an intense pulsed light source. *Dermatol Surg* 28: 504–505
87. Cotellessa C, Peris K, Fargnoli MC, Mordenti C, Giacomello RS, Chimeti S (2003) Microabrasion versus microabrasion followed by 15% trichloroacetic acid for treatment of cutaneous hyperpigmentation in adult females. *Dermatol Surg* 29: 352–356
88. Lugo-Janer A, Lugo-Somolinos A, Sanchez JL (2003) Comparison of trichloroacetic acid solution and cryosurgery in the treatment of solar lentigines. *Int J Dermatol* 42: 829–831
89. Li Y-T, Yang K-C (1999) Comparison of the frequency-doubled Q-switched Nd:YAG laser and 35% trichloroacetic acid for the treatment of face lentigines. *Dermatol Surg* 25(3): 202–204

# Chemexfoliation and Superficial Skin Resurfacing

Paula E. Bourelly, Angela J. Lotsikas-Baggili

## Core Messages

- Superficial chemical peeling produces a controlled injury to the epidermis. Downtime and complications are minimal, and it is found to be suitable for any skin type.
- Medium-depth chemical peeling induces damage to the papillary dermis, thus the preprocedure regimen is essential to avoid postpeel pigmentary alterations.
- Deep chemical peeling penetrates deeper into the dermis and consequently has a higher risk of postoperative complications and downtime in all skin types.
- The latest technology used to potentiate rapid epidermal exfoliation in all skin types is microdermabrasion, a process involving superficial abrading of the skin with fine, sharp crystals with a vacuum closed-loop suction device to remove the crystals.

4.2.4.2	Application of the Wounding Agent . . . . .	58
4.2.4.3	Postprocedure Management . . . . .	59
4.2.5	Adverse Effects . . . . .	59
4.2.6	Outcome . . . . .	59
4.2.7	Ethnic Skin Considerations . . . . .	59
4.3	<b>Glycolic Acid Peels</b> . . . . .	60
4.4	<b>Salicylic Acid Peels</b> . . . . .	61
4.5	<b>Jessner’s Peel</b> . . . . .	64
4.6	<b>Trichloroacetic Acid 10–30%</b> . . . . .	65
4.7	<b>Solid Carbon Dioxide</b> . . . . .	66
4.8	<b>Medium-Depth Chemical Peeling</b> . . . . .	66
4.8.1	Scientific Background . . . . .	66
4.8.2	Indications . . . . .	67
4.8.3	Patient Selection . . . . .	67
4.8.4	Treatment and Clinical Management . . . . .	68
4.8.4.1	Preprocedure Rejuvenation Regimen . . . . .	68
4.8.4.2	Application of the Wounding Agent . . . . .	68
4.8.4.3	Postpeel Management . . . . .	69
4.8.5	Adverse Effects . . . . .	70
4.8.6	Outcome . . . . .	71
4.8.7	Ethnic Skin Considerations . . . . .	72
4.9	<b>Deep Chemical Peeling</b> . . . . .	72
4.9.1	Scientific Background . . . . .	72
4.9.2	Indications . . . . .	73
4.9.3	Patient Selection . . . . .	73
4.9.4	Treatment and Clinical Management . . . . .	74
4.9.4.1	Preprocedure Rejuvenation Regimen . . . . .	74
4.9.4.2	Application of the Wounding Agent . . . . .	74
4.9.4.3	Postprocedure Management . . . . .	74
4.9.5	Adverse Effects . . . . .	75
4.9.6	Outcome . . . . .	76
4.10	<b>Microdermabrasion</b> . . . . .	76
4.10.1	Scientific Background . . . . .	76
4.10.2	Indications . . . . .	77
4.10.3	Patient Selection . . . . .	77
4.10.4	Treatment and Clinical Management . . . . .	77
4.10.5	Adverse Effects . . . . .	78
4.10.6	Outcome . . . . .	78
	<b>References</b> . . . . .	80

## Contents

4.1	<b>Introduction</b> . . . . .	54
4.2	<b>Superficial Chemical Peeling</b> . . . . .	54
4.2.1	Scientific Background . . . . .	54
4.2.2	Indications . . . . .	54
4.2.3	Patient Selection . . . . .	56
4.2.4	Treatment and Clinical Management . . . . .	57
4.2.4.1	Preprocedure Rejuvenation Regimen . . . . .	57

## 4.1 Introduction

Chemical and mechanical skin resurfacing has been utilized by humans to improve the overall appearance and well-being of skin. The first chemical peels date back to the Egyptians who used sour milk baths (lactic acid), various chemicals (e.g., alabaster and salt), and sandpaper in order to attain a smoother skin surface [1]. In 1882, P.G. Unna, a German dermatologist, described the properties of salicylic acid, resorcinol, phenol, and trichloroacetic acid (TCA) and used these chemicals as peeling agents [2]. In 1976, Resnik et al. described the utility of TCA peels in various skin conditions [3]. In the late 1980s and the 1990s,  $\alpha$ -hydroxy acids (AHAs) became available for superficial peeling agents. For nearly 20 years, a newer technique for superficial skin resurfacing, microdermabrasion, has become a key player in the arena of noninvasive anti-aging medicine. Over the last several decades, the science behind resurfacing procedures has expanded, as has the public's increasing demand for cosmetic surgery and skin rejuvenation. To date, chemical peeling and microdermabrasion are among the most common procedures performed in dermatologic offices and are an important component of our armamentarium in the management of both cosmetic and noncosmetic skin conditions.

## 4.2 Superficial Chemical Peeling

- Primary effects on epidermis
- Safe for any skin type
- Minimal downtime and complications

### 4.2.1 Scientific Background

Chemical resurfacing has a long and well-documented history [1]. Since the late 1800s, physicians have been experimenting with various procedures and techniques involving both

chemical and mechanical skin resurfacing. Chemical resurfacing procedures involve the application of a caustic chemical agent to the skin, which produces a controlled, partial-thickness injury, thereby promoting the growth of new skin with improved surface characteristics. Chemical peeling is intended to produce a controlled partial-thickness injury to the skin, destroying varying amounts of epidermis and upper portions of the dermis. A wound-healing response following the injury involves (depending on the depth of injury) (1) removal of actinic keratoses (AK) and lentiginos, (2) epidermal regeneration by epithelial migration from adnexal structures, (3) decrease in solar elastosis, and (4) replacement of new dermal connective tissue [4].

Chemical peels are categorized into superficial, medium-depth, and deep types of wounding (Table 4.1). In this section, the focus will be on superficial peels with a target depth penetration from the stratum corneum through to the superficial papillary dermis (0.06 mm). Superficial chemical peels are divided into two subgroups: very light and light. Examples of very light superficial chemical peels include low-potency concentrations (20–60%) of glycolic acid, alpha-hydroxy acids, 10–20% TCA, tretinoin, Jessner's solution, and salicylic acid. With very light peels, the level of injury is generally limited to the stratum corneum, which creates exfoliation without clinical vesiculation but may also penetrate into the stratum granulosum. With light superficial chemical peels, such as 70% glycolic acid, 25–30% TCA, and solid carbon dioxide (CO<sub>2</sub>) slush, the injury is to the entire epidermis extending down to the basal cell layer or upper papillary dermis, stimulating the regeneration of a new epithelium.

### 4.2.2 Indications

Indications for superficial chemical peeling include fine to mild rhytids, photoaging, actinic and seborrheic keratoses, acne, dyspigmentation in the form of melasma and postinflammatory hyperpigmentation (PIH), and to improve overall textural alterations of the skin (Table 4.2). There are several different chemical

**Table 4.1.** Chemical peel classifications

Chemical peeling agents	Depth of penetration
Glycolic acid 20–50% Salicylic acid 20–30% Resorcinol 20–30% (5–10 min) Jessner's Solution (1–3 coats) Trichloroacetic acid 10% (1 coat) Microdermabrasion (2 passes)	Very superficial/stratum corneum exfoliation
Glycolic acid 50–70% (5–20 min) Jessner's solution (5–10 coats) Resorcinol 50% (30–60 min) Trichloroacetic acid 10–35% (1 coat)	Superficial/epidermal necrosis
Phenol 88% Glycolic Acid 70% (5–30 min) Trichloroacetic acid 35% in combination with: Glycolic acid (50–70%) Solid CO <sub>2</sub> Jessner's solution	Medium-depth/papillary dermal necrosis
Pyruvic acid 40–70% Modified Baker's peel (2 drops croton oil) Baker-Gordon phenol peel	Deep/reticular dermal necrosis

**Table 4.2.** Chemical peel indications

Peel depth	Indications	Contraindications
Superficial	Fine wrinkling, Glogau I Atrophic acne scars, minimal	Active herpes simplex infection Active eczema
	Melasma, epidermal Postinflammatory hyperpigmentation Acne vulgaris Pseudofolliculitis barbae Mottled dyschromia (ethnic skin)	Presence of tan Isotretinoin use within 1 year Skin malignancy
	Medium	As above Deeply pigmented skin (Relative contraindication)
	Mild to moderate photoaging/Glogau II and III Actinic keratoses Melasma, dermal Atrophic acne scars, moderate Pigmentary dyschromias	
	Deep	Severe photodamage, Glogau IV



agents classified under superficial peels, which will be discussed individually. They include glycolic acid (20–70%), salicylic acid, Jessner's solution, solid CO<sub>2</sub>, and TCA (10–35%).

### 4.2.3 Patient Selection

Proper patient selection and assessment of each individual's skin condition is crucial prior to determining if a chemical resurfacing procedure is indicated. The preoperative consultation is important in identifying at-risk patients who are best avoided or who necessitate an extra-cautious approach, as well as selecting patients who are ideal candidates for the resurfacing procedure. At the time of initial consultation, the dermatologist must evaluate the patient for relative contraindications; discuss the indications of the procedure; and assess the patient's goals, expectations, anticipated results, and limitations as well as the potential risks of the procedure. It is crucial that the patient's goals and expectations are realistic prior to selecting the patient for the procedure. The patient must fully understand the potential benefits, limitations, and risks, and an informed consent must be signed prior to performing the surgical procedure.

Several different factors must be assessed to determine if the patient is an appropriate candidate for skin resurfacing. A thorough history and physical examination must be taken during the initial evaluation. The patient's skin type should be evaluated using Fitzpatrick's classification (Table 4.3) measuring pigmentary re-

sponsiveness of the skin to ultraviolet (UV) light, which is most often based on the ethnic background. Skin types I–III are ideal for peeling. Ethnic skin types IV–VI can also be peeled, but the risk of unwanted pigmentary change in the form of hypopigmentation and hyperpigmentation is greater. Regarding skin types IV–VI, it is best to limit peels to superficial and medium-depth and to avoid deep peels in order to reduce the risk for potential side effects. In addition, Glogau's classification of photoaging (Table 4.4) is helpful in assessing sun damage. Superficial peels are indicated for patients with early to moderate photodamage. Past (within the last 6 months) or present use of systemic isotretinoin must be ascertained, since retinoids are known to be associated with a greater risk of scarring after peeling [5]. Patients should be asked about prior resurfacing procedures or cosmetic procedures such as rhytidectomy, coronal brow lift, or blepharoplasty as these procedures can increase the risk of complications following medium-depth and deep resurfacing [6]. An interval of 4–12 weeks is recommended between peeling and procedures involving undermining [7]. Individuals with prior radiation exposure (e.g., history of superficial X-ray treatment for acne) should be examined carefully to evaluate for presence of vellus hairs in order to ensure that there are enough adnexal structures to promote re-epithelialization [8]. Patients, irrespective of their history of recurrent herpes simplex, should be given prophylactic acyclovir, valacyclovir, or famciclovir beginning the day of the procedure and continuing for 3–5 days postprocedure whereas previously, treatment was continued for 10–14 days [9]. Patients with active inflammation as seen in seborrheic, atopic dermatitis, irritant or allergic dermatitis, rosacea, psoriasis, or vitiligo, may be at an increased risk for postoperative complications secondary to alterations in the skin's normal barrier function. Thus, these conditions should be controlled before receiving a superficial peel [10]. Any history of abnormal scar formation, either hypertrophic scar or keloids, creates a greater risk to scar with deep as opposed to medium-depth peeling. In addition, the patient's pregnancy history and medications should be considered,

Table 4.3. Fitzpatrick classification

Skin type	Color	Skin characteristics
I	White	Always burns, never tans
II	White	Usually burns, tans less than average
III	White	Sometimes mild burn, tans about average
IV	White	Rarely burns, tans more than average
V	Brown	Rarely burns, tans profusely
VI	Black	Never burns, deeply pigmented

**Table 4.4.** Glogau's classification of photoaging

Glogau photoaging classification	Skin features
Type I	<p>“No wrinkles”</p> <p>Early photoaging, minimal wrinkles</p> <p>Mild pigmentary changes, no keratoses</p> <p>Younger patient, 20s–30s</p> <p>Minimal or no makeup</p>
Type II	<p>“Wrinkles in motion”</p> <p>Early to moderate photoaging</p> <p>Early senile lentigines visible</p> <p>Keratoses palpable but not visible</p> <p>Parallel smile lines beginning to appear</p> <p>Patient age late 30s or 40s</p> <p>Usually wears some foundation</p>
Type III	<p>“Wrinkles at rest”</p> <p>Advanced photoaging</p> <p>Obvious dyschromia, telangiectasia</p> <p>Visible keratoses</p> <p>Wrinkles even when not moving</p> <p>Always wears heavy foundation</p>
Type IV	<p>“Only wrinkles”</p> <p>Severe photoaging</p> <p>Yellow-gray color of skin</p> <p>Prior skin malignancies</p> <p>Wrinkles throughout, no normal skin</p> <p>Patient age 60s or 70s</p> <p>Can't wear makeup; “cakes and cracks”</p>

especially postmenopausal women on estrogens and women on oral contraceptives, which may sensitize the skin to the sun or produce postinflammatory splotching. Most importantly, the physician must understand the patient's philosophy regarding sun exposure, as patients are expected to avoid sun exposure and must use sunscreens postprocedure to prevent con-

tinuing sun damage. Patients infected with HIV may experience delayed healing or be at risk for secondary infection after peeling. The general health and nutritional status of the patient is also an important consideration, especially for medium-depth and deep chemical peels. Of note, superficial peels are tolerated with little risk in all patients of all skin types regardless of their general state of health.

It is worth mentioning that a postauricular test peel may be useful in select patients to assess their suitability for chemical resurfacing and may be especially helpful in identifying patients at increased risk of postoperative pigmentary dyschromias [11]. Although a favorable test post is reassuring, it does not guarantee a positive outcome following full-face resurfacing.

#### 4.2.4 Treatment and Clinical Management

##### 4.2.4.1 Preprocedure Rejuvenation Regimen

Several different prepeel regimens have been described in the literature. Multiple combinations exist with a few key players such as topical tretinoin, hydroquinone, alpha-hydroxyl acids, kojic acid, and low-potency steroids. It is also important to counsel patients to minimize sun exposure, utilize sun blocks with UVA/UVB protection, and to avoid smoking.

There is evidence that pretreatment with 2–4% hydroquinone twice daily and topical tretinoin (0.05% and 0.1%) or retinoic acid nightly 1 month prior to the peeling reduces dyschromias and promotes faster healing in the immediate postpeel period. The use of tretinoin prior to chemical peeling speeds epidermal healing and enhances the effects of the procedure [12]. These agents act by priming the skin. They help to achieve a more uniform penetration of peeling agents by reducing sebum and thinning the stratum corneum. They also accelerate re-epithelization, reduce wound healing time, and have a lightening effect by en-

hancing dispersion of melanin granules [13]. Hydroquinone blocks the enzyme tyrosinase from developing melanin precursors for the production of new pigment in the epidermis during the healing phase.

Another approach to patients with pigment dyschromias is to start a prepeel regimen that consists of using 4% hydroquinone twice daily 2–4 weeks prior to the peel and to resume using the 4% hydroquinone 2 days postpeel. The combination of the peel and twice-daily application of 4% hydroquinone produced substantial decreases in the intensity of hyperpigmentation and lesional area for both PIH and melasma [14]. Of note, prolonged use of high concentrations of hydroquinone (6–10%) may paradoxically produce ochronosis, especially in patients with Fitzpatrick types V and VI skin.

Combinations of hydroquinone, topical steroids, and tretinoin have also been reported for the treatment of melasma and used in combination with glycolic acid peels in darker-skinned patients [15], the best-known combination being Kligman's formula (tretinoin 0.1%, hydroquinone 5%, and dexamethasone 1% in hydrophilic ointment) used daily [16]. There are other variations of Kligman's formula, which have been adapted using lower concentrations of hydroquinone and lower potency steroids. Additional adjunct to topical therapy include AHAs, which are incorporated into many skin care maintenance regimens. The use of AHA has been shown to reverse histologic signs of photoaging by increasing epidermal thickness, reversing basal cell atypia, dispersing melanin pigmentation, and normalizing the rete pattern of the dermoepidermal junction. There are multiple combinations that can be used, such as 2% hydroquinone/10% glycolic acid gel twice daily and 0.05% tretinoin cream at night. Kojic acid is another topical agent that can be used in the preprocedure rejuvenation regimen. Kojic acid, like hydroquinone, can be combined with chemical peels to utilize its bleaching effects. It is an antibiotic produced by many fungal species such as *Aspergillus* and *Penicillium* in an aerobic process from a wide range of carbon sources [17]. Its mechanism of action is likely due to competitive inhibition of the catecholase activity of tyrosinase [18].

The combinations of prepeel rejuvenation regimens are endless. Many studies have shown that the combination of the prepeel regimens with superficial peels provides additional benefits with minimal adverse effects in patients of all skin types. Typically, the prepeel regimen is begun 2–4 weeks prior to the peel, stopped 2–3 days before the peel, and resumed postoperatively after complete re-epithelialization has occurred.

#### 4.2.4.2 Application of the Wounding Agent

Prior to the application of all peeling solutions, cutaneous lipids, debris, and excess stratum corneum are removed by vigorously cleansing the skin with alcohol or acetone-soaked sponges [19]. Then the area is rinsed with water and dried. Prior to applying the peeling agent, the cleansed skin should be checked for the presence of residual oil and, if needed, the cleansing process repeated. The wounding agent is then applied. Depending on the agent used and the concentration, the amount of time the agent is left on the skin varies, generally between 2–4 min. Frosting with different wounding agents is variable in rate and appearance and depends on the preexisting degree of photodamage, the choice of applicator used, and the adequacy of defatting [7]. Neutralization of the agent is used with either water or sodium bicarbonate. Of note, the effect of AHAs and glycolic acid depends on the contact time on the skin and therefore must be washed off with water or neutralized with 5% sodium bicarbonate after 2–4 min. During this time, patients may experience mild stinging and burning with minimal discomfort; the patient undergoing a superficial peel does not require sedation or general anesthesia. Finally, an emollient is applied to the treated area of skin postprocedure.

The amount of peeling agent applied, the degree of rubbing, and the duration of skin contact must be carefully monitored. The effect of a chemical peel is dependent upon the chemical agent, its concentration, and the techniques employed before and during the application. Each wounding agent has individual chemical

properties and causes a specific pattern of injury to the skin. All superficial wounding agents will be discussed individually.

#### 4.2.4.3 Postprocedure Management

All patients who undergo any type of resurfacing procedure must adhere to strict sun avoidance and sun-protective measures during the postoperative period. In addition, patients should be counseled not to smoke, as smoking impairs the healing process. Patients may resume their prepeel rejuvenation regimen only after complete re-epithelialization has occurred. Typically, the recovery time post superficial peel is minimal.

#### 4.2.5 Adverse Effects

Superficial peels are generally well tolerated. The majority of patients will experience mild stinging and burning during the application of the wounding agent, which is an expected sensation and is not considered a procedural complication. Although the adverse reactions associated with superficial peels are much less than with the deeper peels, the risks are not negligible.

Pigmentary changes in the form of both hypopigmentation and hyperpigmentation are possible complications. The risk of hyperpigmentation is greater in patients with darker skin types. Typically, hypopigmentation resolves within several months after the peel. Hyperpigmentation can be treated effectively with hydroquinone regimens.

Prolonged erythema, milia, pustulocystic acne, reactivation of latent herpes simplex infection, and superficial bacterial infection are all potential complications postpeel [20]. The incidence with superficial peels is significantly less than with deeper peels although not negligible. Patients with a history of herpes should be treated prophylactically with acyclovir, valacyclovir, or famciclovir beginning on the day of the peel and complete a course of 10–14 days at therapeutic doses. Prolonged erythema may be treated with a low-dose topical steroid such as

hydrocortisone or with desonide 0.05% lotion twice daily for 2–3 days. Milia or acne that occurs after the peel may be aggravated by thick ointments applied to the treated area. An irritant reaction due to pooling of the acid in the skin creases (e.g., oral commissures, lateral and medial canthi) are best avoided by applying petrolatum ointment prior to beginning the procedure.

The risk of hypertrophic scarring is less than 1% with superficial peels [7]. The rate of scarring may be increased with a history of recent isotretinoin use or poor patient selection. If hypertrophic scarring does occur, treatments include dilute triamcinolone injections into the scar, topical or tape-impregnated glucocorticoids, silicone gel sheeting, or the 585-nm flashlamp-pumped pulse dye laser [21].

#### 4.2.6 Outcome

Patients who complete a series of treatments with superficial chemical peels experience regeneration of new skin and improvement in their overall complexion and appearance. Of note, the effects on photoaging are very subtle, since superficial peels do not reach the dermis. The benefits to superficial chemical peels are that there are minimal risks as well as no downtime postprocedure. Also, superficial peels, especially glycolic acid and salicylic acid, are well tolerated in patients with darker complexions with minimal side effects since these peels only affect the epidermis and do not penetrate into the dermis.

#### 4.2.7 Ethnic Skin Considerations

When considering using chemical peels in ethnic skin, it is critical to identify the patient's Fitzpatrick skin type as well as determine the patient's ethnicity prior to selecting the peeling agent. Indications for chemical peeling in darker skin include acne vulgaris, PIH, melasma, scarring, photodamage, and pseudofolliculitis barbae. However, the primary indication for chemical peeling in skin types III–VI is for pigmentation dyschromias.

As a dermatologist treating ethnic/darker skinned patients, it is important to understand the different properties of the superficial chemical peeling agents in order to choose the most appropriate agent to address the patient's dermatological needs. For example, glycolic acid and salicylic acid peels are excellent tools to treat acne in skin of color. In addition, salicylic acid in ethanol solutions is a great peeling agent for dark-skinned patients with melasma and PIH whereas glycolic acid is a less favorable agent to treat melasma and PIH because it may induce PIH in skin types V and VI. Trichloroacetic acid at low concentrations of 10–25% works well to treat acne scarring in skin of color, and when used in combination with 70% glycolic gel, it also rejuvenates uneven mottled facial pigmentation. Jessner's solution may create depigmentation in patients with skin types V and VI but may be successful in spot-peeling for PIH in ethnic skin. In addition, TCA 25% and salicylic acid are important tools for spot-peeling for PIH.

Regarding the treatment of melasma with superficial peeling agents, Asian and Asian Americans respond well to serial glycolic peels maintained at the same concentration. Africans and darker African Americans (skin types V and VI) have better results with salicylic acid peels because the risk for PIH is higher with glycolic acid peels. Finally, serial glycolic acid peels and salicylic acid peels have been successful in improving the skin texture in patients with pseudofolliculitis barbae [22].

No matter which superficial agent is chosen in ethnic/dark skin, it is critical to start a pre-peel regimen that includes the morning application of sunscreen with UVA/UVB SPF 30 and a moisturizer containing alpha-hydroxy acid as well as an evening combination including retinoid, hydroquinone, kojic acid, or azelaic acid and possibly at low-potency steroid. The duration of this pre- and postpeel regimen is similar in all skin types.

### 4.3 Glycolic Acid Peels

Glycolic acid is an AHA, which belongs to a class of naturally occurring compounds de-

rived from food sources such as sugar cane [23]. Glycolic acid peels range in concentration from 20–70% glycolic acid. This type of peel is generally performed every 3–4 weeks for a total of four to six treatments. Glycolic acid peels are indicated in the treatment of melasma, postinflammatory hyperpigmentation, mild photoaging (Glogau I and II), and acne. Glycolic acid peels are generally well tolerated by all skin types I–VI. Several studies have shown that up to 70% glycolic acid is well tolerated with minimal adverse effects and has shown improvement in melasma and postinflammatory hyperpigmentation [24, 25]. Glycolic acid peels may be used as monotherapy, combined with a topical preprocedure rejuvenation regimen consisting of tretinoin and hydroquinone, or even combined with 5-fluorouracil (5-FU) known as the fluor-hydroxy pulse peel for the treatment of actinic keratosis with an improved overall cosmesis [26].

Glycolic acid has been shown to cause dis-cohesion of keratinocytes at low concentrations of 20–40% and causes epidermolysis at higher concentrations 50–70% [27]. Very low concentrations of glycolic acid peels cause an injury limited to the stratum corneum and only creates exfoliation, but the injury may extend into the stratum granulosum. The higher potency glycolic acid formulations injure the entire epidermis down to the basal layer. In contrast to beta-hydroxy acid (e.g., salicylic acid), AHAs are lipophobic in nature. A previous study by Moy et al. demonstrated that glycolic acid has a stimulatory effect on collagen production in fibroblasts. This increased collagen stimulation in normal dermal fibroblasts may account for the production of a new zone of collagen in the upper dermis that would replace the elastotic deposits that form from photo-damage [28]. This proposed mechanism may account for the decrease in fine wrinkling, leading to improvement of fine rhytids.

The major factors that determine whether glycolic acid peels result in desquamation or epidermolysis are the concentration of the acid, the pH, the degree of buffering or neutralization with sodium bicarbonate, the vehicle formulation, the frequency of application, the conditions of delivery, the amount of acid delivered



to the skin over a given period, and most importantly, the length of time that the acid remains on the skin [7]. Prior to the application of the wounding agent, the face must be cleansed to remove any preexisting debris and cutaneous lipids with alcohol or acetone-soaked sponges. Then the agent is applied in any cosmetic unit order, covering the face within 20 s (forehead, cheeks, chin, nose, and upper lip) with large cotton swabs, sable brush, or 2" × 2" gauze pads. The time of application is critical for glycolic acid as it must be rinsed off with water or neutralized with 5% sodium bicarbonate 2–4 min after application.

Postprocedure regimen should include the use of sunscreen, avoidance of excessive sun exposure, and the daily application of a moisturizer. The advantage of this superficial peeling agent is that it only causes mild irritancy, and minimal time is needed for recovery. Patients may return to their normal level of daily activities and can wear makeup to conceal erythema. Complications with glycolic peels are very rare.

Treatment of AK with a superficial peel is best approached by combining 5-FU and glycolic acid. A study conducted by Marrero and Katz found that the use of the fluor-hydroxy pulse peel applied in a pulse dose regimen not only provides cosmetic improvement but, more importantly, has a therapeutic effect on ablating premalignant AKs [26]. The ability of AHAs to eradicate AKs is variable and depends on peel depth [29]. 5-FU is an antimetabolite that inhibits DNA and RNA synthesis and destroys hyperproliferative AKs [30]. A major limitation in the use of daily 5-FU topical regimen is severe erythema, local irritation, and discomfort associated with the treatment period of 4–8 weeks [31]. However, it has been shown that weekly pulse dosing of 5-FU is equally efficacious at treating facial AKs as the conventional treatment regimen without the severe side effects [32]. Therefore, the study conducted by Marrero and Katz [26] hypothesized that the use of 5-FU with AHAs (glycolic acid) would work synergistically to improve cosmesis as well as treat AKs. This study found there was a dramatic reduction in the number of AKs, which was sustained at 6 months follow-up after the fluor-

hydroxy pulse peel side of the face, with 92% reduction in AKs versus 20% for the glycolic acid side alone. In addition, there was also a significant cosmetic benefit to the combination peel.

#### 4.4 Salicylic Acid Peels

Salicylic acid (SA) is a beta-hydroxy acid. Salicylic acid is a naturally occurring substance found in the bark of the willow tree. Salicylic acid peels range in concentration from 20–30%, and peels are performed every 3–4 weeks for a total of three to five treatments. Salicylic acid peels are indicated in the treatment of acne vulgaris, melasma, postinflammatory hyperpigmentation (Figs. 4.1, 4.2, 4.3, 4.4), rough/oily skin with enlarged pores, and mild to moderate photodamaged skin (Table 4.2). Salicylic acid peels are safe and efficacious in skin types I–VI [14].

Salicylic acid has been formulated in a hydroethanolic vehicle at concentrations of 20%

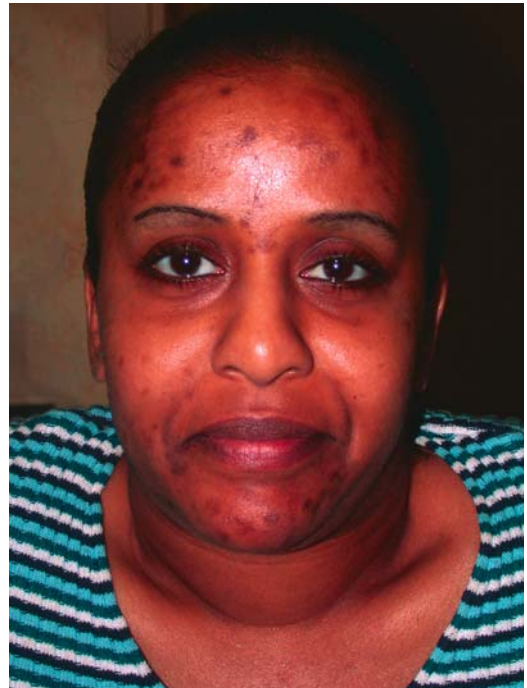

Fig. 4.1. Baseline postinflammatory hyperpigmentation

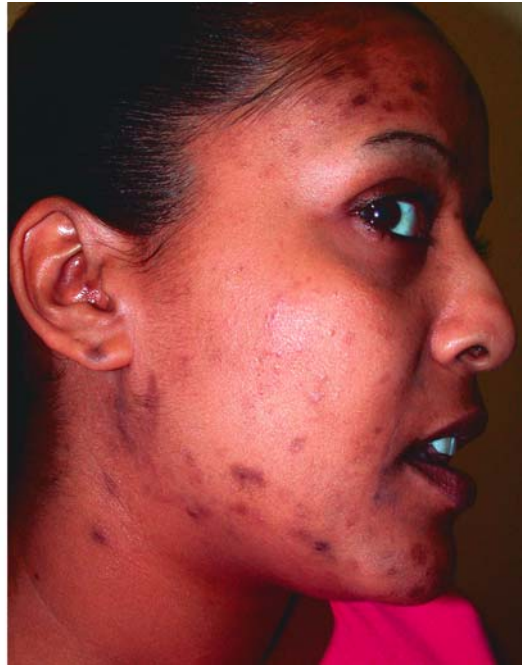
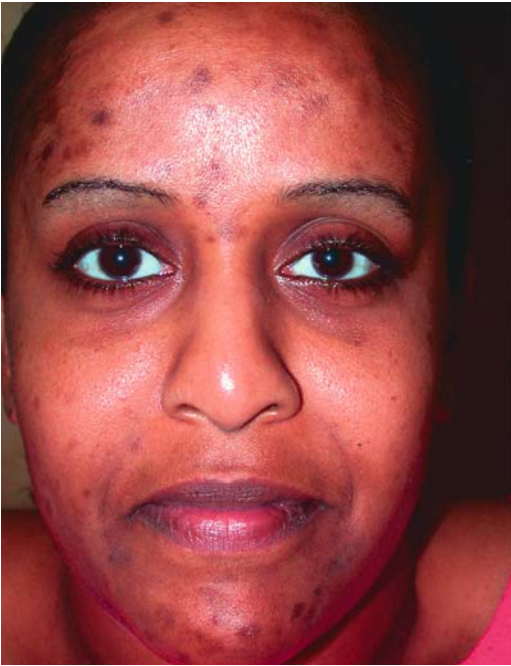
Fig. 4.2. Status post third salicylic acid peel



Fig. 4.3. Status post sixth salicylic acid peel

and 30% for use as a superficial peeling agent [33]. It is a lipophilic agent, which produces desquamation of the upper lipophilic layers of the stratum corneum [14]. Its efficacy for the treatment of acne and photoaging has been well documented in the Fitzpatrick skin types I–III [33, 10] as well as in patients with Fitzpatrick skin types V and VI [14]. Salicylic acid peels are the preferred therapy for comedonal acne as it is lipophilic and concentrates in the pilosebaceous apparatus. It is effective as adjunctive treatment for open and closed comedones and at resolving postacne erythema and hyperpigmentation [34]. Because it is a lipid-soluble comedolytic, salicylic acid acts by decreasing corneocyte cohesion at the follicular opening and assists in comedone plug extrusion [35, 36]. In addition, the salicylic acid peel can be combined with hydroquinone 4% (pre- and post-procedure) to expedite the clearing of hyperpigmented lesions and significantly decrease the occurrence of postpeel hyperpigmentation seen more commonly in skin types V and VI [14].

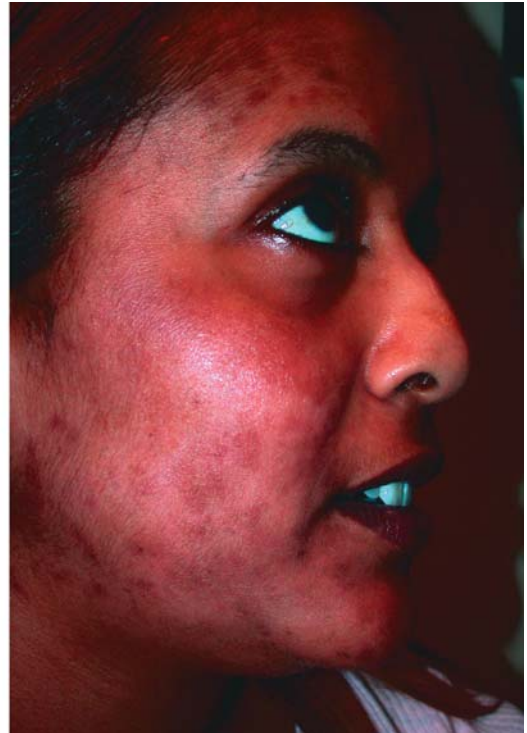

Fig. 4.4. Status post eight salicylic acid peel

As with all superficial peeling agents, prior to applying the wounding agent, the face is cleansed with alcohol- or acetone-soaked sponges. Then the salicylic acid agent (20% or 30% in a hydroethanolic solution) is applied to the face. Patients experience stinging and burning with an intensity that is greater than that of 70% glycolic acid, but this ceases rapidly. The SA peel causes a superficial anesthesia so patients can be reassured that the stinging and burning will cease within a couple of minutes [10]. The agent should be applied to cosmetic units of the face in any order. Uniformity of application is easily observed as a white precipitate of salicylic acid is seen in the areas where the agent has been applied. The agent is applied to the face for 3–4 min. Then the face is washed with water or a mild cleanser. Of note, once the hydroethanolic vehicle has volatilized leaving a white precipitate of salicylic acid on the surface of the skin, there is very little penetration of the active agent. Thus, there is no concern regarding timing or overpeeling.

The majority of patients tolerate this procedure without side effects. Side effects, which are seen, include transient dryness and hyperpigmentation, which resolve within 1–2 weeks; and temporary superficial crusting (Fig. 4.5) and edema, which clear in about 7 days. Salicylism has not been seen as a side effect postpeel since the total amount of SA applied is very small and the majority of the solution is volatilized. In addition, Kligman tested serum levels of subjects after peeling, and the concentrations were far below levels of salicylate toxicity and were below anti-inflammatory levels [10]. Of note, more peeling is seen in areas of prepeel inflammation, e.g., inflammatory acne or seborrheic dermatitis. Peeling usually begins 2 days postpeel and can extend for up to 7 days postpeel. This agent causes significantly more desquamation than glycolic acid peels [10]. The efficacy of salicylic acid peels is directly correlated to the degree of desquamation that is seen postpeel. Postprocedure regimen should include the use of sunscreen,



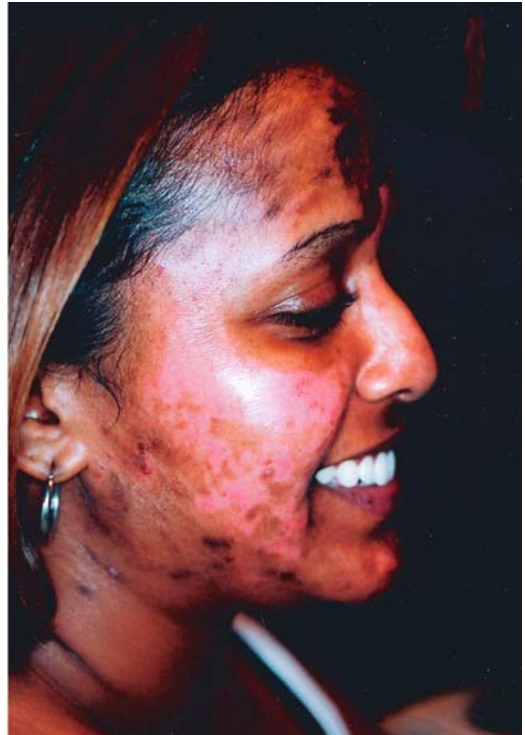
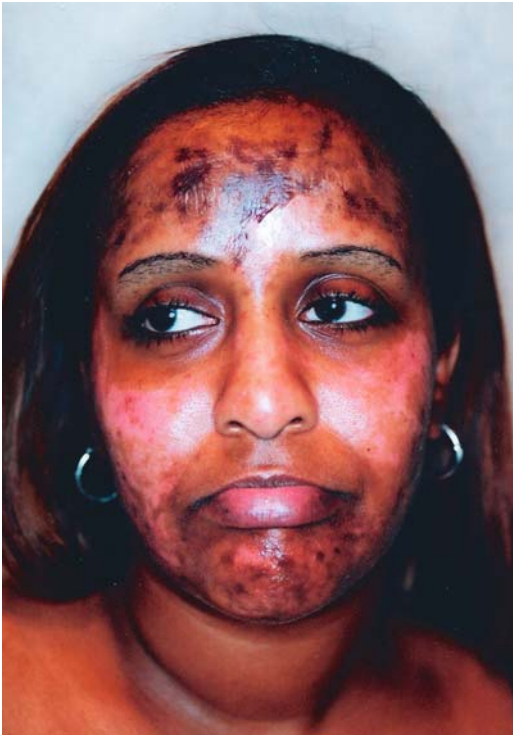
Fig. 4.5. Postoperative day 3 salicylic acid peel with epidermal necrosis

avoidance of excessive sun exposure, and the daily application of a moisturizer.

#### 4.5 Jessner's Peel

Jessner's peel is a solution that combines resorcinol (14 g), salicylic acid (14 g), 85% lactic acid (14 g), and 95% ethanol (q.s.a.d. 100 ml). Jessner's peels are indicated in the treatment of inflammatory and comedonal acne and melasma as well as hyperkeratotic skin disorders. Jessner's solution was formulated to lower the concentration and toxicity of any one agent and to enhance the keratolytic effects. Jessner's solution has intense keratolytic activity, initially causing loss of corneocyte cohesion within the stratum corneum and subsequently creating intercellular and intracellular edema within the upper epidermis if application is continued [37].

Prior to applying the wounding agent, the skin should be degreased with alcohol or acetone. Then Jessner's solution is applied to the skin with 2"×2" gauze or a sable brush, which produces erythema and a very light frost within 15–45 s. The clinical endpoint of treatment is the erythema and blotchy frosting. The depth of penetration of the peeling agent is related to the number of coats applied. The advantages of Jessner's solution are that only a single solution is needed, timing the duration of application is unnecessary, and dilution or "neutralization" is not performed [7]. Jessner's peel can also be combined with 5-FU delivered in a weekly pulse dose regimen, also known as the fluor-hydroxy pulse peel, to treat AKs with an associated improvement in cosmesis. This study showed an 88.14% clearing of AKs [29]. Both studies combining Jessner's solution or glycolic acid with 5-FU showed synergism for the treatment of AKs, with no significant difference between the use of either Jessner's or glycolic acid as adjuvant therapy.

## 4.6 Trichloroacetic Acid 10–30%

TCA produces superficial peeling when used in strengths from 10% to 30% [38]. At these strengths, TCA is indicated for the treatment of fine rhytids, actinic damage, mild epidermal dyschromia, reduction of superficial keratoses, scars, and comedone formation. Treatment intervals between applications of this superficial chemical peeling agent are generally within 7–28 days [7]. As a general rule, repeating the application before the erythema has faded from the previous treatment may enhance penetration of the successive application and produce deeper wounding [39].

TCA precipitates epidermal proteins and causes necrosis and exfoliation of normal and actinically damaged cells. TCA is nontoxic systemically and is neutralized by serum in superficial dermal blood vessels [19]. Partial epidermal exfoliation occurs with 20% TCA; therefore, a series of peels may be necessary in order to optimize the rejuvenating effects of papillary dermal remodeling [40].

Prior to starting the peel, the face is cleansed/degreased with alcohol- or acetone-soaked sponges. Then the TCA agent (10–30%) is applied to the face with short, gentle strokes using only light pressure. Proceeding clockwise or counterclockwise is according to preference, but returning to an already painted area must occur before 2 min have passed to allow the acid to be neutralized before more solution is applied. One or two applications of TCA solution to the entire face produce a transient frost and mild erythema. The depth of penetration of the peeling solution is related to the number of coats applied. Protein precipitation results and leads to exfoliation without vesiculation. TCA is self-neutralizing and does not require water or bicarbonate to terminate the action of peeling. Patients experience a temporary burning and stinging sensations that can be relieved with cool compresses and cool air blown over the skin by an electric fan [41]. Superficial TCA peels are well tolerated by most patients and thus do not require sedation. Of note, topical anesthetics should be avoided because they can increase peel depth by increasing stratum cor-

neum hydration [42]. In the subsequent 24–48 h, the skin turns brown, which is followed by exfoliation by the third to fifth day. Complete re-epithelialization takes place within a week to 10 days. Depending on the desired affects, the patient may undergo a second treatment within a week or two [43].

Postprocedure regimen should include the use of sunscreen, avoidance of excessive sun exposure, and the daily application of a moisturizer. Once the skin is re-epithelialization (postoperative days 7–10), the patient may resume their pre-rejuvenation regimen (such as AHA-containing moisturizers once a day, topical hydroquinone preparations, and tretinoin therapy nightly).

Complications from superficial peeling agents are usually minor and reversible, including transient hyperpigmentation, prolonged erythema (<3 months), colloid milia, acne flares, reactivation of latent facial herpes simplex virus (HSV) infection, and superficial bacterial infection [44]. Scarring in the absence of supervening infection is highly unlikely [43].

One common problem for the physician is discerning the degree of evenness of the application of 10–30% TCA because the frost produced is minimal and transient. To avoid skip areas and to ensure an even application of acid, some manufacturers add sodium fluorescein to the solutions, rendering the preparation visible under a Wood's lamp. This technique helps to detect skip areas and avoids overcoating [45]. Another TCA peel modification is Obagi "blue peel," which contains a nonionic blue color base with glycerin and saponins, which slows the penetration and release of TCA in the skin by reducing the surface tension of the TCA, water, and glycerin. This results in a homogeneous TCA-oil-water solution and provides a gauge to the depth of the peel [46]. A light blue end point signifies exfoliation to the papillary dermis while a medium/dark-blue endpoint denotes coagulation to the immediate upper reticular dermis. The lighter procedure results in skin tightening whereas the deeper procedure results in skin leveling. The minimal recommended waiting period before repeating a blue peel is 6–8 weeks, and two to three blue peels may be required for maximum benefit [42].



## 4.7 Solid Carbon Dioxide

Solid CO<sub>2</sub> (dry ice)/solid CO<sub>2</sub> slush is used for superficial peeling. Solid CO<sub>2</sub> is actually a physical modality for peeling and not a true chemical peeling agent. The dry ice is wrapped in a small hand towel and dipped, as needed, in a solution of approximately 3:1 acetone and alcohol, which serves to facilitate application to the skin [7]. CO<sub>2</sub> ice causes mechanical injury to the epidermis, which results in microvesiculation and disruption of the stratum corneum barrier. It may be used alone (superficial peel) or to amplify TCA as a medium-depth peel [19].

## 4.8 Medium-Depth Chemical Peeling

- Primary effects on papillary dermis
- Combination peels safer than higher concentration TCA
- Prepeel rejuvenation program mandatory, especially in darker skin types

Medium-depth peels by definition are chemical peeling agents used to exert a controlled injury extending to the papillary dermis [47]. The prototypical medium-depth peeling agent, 50% TCA, has fallen into relative disuse because of its high risk of complications. Scarring and postpeel dyschromias are possible sequelae of higher concentrations of TCA due to an unpredictable pattern of absorption and resultant “hot spots”. Many clinicians have abandoned the higher level TCA peels for combination peels using 35% TCA with Jessner’s solution, 70% glycolic acid, or solid CO<sub>2</sub> [47]. Although comparative data is not yet available, pyruvic acid is a new addition to the medium-depth chemical peel armamentarium showing many of the same clinical benefits as the traditional medium-depth peeling agents [48]. The combination peels can achieve the same depth of penetration as the solitary 50% TCA but without the associated risks.

### 4.8.1 Scientific Background

TCA has long since been considered the gold standard of chemical peeling agents. It is a stable agent (shelf life greater than 6 months) that is not light sensitive and requires no refrigeration. TCA crystals are naturally occurring and are mixed with distilled water to form a solution concentration measured by a ratio of weight to volume [49]. By priming the skin with 70% glycolic acid, Jessner’s solution, or solid CO<sub>2</sub>, the cosmetic surgeon can allow for penetration of a lower and safer concentration of TCA (35%) that is deeper and more evenly distributed. The end result is more uniform peeling with fewer complications. Glycolic acid at a concentration of 70% melts away the epidermal barrier by breaking up the individual keratinocytes. Jessner’s solution is composed of 14% lactic acid/14% resorcinol/14 g salicylic acid in 100 ml of ethanol. When applied, this solution destroys the epidermis in a manner similar to that of 70% glycolic acid. Solid CO<sub>2</sub> with acetone, however, creates epidermal necrosis, again enhancing the penetration of the subsequently applied 35% TCA. Following the chemical peel, the process of wound healing is responsible for the smoothing and tightening effect on the skin.

In the immediate postprocedure phase, inflammation and coagulation are present. The inflammatory cells promote bacterial killing, granulation tissue production, and probable fibroblast growth. Within 1 day postpeel, keratinocytes have already begun to migrate from the adnexal epithelia across a fibronectin matrix. In the 10–14 days that follow, re-epithelization is completed, as evidenced by the clinical appearance of an erythematous fresh epidermal layer. Collagen remodeling ensues, a process that may take 3–4 months after a medium-depth chemical peel [47]. Histologic studies taken 3 months following a medium-depth peel demonstrate an increased grenz zone, parallel aggregates of new collagen, mucin deposition, and activated fibroblast [50]. Decreased intracytoplasmic vacuoles and spongiosis have also been seen ultrastructurally [51].

Other less popular chemicals used to achieve a medium-depth peel include pyruvic acid, and a modified Baker-Gordon peel using only one or two drops of croton oil [52]. Pyruvic acid at concentrations of 40–70% is a potent peeling agent. It physiologically converts to lactic acid, and with a pKa of 2.39, this small molecule penetrates down to the upper papillary dermis [48]. Use of this agent has led to increased production of collagen, elastin, and glycoproteins [26]. The depth of penetration of a phenol peel, as a photocoagulant, has an inverse relationship with its concentration. A phenol peel at 88% causes a barrier to be formed by precipitated epidermal proteins, which subsequently protects against deep dermal penetration [45]. At 50%, phenol is a potent keratolytic responsible for deep dermal injury. Additionally, fewer drops of the vesicant croton oil limit the penetration by decreasing the epidermolytic or drying effect.

Obagi et al. emphasize the blue peel, which uses concentrations of 15% and 20% TCA and can be used to achieve a medium-peel depth if a higher volume is used [42]. This suggests that the previous classification of peel depth cannot be determined merely by TCA concentration. One coat of a 15% TCA blue peel is said to exfoliate the stratum corneum while four coats of the same agent can peel down to the papillary dermis. This color-coded peel employs all of the properties of traditional TCA with the addition of an FDA-approved blue dye that allows even the inexperienced physician to accomplish uniform application of the peeling agent. The end points for the blue peel can be gauged by the appearance of the skin following its application. Epidermal penetration (exfoliation) is characterized by an even blue appearance without evidence of a sustained frost. The physician assumes that the papillary dermis has been reached when a frost, described as a “thin, organized, transparent sheet,” becomes visible, with the evidence of the color pink in the background (“the pink sign”). Penetration to the immediate reticular dermis is confirmed when the pink background to the frost lessens or disappears completely, giving way to a solid white sheet. This is the maximum depth recommended for the blue peel on facial skin [42].

## 4.8.2 Indications

Medium-depth chemical peels are best suited for the treatment of superficial epidermal lesions, lentigines, actinic keratosis, pigmentary dyschromias, textural irregularities due to acne scarring, and mild to moderate rhytids associated with photoaging [49]. This level chemical peel is also used as an adjunct to laser resurfacing or deep chemical peels, to blend the lines of demarcation between treated and untreated skin. In patients with more significant periorbital and perioral rhytids, the deeper penetration of laser may be indicated for improvement, but medium-depth peels may be sufficient for the intervening areas of facial skin [53, 54, 55]. Moderate inflammatory acne, acne scarring, AK, warts, and facial skin aging are among the conditions treated successfully by the pyruvic acid peel [48]. Chun et al. utilized the focal application of TCA at concentrations of 10–65% to safely remove or improve benign pigmented lesions, including seborrheic keratoses, lentigines, freckles, and melasma in dark-skinned patients [56]. By combining these therapeutic options, the patient’s healing time and risk of posttreatment morbidity are both reduced [49].

## 4.8.3 Patient Selection

The key to high patient satisfaction and low postoperative complications is appropriate patient selection. Patients with mild to moderate facial rhytids and minimal pigmentary disturbances achieve the best outcomes with medium-depth peels [52]. The Glogau classification system for photoaged skin can be quite useful when deciding the appropriate peel type and depth for a particular patient (Table 4.3). Mild atrophic acne scarring and diffuse AK have been consistently improved with peels of this depth, as well. Traditionally avoided in darker skin types, medium-depth chemical peels are now being safely and successfully performed in these patients with some pre- and posttreatment precautions. Although these agents are applied safely to isolated lesions, full-face, medium-depth chemical peels are still, however,

best avoided in very dark skin types (Fitzpatrick VI) because of the possibility of postpeel hyper- or hypopigmentation.

#### 4.8.4 Treatment and Clinical Management

##### 4.8.4.1 Preprocedure Rejuvenation Regimen

Retinoic acid, hydroquinone, glycolic acid, or lactic acid and sunscreens are among the products used in the pre- and posttreatment phase of medium-depth chemical peels. Their effects on corneocyte adhesion, the stratum corneum and melanin production help ensure even absorption of the peel and reduce postoperative hyperpigmentation. In addition, the use of oral prophylaxis for herpes simplex before the peel and throughout the period of re-epithelialization has become the standard, even in patients without a known history of herpetic infection. Although some degree of variation in clinical management between cosmetic surgeons exists, the basic treatment protocol is similar. Patients are instructed to avoid excessive sun exposure and wear sunscreen 3 or more months in advance of their first peel. Retinoic acid 0.5–1.0% and hydroquinone 2–8% are usually applied daily to the area to be peeled starting from 2 to 12 weeks prior to the procedure. As a keratolytic agent, retinoic acid thins the stratum corneum, increasing the depth of the peel and allowing for more uniform absorption. As mentioned earlier, retinoic acid also speeds epidermal healing and independently has a pronounced effect on collagenesis [49]. Because hydroquinone interferes with tyrosinase, the enzyme responsible for the conversion of tyrosine to L-dopa (a melanin precursor) [52], the end result is stabilizing melanin production. The end effect is limiting the amount of postinflammation pigment from the chemical peel's dermal inflammatory reaction. This is particularly important in darker skin types (Fitzpatrick III and higher) but also in lighter skin with dyschromia.

The day of the peel, most patients are advised to start antiviral prophylaxis (some are

instructed to start 2 days before the peel) and continue for 7–10 days. In some cases, the patient is also given a prescription for an antibiotic (i.e., Cephalexin) and advised to start taking whole-food supplements [52]. Patients are to avoid any procedure that may alter the penetration of the peeling agent, such as waxing, microdermabrasion, electrolysis, or laser hair removal, for 2 weeks prior to the peel. The wait following isotretinoin therapy can be anywhere from 12 to 24 months.

##### 4.8.4.2 Application of the Wounding Agent

Before application of the peeling agent, patients are usually given a short, active sedative (i.e., Valium 5–10 mg) and a mild analgesia (meperidine and hydroxyzine hydrochloride). Frequently, aspirin is given before the peel and continued throughout the first 24 h, not only to relieve pain, but also to combat swelling. The area to be peeled is cleansed vigorously with an antiseptic cleanser using a 4 by 4 gauze pad, and residual facial oil is removed with acetone. The peeling agent is then applied with either cotton-tipped applicators or 2-inch by 2-inch gauze, usually with one or two coats to achieve a light frosting in the case of Jessner's solution [49]. Once frosting is achieved, the Jessner's solution is no longer active.

Upon complete drying, the skin is now ready for the 35% TCA peel. The depth of penetration can be influenced at this stage by the method of application. Using large cotton-tipped applicators allows for more solution application and, therefore, absorption. Repeat rubbing with 4-inch by 4-inch gauze or the application of multiple layers are two techniques for enhancing penetration. TCA is typically applied to one cosmetic unit, allowed to reach an end point, diluted with cool saline compresses, then applied to the next cosmetic unit. The activity of TCA ceases upon complete frosting, which is noticeable at 30 s to 2 min. The sequence of application is typically from forehead, to temple, to cheeks, and lastly to lips and eyelids [49]. Judicious placement of the peeling agent to eyelids and lips is imperative, and having an assistant to

protect the ocular canthi and stretch the skin over the lip along the vermillion is essential. The end point for medium-depth peels can be selected based on the level of actinic damage or lesion type being treated. Frosting represents keratocoagulation and may take several different forms as defined by Rubin (see below). It can serve as a guide, indicating areas not adequately covered, but it is advised that 3–4 min should pass before a second coating or “touch-up” of TCA is applied to an area of uneven frosting [49]. Many still rely on the level of frosting to estimate the depth of penetration attained although this measure is thought by others to be unreliable and not supported scientifically [57]. Rubin’s level 0 frosting is described as pink or erythematous skin. During level 1 frosting, the skin is still pink, but white speckles have begun to appear. Level 2 frosting refers to skin that is frosted but with background pink skin intervening. Level 3 frosting is defined by opaque, solid-white skin that appears blanched and is thought to represent a depth of penetration in the reticular dermis [58]. This level of frosting is usually avoided, except in fair skin where blending of the upper neck may be desired [59].

Most people experience an intense burning during the peeling process, but this sensation subsides as the frosting is completed. [49] In a split-face study comparing the usefulness of topical anesthetic agents EMLA versus ELA-MAX cream applied after 70% glycolic acid but before the application of 35% TCA, Koppel and colleagues demonstrated a significant reduction in pain between the anesthetized areas and the control side (unanesthetized). There was no difference, however, between the two types of topical anesthesia used or in the histology of the sides treated and untreated with anesthetic cream [60]. The activity of the TCA peel is completed once the frosting has occurred, but persistent mild discomfort is not unusual [61]. Cool saline compresses can offer relief, as well as aspirin or other nonsteroidal anti-inflammatory agents in the immediate postoperative period.

Similar steps are taken in the case of glycolic acid pretreatment, except in the case of glycolic acid peels there is no associated frosting to indicate reaction cessation. Glycolic acid peels

need to be timed, and with longer duration of peel contact and higher concentration of glycolic acid, the operator can adjust the intensity of effect. Cook et al. reported the findings of high patient satisfaction and low rate of complications in a series of 3,100 patients treated with a combination of 70% glycolic acid gel with 40% TCA used on facial and nonfacial skin to treat photodamage, striae, and pigmentary abnormalities [59]. These clinicians used 70% glycolic acid gel instead of liquid to act as a partial barrier to the TCA solution, which was applied immediately after. The end point of this technique was a Rubin’s level I or II frosting, and the peeling agents were neutralized with 10% sodium bicarbonate solution [58]. Cook et al. coined the term “total body peel” for this type of peel, not because the peel is applied to the entire body, but because it can be used on most parts of the body. Accordingly, their most impressive results were seen on the hand, neck, and chest of patients with actinic damage.

#### 4.8.4.3 Postpeel Management

Similar to superficial peels, the postpeel regimen is geared toward maximizing the benefit and minimizing adverse effects. Postoperative day one, the patient is instructed to soak with 0.25% acetic acid solution four to five times a day and apply a bland emollient (petrolatum based) until re-epithelialization has occurred. After 24 h, a mild, nondetergent cleanser can be used on the face. At this point, the brawny desquamation that replaced the frosting is more visible and sloughs over the next 5–10 days, leaving behind bright erythema characteristic of new skin formation. The process of re-epithelialization is generally complete 10 days out, at which point the patient may discontinue the antiviral prophylaxis and begin to wear makeup, if desired. Again, many physicians counsel patients to avoid smoking in the postoperative period fearing that tobacco use may lessen the peel effect and increase risks [47]. Sun exposure should be avoided for 6 weeks postprocedure to reduce the risk of dyschromia and limited thereafter to minimize the recurrence of photodamage.

## 8.5 Adverse Effects

4 Complications and risks of medium-depth peel are fewer with the advent of the combination peel, but they still exist. The most common complication following a TCA peel is hyperpigmentation, and the most common factor responsible is early sun exposure [52]. Patients are routinely instructed to avoid significant sun exposure in the weeks leading up to and following a medium-depth peel. A sunscreen with a UVA/UVB block is to be worn faithfully, and some doctors recommend their patients abstain from oral contraceptives (2 months before and after peeling) because their use may incite pigmentary changes [52, 44]. Pretreatment with retinoic acid and hydroquinone can reduce the risk of postoperative hyperpigmentation, but those with darker skin types and or those being treated for pigment problems are at even greater risks. If it arises, postpeel hyperpigmentation can be managed with retinoic acid, hydroquinone products, midpotency topical steroids, and follow-up peels (approximately 3–6 months later) until a lightening effect is achieved [44, 52]. Postpeel hypopigmentation is less frequently a problem, but its treatment options are few and less reliable. Although previously thought only to be a complication of deep peels, hypopigmentation has been reported following blanching with 20% TCA and 35% TCA chemical peels [44]. In darker skin types, this potentially permanent side effect can be devastating.

Hypertrophic scarring is a rare but is a disastrous complication of TCA peels. Those at increase risk include patients who have undergone facial plastic surgery, including a rhytidectomy, blepharoplasty, and deep-plane face lift in close proximity to peeling. Resnik et al. recommend a 6-month waiting period after these procedures before attempting a dermal peel. Additionally, patients who have taken isotretinoin should wait a minimum of 1 year before having a medium-depth peel although many clinicians prefer to wait 18–24 months [44]. Obagi et al., however, conducted a large controlled study and reported that hypertrophic scarring did not result from past, current, or postoperative use of isotretinoin as long as the

peel depth did not extend beyond the papillary dermis [62]. Misplacement of the chemical and the depth of penetration in excess of the operator's expectation are features of peeling that might be avoidable. Special care in not allowing the agent to drip or be drawn into unwanted areas is of critical importance. Maintaining a container with water and 10% sodium bicarbonate close at hand to neutralize glycolic acid and TCA, respectively, can tighten the control one has over how long and where the agent contacts the skin. Conditions that predispose to delayed healing may also be responsible for the development of hypertrophic scarring in certain patients. Chronic medical illnesses, prior radiation, chemical or thermal burns, and medication known to delay wound healing may all play a role in predisposing to scarring. The areas most vulnerable to this disfiguring effect are the jaw line, skin overlying the zygomatic arch, and the perioral perimeter. Treatment options include massage, compression bandages, topical/intralesional steroids, and silicone gel sheeting [44, 63, 64].

Herpes simplex infection reactivation is a risk of any skin-resurfacing procedure. Because the consequences of a herpes outbreak following a medium-depth peel can be diffuse facial dissemination and scarring, patients are routinely prophylaxed with antiviral medication. The regimen may include any of the accepted oral antiherpetic medications beginning from 2 days before the peel (or started on the day of) and continued until re-epithelialization is complete (postoperative days 7–10). If an acute infection erupts in spite of prophylaxis, the medication is usually continued but at a higher dose. With early intervention, scarring is frequently avoided [52]. The risk of bacterial infection is reduced by the frequent acetic acid soaks (1 tablespoon of white vinegar/1 pint of water) recommended following the peel, which is not only antimicrobial against *Pseudomonas* and other gram-negative organisms but acts as a debridement. Candidal infection may result from prophylactic antibiotics [47].

Less serious but more common side effects reported include milia, acne flares, and cyst formation [47] and keratoacanthomas [62] following chemical peeling. The use of occlusive oint-



ments following the peeling process has been implicated as a possible cause. Bland emollients are a necessity in order to protect the newly laid epithelium and promote wound healing. Persistent erythema beyond the accepted 60 days may indicate an incipient scar, contact dermatitis, or infection, and warrants careful proactive management in most cases [47].

#### 4.8.6 Outcome

In most cases of actinic damage, the medium-depth peel has been effective, as evidenced by a diminution of AK and lessening of fine lines and wrinkles. Tse et al. accepted the challenge of comparing two different medium-depth combination peels, 70% glycolic acid/35% TCA versus Jessner's solution/35% TCA, with respect to clinical and histological effects on facial skin [66]. Thirteen patients with AK, fine wrinkling, and lentigines were treated prospectively with both combination peels, each one applied randomly to either the left or right side of the face. Patients were evaluated at postoperative intervals of 7, 30, and 60 days using photographs and preauricular skin biopsies taken at each of the three postoperative visits. Clinically, both peeling combinations were effective at treating solar lentigines and AK, with the glycolic acid/TCA demonstrating a slight advantage in eliminating AK. Neither peel was significantly effective at treating fine wrinkles. Recovery time for both agents was comparable at 7–10 days, but the Jessner's/TCA combination created more postoperative erythema (30–60 days). Additionally, discomfort with the glycolic combination was slightly greater. Histologically, a more prominent periappendageal infiltrate was detected on the Jessner/TCA side, but greater neoelastogenesis on the side treated with the glycolic/TCA sides. An increased thickness of the Grenz zone was noted on the glycolic acid/TCA side, a finding that was, however, statistically insignificant [66].

Advanced photoaging (Glogau level III) is characterized by dyschromic skin with obvious keratoses and demonstrable wrinkles at rest (Table 4.3). These patients are thought to typically fall into the age range of 50–60 years, but

there is variation based on history of sun exposure, ethnicity, and Fitzpatrick's classification of skin types (Table 4.2). In a study evaluating these types of patients with severe facial actinic damage, Witheiler et al. demonstrated that medium-depth peels can be equal in efficacy to 5-FU chemexfoliation in the treatment of AK, but reappearance of these lesions in both groups during a 12–32 month follow-up confirmed the need for regular follow-up [67].

Pigmentary dyschromias, including postinflammatory hyperpigmentation, and melasma, have both been treated successfully with medium-depth peels. The epidermal component of these pigmentary aberrations is responsive to superficial and medium-depth chemical peels, topical bleaching agents, and laser therapy. The dermal component can also be responsive to medium-depth chemical peeling agents albeit the response is less. In addition to removing the epidermis (and offending pigment), medium-depth peels also affect the melanocytes in the pilar apparatus during the process of re-epithelization [49]. This mechanism, along with pre/posttreatment regimens with retinoic acid and hydroquinone, allows for a reduction in the risk of rebound hyperpigmentation when treating these pigmentary problems in nonwhite skin.

A combination medium-depth peel using Jessner's/35% TCA was used to treat 15 Iraqi brown-skinned patients with acne scars classified as "crater-like form" and "pitted (ice-pick)," with enhanced treatment around the edge of the scar with 50% TCA beginning at the time of the second of three total peels [68]. The interval between peels was 1 month, and clinical response was documented by serial photographs and patient self-assessments. At an evaluation 3 months following the final peel, moderate improvement was achieved in eight of the 15 patients (53.3%) and minimal to no response in one patient each. In spite of pretreatment with bleaching aids, posttreatment hyperpigmentation was recorded in nine patients (73.4%) but completely resolved by the 3-month follow-up. Patients with primarily atrophic scars fared better than those with predominantly pitted scars, but the overall level of patient satisfaction with the outcome of their treated acne scars was 80%.

Cook et al. reported that in their series of 3,100 patients treated with a 70% glycolic acid gel and 40% TCA combination peel, approximately 10% were treated on their abdomen. In many cases, they found that abdominal striae distensae can be greatly improved, even if hypopigmented and atrophic. Understanding that the appearance of striae distensae frequently improves with time, irrespective of treatment, the authors warn that in those patients who did not observe improvement after the first peel, subsequent peels would likely be of no benefit.

By focally applying TCA at concentrations ranging from 10% to 65%, Chun et al. safely treated a host of benign pigmented lesion in 106 dark-skinned patients. The chemical peeling agent was applied to the affected area with a sharpened wooden applicator and allowed to remain until frosting. The concentration selected was based on the desired depth of penetration required to target each given lesion. The results revealed that 42 of 49 (86%) patients with solar lentigines, 19 or 23 (83%) patients with seborrheic keratosis, eight of 14 (58%) patients with freckles, and 11 of 20 (55%) patient with melasma experienced a good clinical response without significant complications [56]. A study involving 20 patients with Fitzpatrick skin types II–III and mild to moderate photoaging were treated monthly with four pyruvic acid 50% facial peels. Postoperative evaluation was based on this agent's ability to improve the classic signs of photoaging and revealed smoother skin texture, less-apparent fine wrinkles, and lightening of freckles and lentigines [48]. Patient acceptance was high overall for this procedure due not only to the success in clinical improvement but also the low risk of complications and limited postpeel discomfort.

#### 4.8.7 Ethnic Skin Considerations

In Fitzpatrick skin types IV–VI, medium-depth peels can be used for many of the same indications for which superficial peels are employed in this group (Table 4.2). The lesions requiring this form of therapy in white skin, however, may be less prevalent in ethnic skin by virtue of the latter's response to and extent of sun dam-

age. The medium-depth peeling agents used in patients with darker skin are the same as those used in their white counterparts. The chemical percentage, combinations, and even the vehicle chosen, however, may be different. Roberts describes a technique of using glycolic acid 70% gel in place of solution before applying TCA 25% solution for the treatment of acne scars in darker skin. Although the glycolic acid enhances the effect of the TCA, the gel vehicle limits the harshness of this second product, allowing for more control of the peeling process [22]. This author also emphasized that the TCA should not be allowed to frost completely but, rather, be neutralized with 10% sodium bicarbonate after 2–4 min, depending on the lesion being treated. For areas of postinflammatory hyperpigmentation, Roberts recommended “spot peel,” using TCA 25% salicylic acid or Jessner's solution on discreet areas in combination with or without full-face peeling. Attempts at treating dermal pigment should be avoided because of the inherent risk of permanent depigmentation and hypertrophic scarring in this class of patients. Stringent control of peel depth is basic to achieving a successful outcome in skin types IV–VI because in this population, the treatment of pigmentary and scarring disorders can lead to results worse than the original problem.

### 4.9 Deep Chemical Peeling

- Primary effects extending to the mid-reticular dermis
- Suitable for Fitzpatrick skin types I–III
- High risk of postoperative complications

#### 4.9.1 Scientific Background

Deep chemical peels create an injury through the papillary dermis into the upper reticular dermis and may extend into the midreticular dermis (0.6 mm). Deep peeling agents include phenol-containing preparation, or TCA in concentrations above 50%. Because of the risks as-

sociated with 50% TCA, such as scarring, TCA at these concentrations are not recommended for deep chemical peeling. Therefore, solutions containing phenol is the agent of choice for deep chemical peels [34]. In this section, the focus will be phenol-containing deep chemical peels.

Baker-Gordon phenol formula, occluded and unoccluded, is the most commonly used deep chemical peel. It is composed of a mixture of 3 ml 88% phenol USP, three drops of croton oil, eight drops of Septisol, and 2 ml of distilled water [43]. The mixture of ingredients is freshly prepared and must be stirred vigorously prior to application due to its poor miscibility. Phenol at 80% or higher concentrations precipitates epidermal proteins, thus forming a barrier hindering dermal penetration, while phenol diluted to 50% is keratolytic, allowing increased dermal penetration and hence greater dermal injury. Croton oil is an epidermolytic agent that augments phenol penetration. Septisol increases surface tension and is thought to slow the penetration of phenol [69]. The phenol peel can be applied under occlusion using waterproof zinc oxide nonporous tape or left unoccluded. Occlusion increases the penetration of the phenol by promoting tissue maceration and preventing the agent's evaporation [70]. The unoccluded technique as modified by McCollough involves more cleansing of the skin and the application of more peel solution [71]. This may enhance the efficacy of the solution but without penetrating as deeply as in an occluded peel.

The reaction following application of phenol is characterized by keratocoagulative necrosis of the epidermis extending into the papillary dermis and by a marked inflammatory reaction. Epidermal regeneration begins within 48 h and is completed within 1 week. Dermal regeneration takes longer than epidermal healing and is characterized by rigid, compact collagen in the upper dermis replacing the disorganized collagen seen in elastosis [72].

#### 4.9.2 Indications

Deep peels involve the use of chemoexfoliants that penetrate to the midreticular dermis [45].

Indications for the use of deep peeling agents include deep rhytids secondary to photoaging (Glogau type III or IV), treatment of severe or extensive AK, and solar lentiginosities (Table 4.2). Although the practice is not universally accepted, some physicians use deep peels for acne scarring and melasma [43].

#### 4.9.3 Patient Selection

There are many relative contraindications to deep chemical peels, which depend on the patient's Fitzpatrick skin type and medical history (Table 4.2). Therefore, patient selection is critical in deep chemical peeling. The ideal patient is a fair-complexioned female with thin, dry skin and fine wrinkles, that is, Fitzpatrick skin type I or II and Glogau type III or IV [43].

It is important to remember that phenolic peels pose systemic risks so that patients with a preexisting history of cardiac, hepatic, or renal disease should not undergo a deep chemical peel (Table 4.3). Patients with active herpes simplex labialis infections are not candidates for this type of peel. Also, if a patient has a prior history of HSV infections, they should be prophylactically treated with acyclovir, valacyclovir, or famciclovir prior to the peel and continue until re-epithelialization is completed.

Patients with Fitzpatrick skin type IV–VI are not candidates for deep chemical peels secondary to the increased risk of pigmentary changes, especially hypopigmentation and scarring [44]. Male patients are less favorable candidates for deep chemical peeling, not only because of their unwillingness to use cover-up makeup to camouflage postoperative pigmentary changes, but also because their thick, sebaceous skin does not respond well [43].

Also, patients with diminished or absent normal dermal appendages (e.g., previous radiation treatment or taking Accutane) are poor candidates [5]. Because epidermal regeneration is dependent on migration of epithelium from skin adnexa, in their absence, wound healing is delayed and can result in atrophic and scarred skin with abnormal color and texture. Normal skin topography, including the number of vellus hairs, usually indicates that the epidermis is

capable of re-epithelializing after a chemical peel [40]. Also, deep chemical peels should be delayed a minimum of 2–3 months in patients who have had recent rhytidectomy, blepharoplasty, or deep-plane face lifts.

#### 4.9.4 Treatment and Clinical Management

##### 4.9.4.1 Preprocedure Rejuvenation Regimen

The preprocedure rejuvenation regimens used in deep chemical peeling are identical to those used for superficial chemical peeling.

##### 4.9.4.2 Application of the Wounding Agent

On the day of the procedure, the patient cleanses their face, does not apply any cosmetics, and should be fasting prior to the procedure. Since anesthesia is generally required for deep chemical peels, a thorough preoperative history and physical must be completed prior to beginning the peel. In addition, intravenous hydration with a liter of lactated Ringer's solution should be given prior to the procedure as well as another liter during the procedure. Cardiac monitoring, pulse oximetry, and blood pressure monitoring with full resuscitation capabilities are mandatory for full-face deep peeling with phenol, even if the anesthesia is restricted to light intravenous sedation or local nerve blocks with 1% lidocaine. After thorough cleansing and degreasing of the skin, the chemical agent is applied sequentially to six aesthetic units: forehead, perioral region, right cheek, left cheek, nose, and periorbital region, proceeding from one segment to the next after an interval of 10–15 min between each cosmetic unit, allowing 60–90 min for the entire procedure [19, 43].

Of importance, the Baker-Gordon solution must be prepared at the time of the procedure and repeatedly stirred to keep the various components evenly mixed. After mixing, the solution should be kept in a glass bowl or basin with

a broad bottom so the solution can be gently agitated or stirred without danger of spilling or splashing. One to two cotton-tipped applicators are used to stir the solution and to apply it to the skin. The patient's eyes must be kept closed throughout the procedure. The applicator tip is stroked quickly and with moderate pressure over the cosmetic unit while watching for a whitening frost that appears within 10 s. The cosmetic segment is considered "painted" once an opaque white frost is observed. After each segment is evenly frosted, dry cold compresses and fanned air are used to help minimize the burning sensation. Also, ice packs can be used to symptomatically cool the skin [43]. It is important to remember that diluting phenol compound with water may increase the depth of penetration of injury, so tears spilling onto treated areas must be avoided, and if the eyes need to be flushed in the event contact occurs, mineral oil rather than water should be used [34].

After the entire face is treated, at the physician's discretion, waterproof zinc oxide tape may be placed on the skin to create an occlusion peel. The tape is left in place for 24 h, at which time the normal exudates and edema that follow injury cause the tape to spontaneously separate from the skin. The tape is then removed by the patient in the shower. Taping is thought to result in extra penetration of the wounding agent to the applied areas to achieve optimal cosmetic results, particularly areas of deep rhytids such as the perioral areas, glabella, and lateral crow's feet. For untaped peels, petrolatum is applied, and a biosynthetic dressing is used for the first 24 h.

##### 4.9.4.3 Postprocedure Management

Postoperative management varies depending on the physician's preference and experience. Most physicians follow a modified wet or semi-occlusive technique. Patients are instructed to soak their face with plain water several times a day, which is best done by standing in the shower and letting the water fall on the crown and then run down the face for several minutes. This allows the debris and serous exudates to

be gently removed from the treated area. Fingertips and gentle soap can also be used, but abrasives should be avoided. After cleansing the face, a bland emollient (petrolatum) or antibacterial ointment is then applied generously to the entire face. This regimen should be repeated three to five times during the day. It helps to avoid heavy crust formation and allows for rapid re-epithelialization, usually within 12 days [43].

Once epithelialization is complete, the patient is instructed to use green-tinted foundation makeup to minimized erythema. Daily sunscreen is resumed and continued indefinitely. Patients should be instructed that the residual erythema might take several months to subside. Also, hydroquinone and tretinoin therapy may be resumed after epithelialization is complete to reduce postinflammatory rebound hyperpigmentation.

Postoperative visits are scheduled 48–72 h after the peel to confirm that proper postoperative care is being strictly followed. The patient is then seen at the 12-day mark for instruction in makeup, sunscreen, retinoids, and hydroquinone usage. Then the patient is usually seen 4 weeks postoperatively. It is critical to ensure appropriate follow-up to confirm that healing is occurring at the expected rate and to evaluate for possible superinfection or irritation secondary to the ointments used. To avoid potential complications, any deviation from the norm should be address and treated promptly [43].

#### 4.9.5 Adverse Effects

The most notable complications include hypertrophic scarring, textural changes, and pigmentary disturbances. If hypertrophic scarring is suspected and at any sign of erythema with firmness or textural induration, the physician should be notified and the overnight application of silicone gel sheeting (Epiderm, Biodermis, Las Vegas, NV, USA) should begin, as well as weekly assessment of the patient. Early hypertrophic scarring can be successfully stopped by aggressive intervention with the silicone gel sheeting. If no improvement is seen within the first week, the area can be treated by alternating

Cordran tape at bedtime with the silicone sheeting during the day. If no response is seen within 1–2 weeks of this therapy, then intralesional dilute triamcinolone acetonide 2–4 mg/ml applications are made on an every-other-week schedule while continuing the silicone gel sheeting and the Cordran tape at bedtime. Once the erythema has begun to subside, the Cordran tape is stopped to avoid atrophy, and the silicone gel sheeting is continued until the erythema has completely resolved [43].

Permanent pigmentary changes can occur as a complication of phenol peels. Clinically, hypopigmentation occurs when susceptible Fitzpatrick skin types III–VI undergo deep peeling. Because deep phenol peels may lead to irreversible hypopigmentation, hyperpigmentation, scarring, or keloid formation, it is not advised for dark-skinned patients with Fitzpatrick skin types IV–VI [73]. Temporary hypopigmentation is common and predictable, and the final skin color cannot be discerned until all the postpeel erythema has resolved. However, if the erythema has resolved and the hypopigmentation is still present, the pigmentary change is irreversible. Hyperpigmentation is a common postoperative sequelae in darker-skinned patients but usually resolves spontaneously with time, topical tretinoin, and hydroquinone therapy [43].

Infectious complications secondary to bacterial or viral infections and flat warts can be seen. Bacterial infections are usually the result of improper, inadequate, or infrequent cleaning. *Pseudomonas aeruginosa* is treated by using equal parts of water and distilled vinegar to the effected areas several times a day. *Staphylococcus* and *Streptococcus* infections are rare and must be treated with antibiotics. Toxic-shock-like syndromes have been reported following peels [74]. Viral infections secondary to HSV are treated with acyclovir, valacyclovir, or famciclovir. Flat warts (verruca plana) can occur secondary to autoinoculation. Treatment with salicylic acid, liquid nitrogen, topical tretinoin, or even re-peeling is usually successful [43].

The systemic complications of phenol peels are well documented. Phenol has extensive systemic absorption, is directly cardiotoxic



[75], is inactivated by conjugation in the liver, and is 80% excreted by the kidneys [76]. Therefore, phenol peels are contraindicated in patients who have a history of cardiac, hepatic, or renal disease. The cardiotoxicity of phenol is well documented and has been shown to occur within the first 30 min of application [44]. The use of continuous cardiac monitoring, pulse oximetry, blood pressure monitoring, and intravenous hydration before and during the procedure to promote phenol excretion are mandatory and help to prevent toxicity. Additionally, the treatment of small cosmetic units with resting periods of 10–15 min between applications minimizes potential systemic complications [77,78].

Uncommon complications include induction of pemphigus vulgaris in one patient after a phenol peel [79] and laryngeal edema, seen in three chronic smokers after phenol peels. Their respiratory symptoms resolved 48 h after inhalation therapy [80].

#### 4.9.6 Outcome

Deep peeling with phenol solutions can significantly improve or even eliminate deep rhytids and furrows as well as other textural and pigmented irregularities associated with severe photoaging in Glogau groups III and IV. But it is critical to select the appropriate patient as the risks and complications associated with phenol peels can be devastating if the physician lacks expertise and if the patient is not an appropriate candidate. A remarkable degree of improvement is the expected result of deep chemical peeling when performed properly on the appropriate patient [34].

### 4.10 Microdermabrasion

- Primary effects on stratum corneum and epidermis
- Safe for any skin type
- Solo use and as primer for chemical peels

With more than two dozen products by different manufacturers on the market, microdermabrasion has gained much popularity in Europe, Australia, and the United States since its development in Italy in 1985. The various machine types can be divided into the higher power physician's model and the lower power aesthetician's model. The physician's model is capable of creating pressures up to 70 mmHg, affecting deeper layers of skin, and requires the supervision of a physician [81]. No matter what type of equipment is being used, the technique of microdermabrasion relies on two basic functions: (1) superficially abrading the skin with fine, sharp crystals (aluminum oxide, salt, or sodium bicarbonate) via positive- or negative-flowing pressure, and (2) a vacuum closed-loop suction device to remove the crystals, along with dead skin, oil, and surface debris [81, 82].

#### 4.10.1 Scientific Background

Aluminum oxide crystal particles (corundum crystals) are composed of white-fused alumina and bauxite. These particles are inert, water insoluble, and approximately 100  $\mu\text{m}$  in diameter. The abrasive effect of these crystals results from their sharp edges, coupled with the flow generated by the positive stream of crystals flowing via a hand piece with vacuum suction [81]. The vacuum suction collects the crystals in a container that allows for their neat and safe disposal. The depth of penetration is controlled by the level of suction, the duration of time the suction hand piece is held in contact with the skin, and the number of passes. Typically, microdermabrasion treatments exert direct effects on the stratum corneum and epidermis. With high-pressure settings, more aggressive treatment regimens have reportedly affected the reticular dermis in some cases. The exfoliating effect is responsible for the improvement seen in clogged pores. Improved skin texture is a direct effect of removing superficial skin layers, [81] and, although somewhat controversial, the theory of microdermabrasion stimulating dermal collagen deposition is supported by at least one study evaluating the histology of three patients before and after six treatments

[83]. In that study, posttreatment biopsies revealed an increase of collagen deposition in the papillary dermis thought to result from repeated intraepidermal injury. Significant epidermal thickening from 103 microns to 148 microns was demonstrated histologically in one study that evaluated the effects of 8 weekly microdermabrasion treatments. Photograph assessment of baseline and posttreatment photos of this same group of 17 patients revealed a rating of improved pigmentation as reported by all 30 evaluators, but improvement of fine wrinkling was noted only by the 14 nonmedical observers [84]. Tan et al. described a slight abrasion of the stratum corneum following four passes of microdermabrasion at an aggressive setting (65 - mmHg). Clinical erythema, however, persisted for 5–6 days posttreatment and was thought to represent a biologic response. This response may help explain the mechanism behind the diminution of fine rhytids following microdermabrasion of photodamaged areas. In the treatment of depressed scars, formation of granulomas in the upper dermis due to retained aluminum oxide crystals is hypothesized, a histologic finding not typically found after traditional dermabrasion. Microdermabrasion may prove to be better than traditional dermabrasion in treating atrophic scars for this reason [85].

#### 4.10.2 Indications

As an alternative to laser resurfacing, chemical peels, and dermabrasion, microdermabrasion is indicated for similar skin issues but with the limitation of having relatively superficial results. Microdermabrasion, described as a “skin polishing,” is used for atrophic acne scars, mild facial rhytids, clogged pores, traumatic scars [81], enlarged pores, brown spots, stretch marks [86], melasma, keratosis pilaris, and to improve skin texture [81]. Hernandez-Perez admitted to less-than-satisfactory results when treating melasma [87]. Microdermabrasion has also been used to prime the skin for superficial chemical peels by stripping the stratum corneum to ensure more even absorption [81]. When used in conjunction with microdermabrasion, traditional superficial chemical peeling agents

can help many physicians achieve medium-depth chemical peel results with fewer side effects. Anatomic sites treated safely and successfully include face, hands, neck, chest [86], and back [81].

#### 4.10.3 Patient Selection

With predictably superficial results, microdermabrasion has been safely done on all skin types. The concerns of hyperpigmentation limiting many patients from elective resurfacing procedures are greatly reduced in microdermabrasion. If present, posttreatment hyperpigmentation is short lived. The key, in part, to patient satisfaction is in choosing the type of patient who can most likely benefit from this procedure. In a telephone survey including the opinions of 43 patients with a mean number of 4.51 treatments, the overwhelming reason these patients chose the procedure was for the treatment of fine lines plus wrinkles [88]. In this group, satisfaction with the procedure was correlated with an increased number of treatments (three or more). People whose expectations for dramatic change are high, or photodamage and/or acne scars are too extreme, would not be appropriate for microdermabrasion as a sole therapy. Contrary to the opinion of Hernandez-Perez et al., who stated that patients on isotretinoin can be microdermabraded, most authors recommend abstaining from microdermabrasion for at least 1 year following isotretinoin [87]. Other poor candidates include those with cutaneous malignancies, recent herpes outbreak, warts involving the treatment area, flared rosacea, draining acne vulgaris, unstable diabetes, and autoimmune disorders [81].

#### 4.10.4 Treatment and Clinical Management

The technique of microdermabrasion is noninvasive and quite simple. Prior to treatment, the area is cleansed and allowed to dry completely. Vacuum level and crystal pressure may be determined by testing an area of nonfacial skin,

but patient tolerance can also dictate an adjustment in the power setting. The first pass is performed by allowing gentle suction of the skin into the hand piece as it is made to glide along the skin surface. The surface area being treated is stretched taut by the clinician's free hand to avoid excessive suction in any one area, which can cause an abrasion or pinpoint bleeding. A second pass is made at a right angle to the first, and if more passes are required, they should continue to follow this alternating pattern to avoid streaking [81]. Reducing the level of suction and or number of passes may be necessary around the eyes and other delicate areas of the face. The intensity of the treatment, as determined by the number of passes and level of suction, is chosen based on the condition being treated. When the treatment is completed, the residual crystals should be gently brushed off the skin in the direction away from the eyes so as to prevent eye irritation. The skin can then be rinsed with tepid water and a moisturizer with adequate sunscreen applied. Patients are instructed to avoid keratolytic agents, including retinoids, alpha-hydroxy acids, and benzoyl peroxides 3 days before and 3 days following the treatment. They are asked to avoid waxing, electrolysis, and laser hair removal 1 week before treatment, and excessive sun exposure 2 weeks before treatment. All patients are given prophylaxis for HSV 1 day before and 2 days following the treatment using standard oral antiviral therapy.

#### 4.10.5 Adverse Effects

Complications from microdermabrasion are few and avoidable with a proper patient history. Unlike traditional dermabrasion, the risk for scarring and hyperpigmentation is quite low. Reviewing 2 years of microdermabrasion treatments involving 126 patients, Freeman reported that there were no instances of hypopigmentation, scarring, or postoperative wound infections. In 2 referred cases, the same author reported abrasive injuries from treatments thought to be due to impurities in the aluminum oxide crystals. These injuries resulted in a detectable groove upon healing [89]. Because

microdermabrasion breaks in the integrity of the skin barrier, many physicians preoperatively treat patients prophylactically with antiviral medication to avoid flaring of quiescent HSV [90].

Although a very well-tolerated procedure, the noncutaneous complications of microdermabrasion warrant precautions. The risk of eye irritation and corneal abrasion [82] from the crystals has many technicians and patients using protective eye wear during the procedure. Pulmonary fibrosis and tracheal and laryngeal papillomas have been linked to aluminum oxide dust exposure [91]. The presence of aluminum in the brain senile plaques of Alzheimer's patients has raised the question of the risk of chronic exposure to aerosolized aluminum oxide, which places patients and technicians at increased risk of cognitive impairment in the future. The particle size of the aluminum oxide crystals used for microdermabrasion are significantly larger than those for dental use (100–120  $\mu\text{m}$  versus 24–50  $\mu\text{m}$ ), and the smaller particles used for dental air abrasion have not been found to pose a significant health hazard [92]. The larger particles used in microdermabrasion are inert and too heavy to become aerosolized and are not likely to pose a risk to the respiratory or cognitive systems [82].

#### 4.10.6 Outcome

Critics of microdermabrasion will agree that among the risks associated with this procedure, "disappointment" should be included. Because microdermabrasion was approved by the FDA as a type 1 device, the manufacturer does not have to establish performance standards for the machine, only to manufacture the device using good manufacturing practices (GMP) guidelines. With the 1998 issuance of "exempt" status, there is no need for a clearance letter from the FDA in order to sell the instrument in the United States [82]. The effects are described as superficial in most cases, although the physician can reach the level of the dermis with a machine capable of positive pressure crystal delivery. Evidence that the epidermal-dermal junction has been reached may present clinical-

ly as punctate hemorrhage. Re-epithelialization is usually complete within 1 week, but erythema may persist just beyond 2 weeks. More uniform punctate bleeding may indicate reaching the papillary dermis, and treatments extending to the reticular dermis are marked by full-face bleeding [92]. With variation in the depth of penetration, the anticipated results depend greatly on the treated lesions.

Tan et al. treated ten volunteers on the face with Fitzpatrick skin types I–III with Glogau scale II–III photodamage once a week for five to six treatments. Assessments immediately before and after the first, second, and fifth visit, and a final evaluation 1 week following the last session, were performed. The vacuum pressure was maintained at 30 mmHg for four passes full face and 15 mmHg for two passes periorbitally. An increased roughness consistent with mild abrasion and a slight flattening of wrinkles were detected immediately following the treatment but did not last in the majority of patients beyond 1 week. A significant but transient decrease in sebum production was also noted. Increased skin compliance and decreased skin stiffness was noted on the cheeks, a finding that persisted for 1 week following the final treatment. Seven of the ten patients reported clinical improvement in their photodamage as a result of the microdermabrasion treatments. The three patients without any improvement were classified as Glogau group III photodamage. Histologic evaluation was performed on preauricular 2 mm punch biopsies of 2 volunteers at baseline and following the final session. A slight increase in orthokeratosis, and a diminished epidermal rete ridge pattern were noted superficially. Vascular ectasia, a perivascular mononuclear cell infiltrate, and edema were seen in the reticular dermis. Two additional healthy males received 3-mm forearm punch biopsies before and immediately following four passes at 65 mmHg (aggressive setting). Results demonstrated thinning of the stratum corneum and slight dermal edema but no epidermal change. No significant change was seen in the content of collagen or elastin [82].

In another study by Hernandez-Perez et al., seven women (median age 45 years) underwent five microdermabrasion treatments at weekly

intervals. A 3-mm punch biopsy was taken from the malar area before the first treatment and following the fifth, which showed the most dramatic change in epidermal thickness – a change that was statistically significant. Clinically, there was a moderate to excellent improvement in oily skin and dilated pores in all patients. In 86% of the patients, the improvement in fine wrinkles was good and in 14% only moderate [87]. Histologically, improvement in inflammation, telangiectasias, and edema were noted. Collagen fibers in the dermis were reportedly more fibrillar and less basophilic, and an improvement in the elastotic material was detected. With such dermal effects, some have compared the outcome of microdermabrasion to medium-depth chemical peels [86]. Others have declared that even ten serial microdermabrasion treatments cannot achieve the results possible with one papillary dermis peel [93].

Comparing microdermabrasion with glycolic acid peels in terms of efficacy and patient satisfaction, Alam et al. treated ten female patients (mean age 43) split face with six consecutive weekly 20% glycolic acid peels and mild-setting microdermabrasion. Comparative reviews were composed of patient ratings, investigator ratings, and photographs before any treatments and 1 week following the last treatment. Skin features under review included redness, brown spots, smoothness, softness, and wrinkles. Investigators' ratings revealed no significant treatment-specific differences when evaluated by photographs or in person. Patient ratings, however, revealed some marked differences between the two procedures. With respect to skin texture, four of the ten patients favored the glycolic acid peels, two favored microdermabrasion treatments, three found that both procedures improved the skin texture equally, and one felt no significant change from either intervention. Fine wrinkles were improved more by glycolic acid peels in four patients, by microdermabrasion in one patient, and equally in five patients. Skin color was improved more by glycolic acid peels in four patients, by microdermabrasion in one patient, equally in three patients, but not at all in two patients. An overall preference for glycolic acid peels was stated by

seven of the ten patients while, of the remaining three, one preferred microdermabrasion and two revealed no preference [94].

Chemexfoliation and superficial skin resurfacing continue to be two essential techniques in the arsenal allowing cosmetically oriented physicians to be competitive in the anti-aging war. From the most superficial chemical peel agents to those more deeply penetrating, the dermatologist is able to implement for the patient a treatment regimen targeted to meet specific goals but tailored to individual lifestyles. Chemical peels and microdermabrasion will likely remain among the most popular “cosmetic procedures” of younger generations whose early intervention may afford them the luxury of preventive rather than therapeutic practices.

## References

1. Brody HJ, Monheit GD, Resnik SS, Alt TH (2000) A history of chemical peeling. *Dermatol Surg* 26: 405-409
2. Brody H (1992) History and classification of chemical peels. In: Patterson AN (ed) *Chemical peeling*, 1st edn. Mosby, St. Louis. pp 7-22
3. Resnik SS, Lewis LA, Cohen BH (1976) TCA peeling. *Cutis* 17:127-129
4. Alt TH (1989) Occluded Baker-Gordon chemical peel: Review and update. *J Dermatol Surg Oncol* 15: 980-993
5. Rubenstein R, Roenigk HH, Stegman SJ, Hanke CW (1986) Atypical keloids after dermabrasion of patients taking isotretinoin. *J Am Acad Dermatol* 15: 280-285
6. Dingman DL, Hartog J, Siemionow M (1994) Simultaneous deep-plane face lift and trichloroacetic acid peel. *Plast Reconstr Surg* 93:86-93 (discussion 4-5)
7. Brody HJ (2003) Skin resurfacing: Chemical peels. In: Freedberg IM, Eisen AZ, Wolf K (eds) *Fitzpatrick's dermatology in general medicine*, 6th edn. McGraw-Hill, New York 2530-2535
8. Wolfe SA (1982) Chemical face peeling following therapeutic irradiation. *Plast Reconstr Surg* 69: 859-862
9. Monheit GD (1995) Facial resurfacing may trigger herpes simplex virus. *Cosmet Dermatol* 8:9-16
10. Kligman D and Kligman AM (1988) Salicylic acid peels for the treatment of photoaging. *Dermatol Surg* 24:325-328
11. Swinehart JM (1990) Test spots in dermabrasion and chemical peeling. *J Dermatol Surg Oncol* 16: 557-563
12. Monheit GD (1996) Skin preparation: an essential step before chemical peeling or laser resurfacing. *Cosmet Dermatol* 9-14
13. Nanda S, Grover C, and Reddy BS (2004) Efficacy of hydroquinone (2%) vs tretinoin (0.025%) as adjunct topical agents for chemical peeling in patients of melasma. *Dermatol Surg* 30:385-389
14. Grimes PE (1999) The safety and efficacy of salicylic acid chemical peels in darker racial-ethnic groups. *Dermatol Surg* 25:18-22
15. Sarkar R, Kaur C, Bhalia M, and Kanwar AJ (2002) The combination of glycolic acid peels with a topical regimen in the treatment of melasma in dark-skinned patients: a comparative study. *Dermatol Surg* 28:828-832
16. Kligman AM, Willis I (1975) A new formula for depigmenting human skin. *Arch Dermatol* 111:40-48
17. Kwak MY, Rhee JS (1994) Cultivation characteristics of immobilized *Aspergillus oryzae* for kojic acid production. *Biotechnol Bioeng* 39:903-906
18. Cabanes J, Chazarra S, Garcia-Carmona R (1994) Kojic acid, a cosmetic whitening agent, is a slow-binding inhibitor of catecholase activity of tyrosinase. *J Pharm Pharmacol* 46:982-985
19. Brody HJ (1997) *Chemical peeling and resurfacing*, 2nd edn. Mosby, St Louis
20. Resnik SS, Resnik BI (1995) Complications of chemical peeling: cosmetic dermatology. *Dermatol Clin* 13:309-331
21. Goldman MP, Fitzpatrick RE (1995) Laser treatment of scars. *Dermatol Surg* 21:685
22. Roberts WE (2004) Chemical peeling in ethnic/dark skin. *Dermatol Ther* 17(2):196-205
23. Newman N, Newman A, Moy LS, et al (1996) Clinical improvement of photoaged skin with 50% glycolic acid: a double-blinded vehicle-controlled study. *Dermatol Surg* 22:455-460
24. Khunger N, Sarkar R, Jain RK (2004) Tretinoin peels versus glycolic acid peels in the treatment of melasma in dark-skinned patients. *Dermatol Surg* 30:756-760
25. Burns RL, Prevot-Blank PL, Lawry MA, et al (1997) Glycolic acid peels for postinflammatory hyperpigmentation in black patients: A comparative study. *Dermatol Surg* 23:171-175
26. Marrero GM, Katz BE (1998) The new fluor-hydroxy pulse peel: A combination of 5-fluorouracil and glycolic acid. *Dermatol Surg* 24:973-978
27. Moy LS, Peace S, Moy RL (1996) Comparison of the effect of various chemical peeling agents in a minipig model. *Dermatol Surg* 22:429-432
28. Moy LS, Howe K, Moy RL (1996) Glycolic acid modulation of collagen production in human skin fibroblast cultures in vitro. *Dermatol Surg* 22:139-141
29. Katz B (1995) The fluor-hydroxy pulse peel: a pilot evaluation of a new superficial chemical peel. *Cosmet Derm* 8:24-30
30. Jansen GT (1971) Topical therapy with 5-fluorouracil. *J Surg Oncol* 3:317-323



31. Bercovitch L (1987) Topical chemotherapy of actinic keratoses of the upper extremity with tretinoin and 5-fluorouracil: a double-blind controlled study. *Br J Dermatol* 116: 549–552
32. Pearlman DL (1991) Weekly pulse dosing: effective and comfortable topical 5-fluorouracil treatment of multiple facial actinic keratoses. *J Am Acad Dermatol* 25: 665–667
33. Kligman D, Kligman AM (1997) Salicylic acid as a peeling agent for the treatment of acne. *Cosmetic Dermatol* 10: 44–47
34. Monheit GD and Chastian MA (2003) Chemical and mechanical skin resurfacing. In: Bologna JL, Jorizzo JL, Rapini RP (eds) *Dermatology*. Mosby, Philadelphia, 2: 2379–2398
35. Van Scott EJ, Yu RJ (1984) Hyperkeratinization, corneocyte cohesion, and alpha hydroxyl acids. *J Am Acad Dermatol* 11: 867–879
36. Van Scott EJ, Yu RJ (1989) Alpha hydroxyl acids: procedures for use in clinical practice. *Cutis* 43: 222–228
37. Monheit GD (1989) The Jessner's and TCA peel: A medium depth chemical peel. *J Dermatol Surg Oncol* 15: 945–950
38. Stagnone JJ (1989) Superficial peeling. *J Dermatol Surg Oncol* 15: 924–930
39. Brody HJ (1989) Variations and comparisons in medium-depth chemical peeling. *J Dermatol Surg Oncol* 15: 953–963
40. Roenigk RK, Brodland DG (1993) A primer of facial chemical peel. *Dermatol Clin* 11: 349–359
41. Collins PS (1989) Trichloroacetic acid peels revisited. *J Dermatol Surg Oncol* 15: 933–940
42. Obagi ZE, Obagi S, Alaiti S, and Stevens MB (1999) TCA-based blue peel: A standardized procedure with depth control. *Dermatol Surg* 25: 10: 773–780
43. Glogau RG, Matarasso SL (1995) Chemical peels: Trichloroacetic acid and phenol. *Dermatol Clinics* 13(2): 263–276
44. Resnik SS and Resnik BI (1995) Complications of chemical peeling. *Dermatol Clinics* 13(2): 309–312
45. Manaloto RMP and Alster TS (1999) Periorbital rejuvenation: A review of dermatologic treatments. *Dermatol Surg* 25(1): 1–9
46. Johnson JB, Ichinose H, Obagi ZE (1996) Obagi's modified trichloroacetic acid (TCA)-controlled variable-depth peel: a study of clinical signs correlation with histologic findings. *Ann Plast Surg* 36: 225–237
47. Monheit GD, Chastain, MA (2001) Chemical peels. *Facial Plast Surg Clin North Am* 9(2): 239–255
48. Gersetich I, Brazzini B, Peris K et al (2004) Pyruvic acid peels for the treatment of photoaging. *Dermatol Surg* 30: 32–36
49. Monheit GD (2001) Medium-depth chemical peels. *Dermatol Clin* 19(3): 413–425
50. Stegman SJ (1982) A comparative histologic study of the effects of three peeling agents and dermabrasion on normal and sun damaged skin. *Aesth Plast Surg* 6: 123
51. Nelson BR, Fader DJ, Gillard M, et al (1995) Pilot histologic and ultrastructural study of the effects of medium depth facial peels on dermal collagen in patients with actinically damaged skin. *J Am Acad Dermatol* 32: 472–478
52. Mendelsohn JE (2002) Update on chemical peels. *Otolaryngol Clin North Am* 35(1)
53. Cotellessa C, Manunta T, Ghersetich I, et al. The use of pyruvic acid in the treatment of acne. *J Eur Acad Dermatol Venerol* 18(3): 275–278
54. Griffin TD, Van Scott EJ (1991) Use of pyruvic acid in the treatment of actinic keratoses: a clinical and histopathologic study. *Cutis* 47: 325–329
55. Halasz CL (1998) Treatment of warts with topical pyruvic acid: with and without added 5-fluorouracil. *Cutis* 62: 283–285
56. Chun E, Lee JB, Lee KH (2004) Focal trichloroacetic acid peel method for benign pigmented lesions in dark-skinned patients. *Dermatol Surg* 30: 512–516
57. Coleman WP 3rd. Dermal peels. *Dermatol Clin* 2001 19(3): 405–11
58. Rubin MG (1995) *Manual of chemical peels: superficial and medium depth*. Lipincott-Raven, Philadelphia
59. Cook K, Cook W Jr (2000) Chemical peel of nonfacial skin using glycolic acid gel augmented with TCA and neutralized based on visual staging. *Dermatol Surg* 26: 994–999
60. Koppel RA, Coleman Kyle M, Coleman III WP (2000) The efficacy of EMLA versus ELA-MAX for pain relief in medium-depth chemical peeling: a clinical and histopathologic evaluation. *Dermatol Surg* 26: 61–64
61. Monheit GD (1994) The Jessner's TCA peel. *Facial Plastic Surg Clin North Am* 2: 21–22
62. Obagi S, Obagi Z, Bridenstine JB (2002) Isotretinoin use during chemical skin resurfacing: a review of complications. *Am J Cosmet Surg* 19: 9–13
63. Ahn ST, Monafa WW, Mustoe TA (1991) Topical silicone gel for the prevention and treatment of hypertrophic scar. *Arch Surg* 126: 499–504
64. Gold MH (1994) A controlled clinical trial of topical silicone gel sheeting in the treatment of hypertrophic scars and keloids. *J Am Acad Dermatol* 30: 506–507
65. Cox E (2003) Rapid development of keratoacanthomas after a body peel. *Dermatol Surg* 29: 201–203
66. Tse Y, Ostad A, et al (1996) A clinical and histologic evaluation of two medium depth peels. Glycolic acid versus Jessner's, trichloroacetic acid. *Dermatol Surg* 22: 781–786
67. Witheiler D, Lawrence N, et al (1997) Long-term efficacy and safety of Jessner's solution and 35% trichloroacetic acid vs 5% fluorouracil in the treatment of widespread facial actinic keratoses. *Dermatol Surg* 23: 191–196
68. Al-Waiz M, Al-Sharqi A (2002) Medium-depth chemical peels in the treatment of acne scars in dark-skinned individuals. *Dermatol Surg* 28: 383–387

69. Matarasso SL, Brody HJ (1996) Deep chemical peeling. *Semin Cutan Med Surg* 15:115-161
70. Brody HJ (1997) Deep peeling. In: Brody HJ (ed) *Chemical peeling and resurfacing*, 2nd edn. Mosby, St. Louis 137-159
71. McCollough EG, Langsdon PR (1989) Chemical peeling with phenol. In: Roenigk H, Roenigk R (eds) *Dermatologic surgery: principles and practice*. Marcel Dekker, New York, 997-1016
72. Stuzin JM, Baker TJ, Gordon HL (1993) Treatment of photoaging facial chemical peeling (phenol and trichloroacetic acid) and dermabrasion. *Clin Plast Surg* 20:9-25
73. Pandya AG, Guevara IL (2000) Disorders of hyperpigmentation. *Dermatol Clin* 18:91-98
74. LoVerme WE, Drapkin MS, Courtiss EH, et al (1987) Toxic shock syndrome after chemical face peel. *Plast Reconstr Surg* 80:115-118
75. Stagnone GJ, Orjel MG, Stagnone JJ (1987) Cardiovascular effects of topical 50% trichloroacetic acid and Bakers phenol solution. *J Dermatol Surg Oncol* 13:999-1002
76. Beeson WH, McCullough EG (1985) Chemical face peeling without taping. *J Dermatol Surg Oncol* 11:985-990
77. Beeson WH (1987) The importance of cardiac monitoring in superficial and deep chemical peeling. *J Dermatol Surg Oncol* 13:949-950
78. Botta SA, Straith RE, Goodwin HH (1988) Cardiac arrhythmias in phenol face peeling: A suggested protocol for prevention. *Aesth Plastic Surg* 12:115-117
79. Kaplan RP, Detwiler SP, Saperstein HW (1993) Physically induced pemphigus after cosmetic procedures. *Int J Dermatol* 32:100-103
80. Klein DR, Little JH (1983) Laryngeal edema as a complication of chemical peel. *Plast Reconstr Surg* 71:419-420
81. Koch RJ, Hanasono M (2001) Microdermabrasion. *Facial Plast Surg Clin of North Am* 9(3):377-382
82. Tan M, Spencer J, et al (2001) The evaluation of aluminum oxide crystal microdermabrasion for photodamage. *Dermatol Surg* 27:943-949
83. Rubin MG, Greenbaum SS (2000) Histologic effects of aluminum oxide microdermabrasion on facial skin. *J Aesth Derm Cosmetic Surg* 1:237
84. Coimbra M et al (2004) A prospective controlled assessment of microdermabrasion for damaged skin and fine rhytids. *Plast Reconstr Surg* 113:1438-43
85. Tsai R, Wang C, Chan H (1995) Aluminum Oxide Crystal Microdermabrasion. *Dermatol Surg* 21:539-542
86. Bernard R, Beran SJ, et al (2000) Microdermabrasion in clinical practice. *Clin Plast Surg* 27 (4):571-577
87. Hernandez-Perez E, Ibiert EV (2001) Gross and microscopic findings in patients undergoing microdermabrasion for facial rejuvenation. *Dermatol Surg* 27:637-640
88. Bridges MA, Chrzanowski DS et al (2003) The efficacy of facial microdermabrasion. *Cosmetic Dermatol* 16(2):19-21
89. Freeman MS (2001) Microdermabrasion. *Facial Plast Surg Clin North Am* 9(2):257-266
90. Warmuth I, Bader R, Sarborough DA et al (1999) Herpes simplex infection after microdermabrasion. *Cosmet Dermatol* 12(7):13
91. Stenback F, Rowland J, Sellakumar A (1976) Carcinogenicity of benzo pyrene and dusts in the hamster lung (instilled intratracheally with titanium oxide, aluminum oxide, carbon and ferric oxide. *Oncology* 33:29-34
92. Clark CP 3rd (2001) New directions in skin care. *Clin Plast Surg* 28(4):745-749
93. Obagi ZE, Obagi S (2004) Pearls for successful chemical peels. *Cosmetic Dermatology* 17(6):363-371
94. Alam M, Omura N, Dover JS, Arndt KA (2002) Glycolic acid peels compared to microdermabrasion: a right-left controlled trial of efficacy and patient satisfaction. *Dermatol Surg* 28:475-479

# Botulinum Toxin

Cheryl M. Burgess

## Core Messages

- *Clostridium botulinum* produces eight serologically distinct toxins: A, B, C $\alpha$ , C $\beta$ , D, E, F, G. Of the eight serotypes, A is the most potent.
- Botulinum toxin type A and type B are the only commercially available serotypes and are used for various medical indications, including cosmetic treatment.
- Botulinum toxin relaxes the underlying muscles of expression, leading to a reduction in the formation of skin creases. Over time, regular maintenance treatments can lead to the disappearance of these creases.
- Botulinum toxin is safe and effective in all skin types (Fitzpatrick I–VI).

5.3	<b>Indications</b> . . . . .	88
5.3.1	Botulinum Toxin Type A . . . . .	88
5.3.1.1	Botox Medical . . . . .	88
5.3.1.2	Botox Cosmetic . . . . .	88
5.3.1.3	Dysport . . . . .	88
5.3.2	Botulinum Toxin Type B . . . . .	88
5.4	<b>Patient Selection</b> . . . . .	88
5.4.1	Managing Patient Expectations . . . . .	88
5.4.2	Pretreatment Considerations . . . . .	89
5.4.3	Postinjection Considerations . . . . .	89
5.4.4	Contraindications . . . . .	89
5.5	<b>Treatment and Clinical Management</b> . . . . .	89
5.5.1	Botulinum Toxin Type A . . . . .	90
5.5.2	Botulinum Toxin Type B . . . . .	91
5.6	<b>Complications/Adverse Reactions</b> . . . . .	91
5.6.1	Other Reported Side Effects . . . . .	91
5.7	<b>Prognosis/Outcome</b> . . . . .	91
	<b>References</b> . . . . .	92

## Contents

5.1	<b>Introduction</b> . . . . .	83
5.2	<b>Scientific Background</b> . . . . .	84
5.2.1	Availability . . . . .	84
5.2.2	History of Treatment Using Botulinum Toxin . . . . .	85
5.2.2.1	Partial List for the Use of Botulinum Toxin . . . . .	85
5.2.3	Muscles Involved in Treatment Using Botulinum Toxin . . . . .	86

## 5.1 Introduction

The formation of crease lines and rhytids is a natural component of the aging process. As individuals enter their 30s and 40s, fine lines, creases, rhytids, and sagging skin become apparent, and deep furrows and frown/scowl lines often develop. Such furrows and frown/scowl lines are referred to as dynamic rhytids because they arise when we laugh, frown, or smile and are caused by the repeated forces generated by the underlying muscles. These hyperkinetic muscles include the frontalis (responsible for forehead furrows), corrugator supercilii (involved in frown/scowl lines), orbicularis oculi (responsible for crow's feet), and procerus and

depressor supercillii (also involved in frown/scowl lines). The repetitive contraction of these muscles beneath the skin causes creases and rhytids [1]. Botulinum toxin, a natural purified protein, is used to relax these facial muscles of expression.

## 5.2 Scientific Background

5

*Clostridium botulinum* (Fig. 5.1) produces eight serologically distinct botulinum toxins designated A, B, C $\alpha$ , C $\beta$ , D, E, F, G. Of the eight serotypes, A is the most potent, although serotypes B and F are almost as strong. These proteins are activated by complexing with hemagglutinin and the nontoxic molecule. A dimer forms, and activity is caused by the resulting inhibition of acetylcholine release from presynaptic neurons at the neuromuscular junction (NMJ). The inhibition takes place as the neurotoxin cleaves SNAP-25 proteins and ultimately leads to the chemical denervation at the motor end plate. Symptoms are characterized by striated muscle relaxation that usually begins 2–3 days after local injection. Relaxation is correlated with the amount of natural purified protein delivered. With exposure to increasing amounts, the relaxation may ultimately progress to total relaxation by 8–10 days postinjection. Although this process of chemical denervation is complete in all exposed NMJs, neurogenesis leads to recov-

ery of the muscle in almost every situation. Denervation effects are generally inactivated in 3–6 months [1].

Botulinum toxin is an immunogenic protein and is capable of producing neutralizing and nonneutralizing antibodies. Treatment failure and eventual attenuation of the therapeutic effects may be traced to this immunogenic response. Fortunately, antibodies to one serotype of the botulinum protein do not cross-neutralize another, so an option for continuing therapy may be to change to another serological type [1]. For individuals treated for cosmesis or hyperhidrosis, the development of resistance has not been a problem. However, neutralizing antibodies have been reported in 3–5% of patients treated for dystonia [2, 3, 4].

### 5.2.1 Availability

Currently, four commercially available sources of the purified protein of botulinum toxin are available. Three sources contain type A: (1) Botox Medical and (2) Botox Cosmetic are available worldwide from Allergan (Irvine, CA, USA); (3) Dysport, from Speywood Pharmaceuticals (Spotsylvania, VA, USA), is available in many parts of the world but not currently in the United States. The fourth source, Myobloc, from Elan Pharmaceuticals (San Francisco, CA, USA) [5], contains botulinum toxin type B and is

### BOTOX® Structure

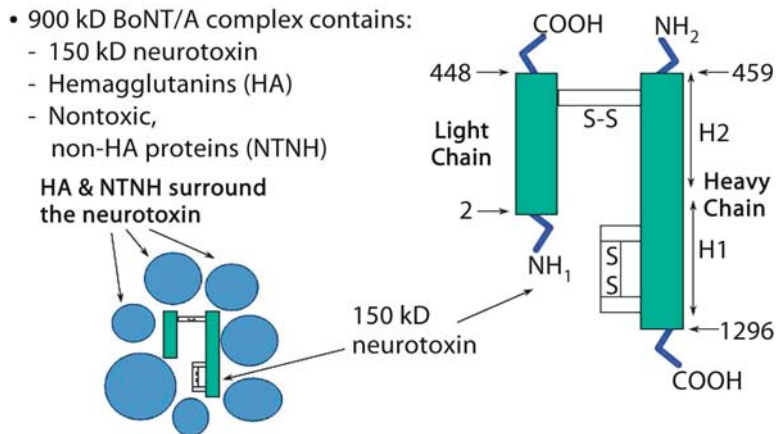


Fig. 5.1. Chemical structure of botulinum toxin A

available under the name Neurobloc in Europe. Myobloc functions in a similar manner as the type A botulinum toxin, although the two serotypes are not interchangeable for all uses. Aside from being antigenically distinct serotypes, Myobloc differs from botulinum toxin type B in its formulation characteristics, complications, dosing, and response [5, 6].

## 5.2.2 History of Treatment Using Botulinum Toxin

Botulinum toxin type A has been used safely and effectively for more than 15 years to treat many disorders, including strabismus, blepharospasm, and myotonic dystrophies [1, 7]. The first evidence of potential therapeutic use was reported in 1973 when muscle relaxation was demonstrated in studies using a monkey model [8]. In 1980, the natural purified protein of botulinum toxin was used in the treatment of strabismus, marking the beginning of medical use of this molecule in human beings [1]. At present, botulinum toxin has been shown to be beneficial in the treatment of many disease states. A partial list of treatments is presented below.

### 5.2.2.1 Partial List for the Use of Botulinum Toxin for Medical Purposes

The following list provides some of the medical applications for botulinum toxin [1]:

- Dystonia
- Cranial dystonia
- Blepharospasm
- Lower facial dystonia
- Oromandibular dystonia
- Cervical dystonia
- Spasmodic torticollis

- Craniocervical dystonia
- Meige's syndrome
- Laryngeal dystonia
- Spasmodic dysphonia
- Limb dystonia
- Sustained or fixed dystonia
- Task-specific dystonia
- Hemifacial spasm
- Tremor
- Tics
- Myoclonus, including palatal myoclonus
- Spasticity
- Multiple sclerosis
- Cerebral palsy
- Poststroke states
- Posttraumatic
- Ophthalmologic conditions
- Strabismus
- Acute oculomotor nerve palsy
- Nystagmus
- Masseteric hypertrophy
- Anal fissure
- Anismus
- Detrusor sphincter dyssynergia
- Achalasia
- Bilateral primary axillary hyperhidrosis [9]
- Brow furrows and frown lines

In 1991, Carruthers and Carruthers reported at the annual meeting of the American Society for Dermatologic Surgery the use of botulinum toxin injections for glabellar rhytids. In 1992, Borodic et al. noted a decrease in facial wrinkling in the course of treating individuals with



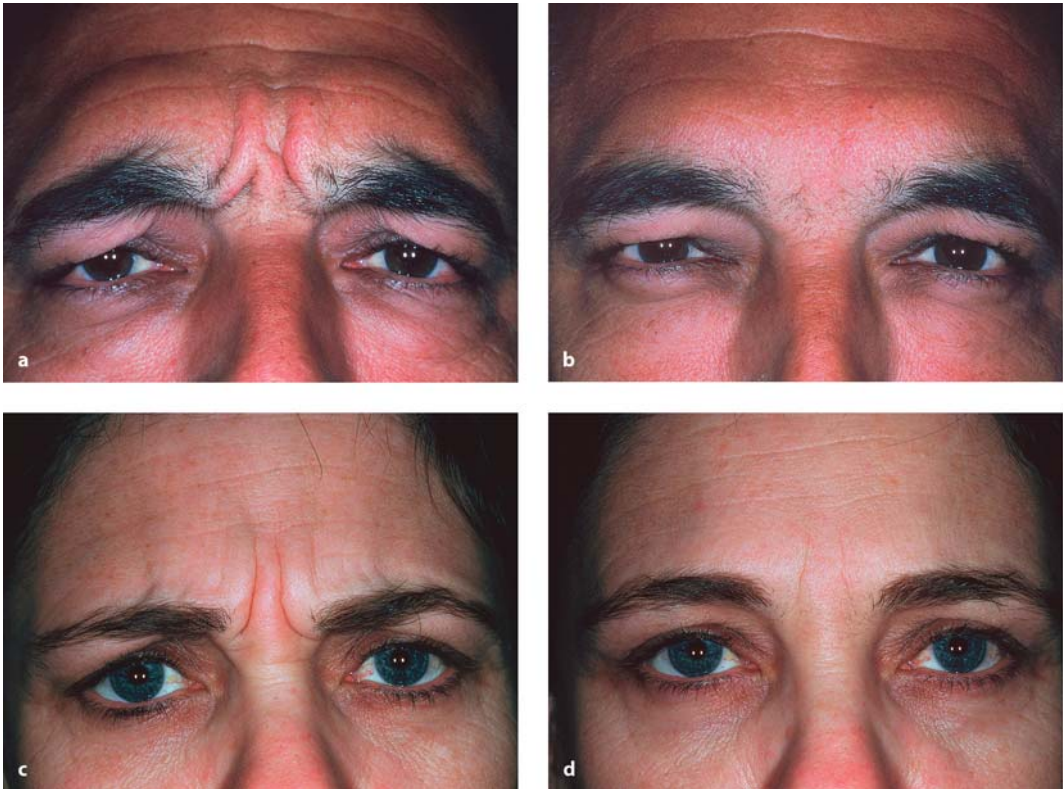hemifacial spasm [10]. Such observations led to interest in botulinum toxin for treating rhytids. Since that time, additional research has been undertaken to explore its usefulness to treat hyperkinetic movement disorders as well as its capacity to reduce hyperkinetic glabellar facial lines. Numerous studies were undertaken in the mid-1990s; for example, one study evaluated the protein's ability to ameliorate facial kinetic frown lines [7] while a double-blind, placebo-controlled investigation evaluated its efficacy to treat glabellar folds [11]. A collaborative study of 210 injection sites in 162 patients showed the natural purified protein to be a safe and important adjunctive technique for the management of patients with symptomatic hyperfunctional facial lines [12].

Today, treatment of rhytids with botulinum toxin is the top nonsurgical procedure in the United States with over one million people in-

jected. Demographics indicate that the volume of treatment will increase, as baby-boomer statistics reveal a large market with considerable financial assets: 78 million people aged 36–54 years old (born between 1946 and 1964). While only 29% of the US population, this segment controls 74% of personal financial assets (Allergan). This large market is driven by women in their 40s who have become self-aware of their aging, find that managing appearance is more urgent, and desire more than ever to take care of themselves (Fig. 5.2).

### 5.2.3 Muscles Involved in Treatment Using Botulinum Toxin

Tables 5.1, 5.2, and 5.3 and Figs. 5.3 and 5.4 depict the muscles involved in treatment with botulinum toxin [13].



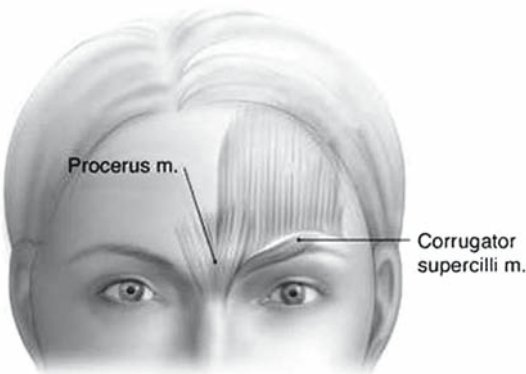
**Fig. 5.2.** Relaxation of the frown lines in a woman and man treated with Botox Cosmetic: before treatment and 4 weeks following treatment of the corrugator supercillii and procerus muscles

**Table 5.1.** Anatomic considerations: upper face

Muscle	Function
Frontalis	Raises the eyebrows and produces transverse wrinkles of the forehead
Corrugator	Brings the eyebrows toward each other
Procerus	Pulls the glabellar skin in an inferior direction and causes a transverse rhytid
Depressor supercillii	Depresses the eyebrow
Orbicularis oculi	Functions as the sphincter of the eye

**Table 5.2.** Anatomic considerations: mid and lower face

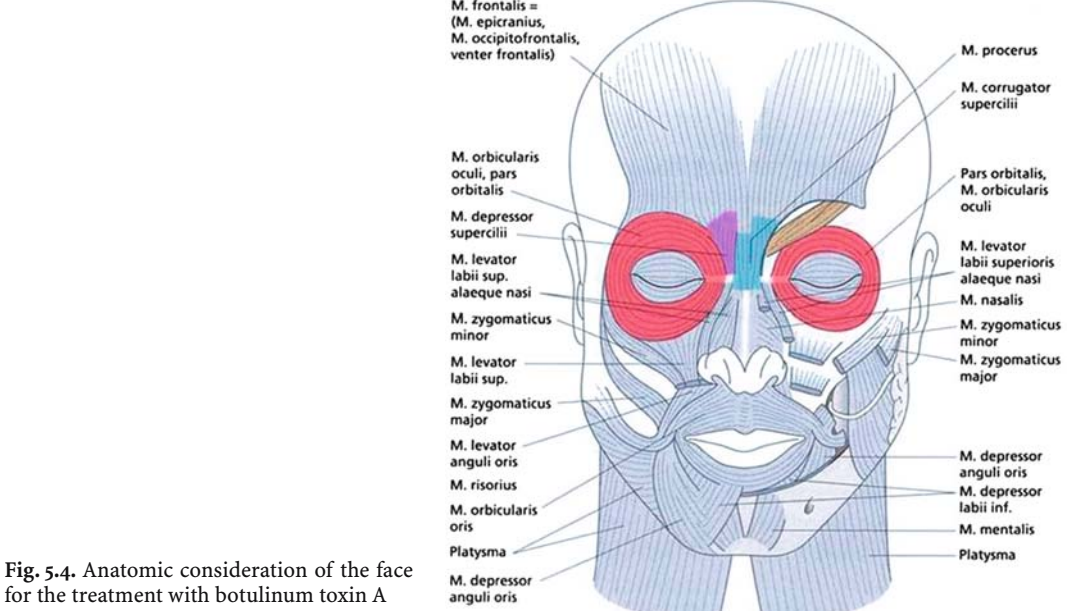
Muscle	Function
Risorius	Draws the corners of the mouth laterally
Orbicularis oris	Sphincter of the mouth
Levator labii superioris	Raises the upper lip
Depressor anguli oris	Depresses the corner of the mouth
Depressor labii inferioris	Lowers the lower lip
Modiolus	Wagon wheel of muscle situated just lateral to the external commissure of the mouth; the muscles of perioral and lip expression insert into here, allowing graded symmetrical perioral expression



**Fig. 5.3.** Illustration of upper facial muscles involved in the expression of frowning

**Table 5.3.** Anatomic considerations: neck

Muscle	Function
Platysma	Lowers the jaw and lip; tenses the neck; forms vertical bands and causes horizontal lines



**Fig. 5.4.** Anatomic consideration of the face for the treatment with botulinum toxin A

## 5.3 Indications

### 5.3.1 Botulinum Toxin Type A

#### 5.3.1.1 Botox Medical

Botox Medical has the longest commercial history, having been approved by the FDA in 1989 for the treatment of strabismus and blepharospasm and in December 2000 for the treatment of cervical dystonia. Botox therapy is approved in over 70 countries for a broad range of conditions and is currently being investigated in the United States for even more medical conditions, among them hyperhidrosis [9], poststroke spasticity, back spasm, and headache [14].

#### 5.3.1.2 Botox Cosmetic

Botox Cosmetic was approved by the FDA in April 2002 for the temporary improvement in the appearance of moderate to severe glabellar lines in men and women 65 years of age or younger. While the approval specifically applies to the vertical lines between the eyebrows, there are numerous reports in the literature where other rhytids, such as crow's feet, horizontal forehead lines, neck lines, melolabial folds, and other hyperkinetic facial lines, have also been successfully treated [14, 15].

#### 5.3.1.3 Dysport

Dysport is another brand of botulinum toxin type A. It has been available in the United Kingdom since the early 1990s and has been used extensively there and elsewhere in Europe for a number of different medical indications, including blepharospasm, hemifacial spasm, and spasmodic torticollis [16]. Dysport is not currently approved for cosmetic use anywhere in the world. However, it is still favored by some practitioners in the United Kingdom as an alternative to Botox Medical for treating lines and rhytids.

### 5.3.2 Botulinum Toxin Type B

Myobloc contains botulinum toxin type B. It was licensed by the FDA in January 2001 for treatment of cervical dystonia. Elan Pharmaceuticals, the manufacturer of Myobloc, makes no recommendations for its use in cosmetic purposes. However, because it has FDA approval for treatment of cervical dystonia, patients in the United States can consent to off-label use for cosmetic purposes [17]. Moreover, the efficacy and safety of using botulinum toxin type B for cosmetic purposes has been demonstrated in a number of small pilot studies. Overall, the results of these studies found that botulinum toxin type B was an effective treatment for glabellar wrinkles [18, 19, 20, 21, 22, 23], forehead wrinkles [20, 21, 24], and crow's feet [21, 25, 26]. Further investigation of the safety and efficacy of using botulinum toxin type B for cosmetic purposes will be necessary.

## 5.4 Patient Selection

Today's aesthetically oriented consumer is ambitious, optimistic, and upbeat, placing great emphasis on a person's own beauty and seeking high levels of satisfaction with personal appearance. These consumers are also deliberate and thoughtful when considering methods to achieve satisfaction in appearance. However, qualitative research has found that individuals are not looking for dramatic work that brings drastic change because results are too obvious. The goal is to look better naturally, more well-rested, refreshed, and vital as well as less stressed, tired, and annoyed, which involves less frowning. Achieving a natural look, as if nothing has been done, brings self-confidence to patients.

### 5.4.1 Managing Patient Expectations

Cosmetic denervation with botulinum toxin is suitable for all skin types. It provides relaxation of dynamic rhytids giving patients a more youthful appearance. Deep furrows or rhytids may require higher doses and/or more yearly

treatments. Overall, doses will vary from person to person. It is important for patients to understand that they are not being paralyzed; rather, hyperkinetic muscles are being relaxed. They should also be made aware that Botox treatment does not improve the more common static rhytids that are unrelated to facial contraction. Moreover, cosmetic denervation will not improve loose or sagging skin and does not serve the same function as a facelift. For patients with a combination of dynamic and static rhytids, improvements may be limited if Botox treatment only is used. To optimize a treatment program, many options are available to use botulinum toxin in combination therapy, including injectable fillers and microimplants. Early results from clinical trials suggest that the duration of benefits from Botox treatment increases with time so that a patient may require less frequent injections in the future, but this varies from person to person.

#### 5.4.2 Pretreatment Considerations

Because of the potential for bleeding, patients should avoid using (1) anticoagulants, including warfarin, aspirin, or nonsteroidal anti-inflammatory drugs (NSAIDs); (2) nutritional supplements such as Ginkgo biloba, garlic, or vitamin E; and (3) alcohol.

#### 5.4.3 Postinjection Considerations

Postinjection, patients may apply makeup even before leaving the physician's office. They should, however, avoid physical activity or exercise for the remainder of the day. If bruising be-

comes a concern, patients should immediately apply cold compresses to the injected area.

#### 5.4.4 Contraindications

Botulinum injections are contraindicated in patients with a history of neurological disorders such as myasthenia gravis, amyotrophic lateral sclerosis, Eaton-Lambert syndrome, and myopathies [27, 28]. They are also contraindicated for individuals in the following categories:

- Pregnant or lactating women
- Psychological or medical contraindications
- Allergy to aminoglycoside antibiotics
- Infection at the proposed injection sites [14]

#### 5.5 Treatment and Clinical Management

It is important to note that the definition of a unit of activity varies among Botox, Dysport, and Myobloc. In clinical use, Botox appears three to four times stronger (in mouse units) than Dysport, and the dose must be adjusted accordingly [15]. Determining an equivalent unit of Myobloc is more complicated due to differences in such details as the vehicle, dilution scheme, and laboratory protocols for various assays (Table 5.4) [29].

**Table 5.4.** Comparison of Botox and Myobloc preparations

	Botox	Myobloc
Preparation	Lyophilized powder in vials of 100 U	Liquid in vials of 2,500, 5,000, and 10,000 U
pH	7.2	5.5
Complex size	500–900 kDa	500–700 kDa
Specific potency	20 U/ng	100 U/ng
Stability	Approximately 4 h after reconstitution	2 years when stored at 4–8°C
Immunogenicity	Very low	Unknown

### 5.5.1 Botulinum Toxin Type A

Botox Cosmetic is supplied in 100-U vials, which must be kept between 2°C and 8°C until used. Additionally, the sterile vacuum vial contains albumin and sodium chloride but does not contain a preservative. The 100-U vial is re-

constituted with 2.5 ml of normal saline (0.9% NaCl), resulting in a final concentration of 4 U/cc of Botox Cosmetic. Due to the absence of a preservative, Botox Cosmetic should be stored in a refrigerator and used within 4 h. Small quantities are injected directly into the muscles to be treated (Table 5.5) using a 30- to 32-gauge needle and a calibrated syringe [14].

Table 5.5. Treatments and injection sites

Region	Type of correction	Injection site	Additional Information
Facial asymmetry	Hemiparesis: naturally occurring or consequence of medical conditions such as Bell's palsy [30]	Contralateral muscles [30]	
Upper face	Glabellar creases	Corrugator/supercilli/procerus	Orbicularis oculi: pretreatment snap test and Schirmer documented tear secretion
	Forehead lines	Frontalis	
	Forehead and brow shaping	Frontalis, depressor supercillii, lateral orbicularis oculi	
	Periorbital rhytids or crow's feet Eye shaping to increase the palpebral aperture	Inferior ciliary margin of the orbicularis oculi [31]	
Midface [32]	Nasalar radix (bunny lines), nasolabial folds Nasal flare Gummy/canine smile	Levator alaeque nasi Levator labii superioris	Causes upper lip ptosis
Lower face [32]	Marionette lines or mouth frown	Depressor anguli oris	Potential side effect includes asymmetric relaxation of the oral commissure
	Perioral rhytids and mouth shaping	Orbicularis oris	
	Peau d'orange (pebbly chin)	Depressor labii inferioris Mentalis muscle	
Neck [32]	Horizontal neck creases	Intradermal along the transverse neckline	Possibility of dysphagia
	Platysmal bands	Platysma	
Below the neck	Décolleté creases [33]	Subcutaneous muscle fibers running over the third intercostal spaces and over the presternal area [33]	
	Breast lifts		



The injections may cause some discomfort manifested as mild stinging or burning. Patients should avoid physical activity or exercise for the remainder of the day.

### 5.5.2 Botulinum Toxin Type B

Myobloc is sold as a premixed solution, ready to use, and it has a longer shelf life than Botox, maintaining its potency for many months stored at room temperature. Myobloc may serve as an alternative to patients who are resistant to botulinum toxin type A [6].

## 5.6 Complications/Adverse Reactions

Side effects most often reported during clinical trials included headache, respiratory infection, blepharoptosis, nausea, and flu syndrome. Less frequently occurring adverse reactions included pain in the face and erythema at the injection site. In rare cases, botulinum injections have caused transient relaxation of injected or nearby muscles, resulting in blepharoptosis (eyelid ptosis) or asymmetry of facial expression. Blepharoptosis is a short-lived side effect that can be reversed by treating with an alpha-1-adrenergic agent. Asymmetry of facial expression can be corrected by relaxing the contralateral muscles. Unlike blepharoptosis, asymmetry of facial expression can be a prolonged side effect. The risk of any side effects depends on which muscles are injected. Because treatment is completely reversible, side effects related to excessive relaxation are temporary, lasting only days or weeks [14]. The human median lethal dose ( $LD_{50}$ ) is estimated to be 40 U/kg (2,800 U for an average 70-kg individual) [34].

### 5.6.1 Other Reported Side Effects

Other side effects reported with botulinum toxin treatments are:

- Dry mouth
- Change in voice (platysmal/neck injections)
- Diplopia/blurred vision
- Ectropion
- Dry eyes
- Lymphedema
- Cheek ptosis
- Rash
- Abnormalities of cardiovascular reflexes
- Generalized weakness
- Muscle jitters [35, 36] (no clinical relevance)
- Ecchymosis, headache, muscle soreness—general areas, especially with glabella and forehead injections
- Upper eyelid to ptosis—glabellar injections
- Perioral dysfunction—perioral lines
- Potentiation of neurological disease
- Unresponsiveness to botulinum natural purified protein

## 5.7 Prognosis/Outcome

The effects of botulinum toxin relaxation of the underlying muscles of expression can last 3–5 months, and benefit increases over time, leading to a reduction in the formation of skin creases. If regular maintenance sessions achieve persistent muscle relaxation, these skin creases can diminish over time. However, regular maintenance sessions must take place before muscle relaxations completely reverse themselves.

## References

1. Carruthers A, Kiene K, Carruthers J (1996) Botulinum A exotoxin use in clinical dermatology. *J Am Acad Dermatol* 34(5): 788–797
2. Tintner R, Jankovic J (2001) Focal dystonia: the role of botulinum toxin. *Curr Neurol Neurosci Rep* 1(4): 337–345
3. Smith ME, Ford CN (2000) Resistance to botulinum toxin injections for spasmodic dysphonia. *Arch Otolaryngol Head Neck Surg* 126(4): 533–535
4. Siatkowski RM et al (1993) Serum antibody production to botulinum A toxin. *Ophthalmology* 100(12): 1861–1866
5. Elan Pharmaceutical Inc (2000) Myobloc package insert
6. Guttman C (2002) Botulinum toxin type B option for wrinkles, sweating. *Dermatology Times*
7. Foster JA et al (1996) The use of botulinum A toxin to ameliorate facial kinetic frown lines. *Ophthalmology* 103(4): 618–622
8. Scott AB, Rosenbaum A, Collins C (1973) Pharmacologic weakening of extraocular muscles. *Invest Ophthalmol* 12(12): 924–927
9. Naumann M, Lowe NJ (2001) Botulinum toxin type A in treatment of bilateral primary axillary hyperhidrosis: randomised parallel group double blind placebo controlled trial. *BMJ* 323(7313): 596–599
10. Borodic GE, Cheney M, McKenna M (1992) Contralateral injections of botulinum A toxin for the treatment of hemifacial spasm to achieve increased facial symmetry. *Plast Reconstr Surg* 90(6): 972–979
11. Lowe NJ, Maxwell A, Harper H (1996) Botulinum A exotoxin for glabellar folds: a double-blind placebo-controlled study with an electromyographic injection technique. *J Am Acad Dermatol* 35(4): 569–572
12. Blitzer A et al (1997) The management of hyperfunctional facial lines with botulinum toxin. A collaborative study of 210 injection sites in 162 patients. *Arch Otolaryngol Head Neck Surg* 123(4): 389–392
13. Fodor P, Nicanor GI, Hengst TC (1996) Endoscopically assisted plastic surgery. Mosby, St Louis
14. Allergan Pharmaceuticals (2002) Botox Cosmetic (botulinum toxin type A). Prescribing information
15. Carruthers A, Carruthers J (1994) Botulinum toxin used in the treatment of glabellar frown lines and other facial wrinkles. In: Jankovic J, Hallett M (eds) *Therapy with botulinum toxin*. Marcel Dekker, New York, pp 577–595
16. Dysport Cbotulinum type A toxin-haemagglutinin complex: patient information leaflet
17. Elan Pharmaceuticals (2004) Myobloc: Cosmetic use
18. Sadick NS, Faacs (2002) Botulinum toxin type B for glabellar wrinkles: a prospective open-label response study. *Dermatol Surg* 28(9): 817–821
19. Sadick NS (2003) Prospective open-label study of botulinum toxin type B (Myobloc) at doses of 2400 and 3000 U for the treatment of glabellar wrinkles. *Dermatol Surg* 29(5): 501–507
20. Spencer JM, Gordon M, Goldberg DJ (2002) Botulinum B treatment of the glabellar and frontalis regions: a dose response analysis. *J Cosmet Laser Ther* 4(1): 19–23
21. Ramirez AL, Reeck J, Maas CS (2002) Botulinum toxin type B (Myobloc) in the management of hyperkinetic facial lines. *Otolaryngol Head Neck Surg* 126(5): 459–467
22. Alster TSL, Lupton J R (2003) Botulinum toxin type B for dynamic glabellar rhytides refractory to botulinum toxin type A. *Dermatol Surg* 29(5): 516–518
23. Lowe NJ et al (2002) Botulinum toxins types A and B for brow furrows: preliminary experiences with type B toxin dosing. *J Cosmet Laser Ther* 4(1): 15–18
24. Flynn TC, Clark RE (2003) 2nd Botulinum toxin type B (MYOBLOC) versus botulinum toxin type A (BOTOX) frontalis study: rate of onset and radius of diffusion. *Dermatol Surg* 29(5): 519–522
25. Baumann L et al (2003) A double-blinded randomized placebo-controlled pilot study of the safety and efficacy of Myobloc (botulinum toxin type B)-purified neurotoxin complex for the treatment of crow's feet: a double-blinded placebo-controlled trial. *Dermatol Surg* 29(5): 508–515
26. Matarasso SL (2003) Comparison of botulinum toxin types A and B: a bilateral and double-blind randomized evaluation in the treatment of canthal rhytides. *Dermatol Surg* 29(1): 7–13
27. Borodic G (1998) Myasthenic crisis after botulinum toxin. *Lancet* 352(9143): 1832
28. Erbguth F et al (1993) Systemic effect of local botulinum toxin injections unmasking subclinical Lambert-Eaton myasthenic syndrome. *J Neurol Neurosurg Psychiatry* 56(11): 1235–1236
29. ATC Draft (2001) Facial aesthetic enhancements: chemodenervation and tissue augmentation pp 76
30. Finn JC (2004) Botulinum toxin type A: fine-tuning treatment of facial nerve injury. *J Drugs Dermatol* 3(2): 133–137
31. Flynn TC, Carruthers, JA (2001) Botulinum-A toxin treatment of the lower eyelid improves infraorbital rhytides and widens the eye. *Dermatol Surg* 27(8): 703–708
32. Carruthers J, Carruthers A (2001) BOTOX use in the mid and lower face and neck. *Semin Cutan Med Surg* 20(2): 85–92
33. Becker-Wegerich PM, Rauch L, Ruzicka T (2002) Botulinum toxin A: successful décolleté rejuvenation. *Dermatol Surg* 28(2): 168–171
34. Scott AB, Suzuki D (1988) Systemic toxicity of botulinum toxin by intramuscular injection in the monkey. *Mov Disord* 3(4): 333–335
35. Lange DJ et al (1991) Distant effects of locally injected botulinum toxin: a double-blind study of single fiber EMG changes. *Muscle Nerve* 14(7): 672–675
36. Girlanda P et al (1992) Botulinum toxin therapy: distant effects on neuromuscular transmission and autonomic nervous system. *J Neurol Neurosurg Psychiatry* 55(9): 844–845

# Soft Tissue Augmentation

Cheryl M. Burgess

## Core Messages

- Facial aging is a growing concern among individuals in their 30s, 40s, and 50s and is driving increased demand for new products and techniques.
- Soft tissue augmentation is the fastest-growing segment among plastic and dermatologic cosmetic procedures and is one of the few cosmetic procedures that can be used in all skin types (Fitzpatrick I–VI).
- Soft tissue fillers and microimplants can be permanent, semipermanent, or temporary.
- Natural soft tissue filler materials are derived from sources that include bovine, porcine, human (autologous and cadaver), and recombinant bacteria.
- Synthetic soft tissue filler materials include silicone oil, expanded polytetrafluoroethylene (ePTFE), synthetic calcium hydroxylapatite, poly-L-lactic acid (PLA), and polymethylmethacrylate (PMMA).

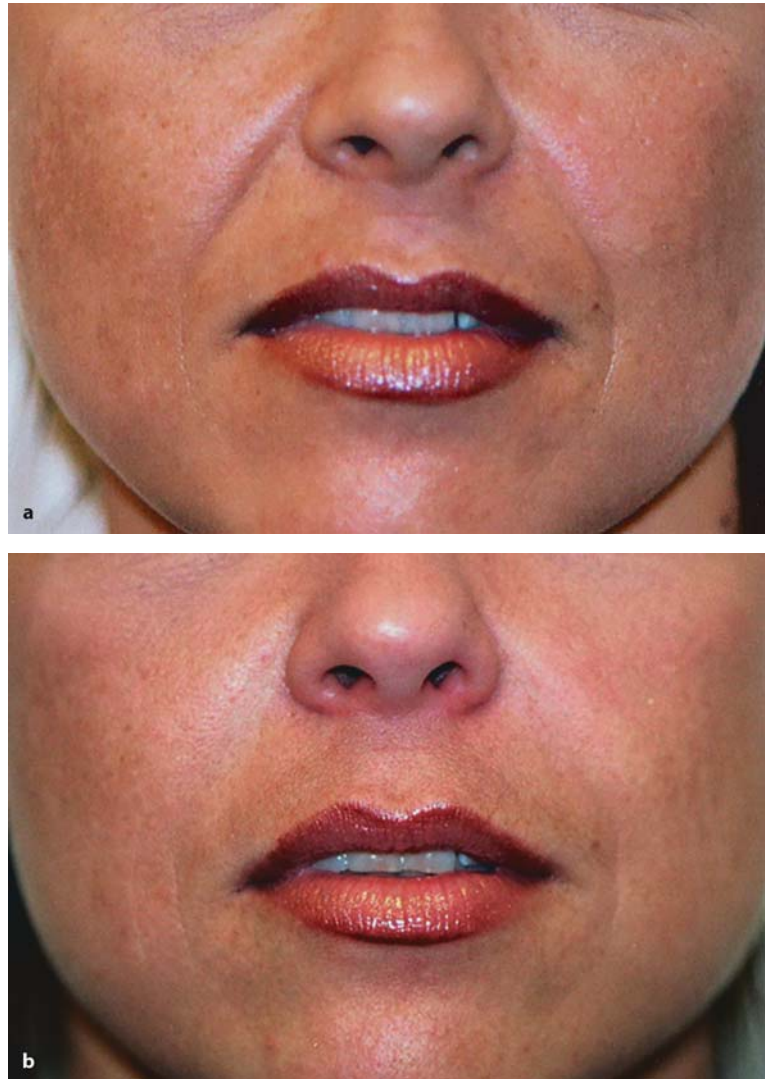## Contents

<b>6.1</b>	<b>Introduction</b>	94
6.1.1	Overview of Common Injectable Fillers	96
6.1.1.1	Fat	96
6.1.1.2	Autologous	96
6.1.1.3	Cadaver-Derived	96
6.1.1.4	Collagen	96
6.1.1.5	Hyaluronic Acid	97
6.1.1.6	Poly-L-lactic Acid	97
6.1.1.7	Silicone Oil	97
<b>6.2</b>	<b>Scientific Background</b>	97
6.2.1	Autologous Material	97
6.2.1.1	Fat Transfer	97
6.2.1.2	Fat Autograft Muscle Injection	97
6.2.1.3	Cultured Human Fibroblasts	97
6.2.2	Cadaver-derived Implants	98
6.2.2.1	Acellular Allogeneic Dermis	98
6.2.2.2	Injectable Microparticulate Acellular Allogeneic Dermis	98
6.2.2.3	Lyophilized Human Particulate Fascia Lata	98
6.2.3	Temporary	99
6.2.3.1	Animal-Based Collagen	100
6.2.3.2	Non-Animal-Based Collagen	102
6.2.3.3	Hyaluronic Acid	103
6.2.3.4	Poly-L-lactic Acid	103
6.2.4	Semipermanent	104
6.2.4.1	Synthetic Calcium Hydroxylapatite Microspheres Suspended in Aqueous Polysaccharide Gel	104
6.2.5	Permanent	104
6.2.5.1	Polymethylmethacrylate Microspheres in Denatured Bovine Collagen	104
6.2.5.2	Silicone Oil	105
6.2.6	Implants	106
6.2.6.1	Expanded Polytetrafluoroethylene	107
6.2.6.2	Gore-Tex	107
6.2.6.3	Dual-Porosity Expanded Polytetrafluoroethylene	107
<b>6.3</b>	<b>Indications</b>	107
6.4	Patient Selection	107
6.4.1	Contraindications	108
6.4.2	Specific Product Contraindications	108
	<b>References</b>	108

## 6.1 Introduction

Many options are available to the individual wishing to ameliorate such facial signs of aging as rhytids (fine lines, creases, and wrinkles). In response to ongoing demand, research is focusing on new and better ways to do so. In consultation with the dermatologist or cosmetic surgeon, the patient can explore these options in detail and arrive at an individualized plan. In some instances, combining procedures may be an excellent choice.

Over time, senescence of the skin, elastosis, decreased collagen, and lipoatrophy lead to the loss of the face's youthful turgor and tightness, resulting in the appearance of radiating vertical lines around the lips and mouth, deepening and furrowing of the nasolabial folds, and the development of a longer and flatter upper lip leading to a thinner lip vermilion border. These changes begin to appear in a person's late 20s or early 30s, and they may become a growing concern for individuals in their 30s, 40s, and 50s [1]. People are living longer and want to achieve their best appearance for their entire life, and



**Fig. 6.1a,b.**  
Dermal enhancement using Restylane. **a** Before. **b** After  
(Courtesy of Z. Paul Lorenc, M.D., F.A.C.S.)



soft tissue augmentation is one of the few cosmetic procedures that can be used in all skin types (Fitzpatrick I–VI) [2, 3]. Figures 6.1a,b and 6.2a–d are before-and-after photos that demonstrate the results from soft tissue augmentation. This chapter focuses on procedures and products to ameliorate the fine lines, creases, and wrinkles associated with age and exposure to the elements as well as the process of re-volumizing the face.

For the individual desiring to rejuvenate his or her face by treating perioral signs of aging, there are many options available, including use of botulinum toxin, injectable fillers, microimplants, and combination therapy. These include soft tissue fillers that may be synthetic, animal-derived, human-derived, or autologous—the latter harvested from the patient's own vein or fat. The primary action of these products and tech-

niques is to induce collagen formation and/or occupy volume and space. The dermatologist or cosmetic surgeon can assess the patient's needs and desires and propose a course of treatment from among available products and techniques.

Fillers are categorized as permanent, semi-permanent, and temporary. The majority of injectable fillers are temporary, lasting from several weeks to several months, although some reportedly last 9–12 months. Many of these processes require ongoing treatment to maintain the desired appearance. Injectable microimplants are, for the most part, semipermanent, although some newer products containing microspheres are temporary. Synthetic implants are permanent, remaining in place unless removed surgically; human-derived or cadaver-derived implants, while long lasting, do not ap-

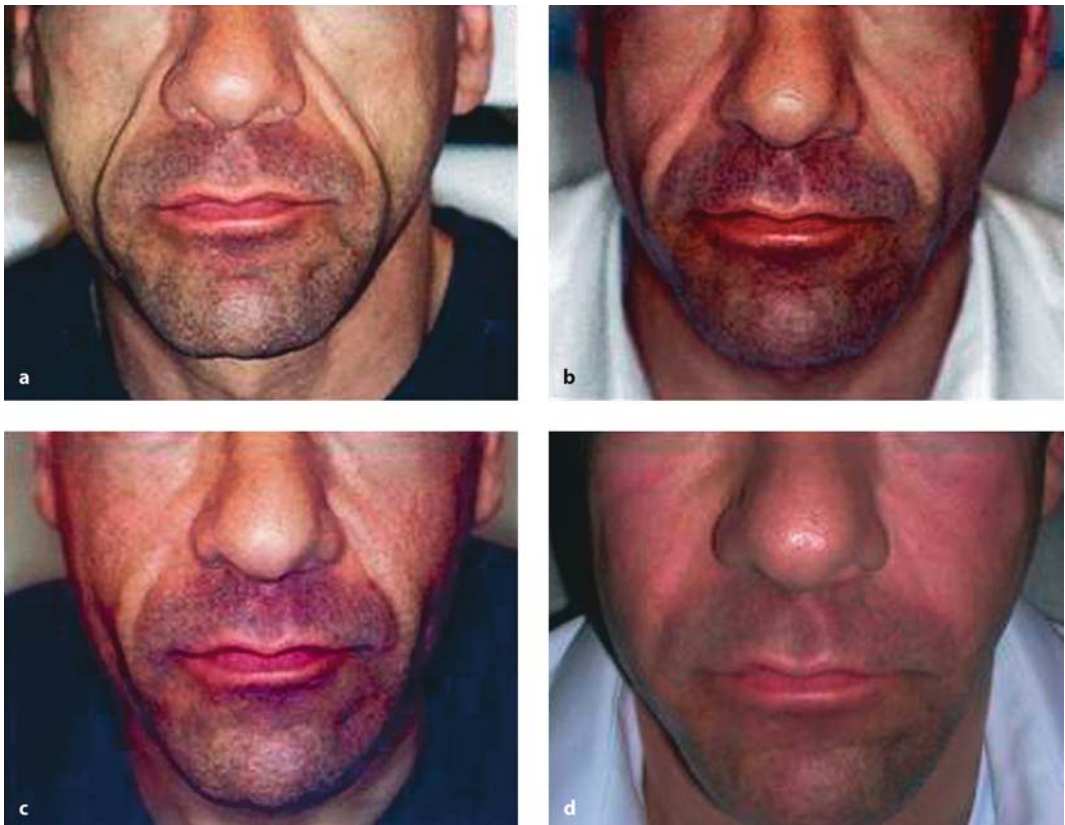

Fig. 6.2a–d. Lipoatrophy using Sculptra



pear to last indefinitely. Finally, autologous implants and injectables vary in their longevity.

Each type of soft tissue filler or implant has its own advantages and disadvantages. Candidates for treatment must consider factors such as product availability, treatment complexity (number of required serial treatment sessions), necessity for local anesthesia, longevity of augmentation, contraindications, allergy testing, potential complications, cost, and technical expertise required of clinicians.

General contraindications include any active disease (including diabetes) that may affect risk or outcome; disorders involving collagen, scarring, or connective tissue; lupus (dependent on type of treatment); recent treatment with isotretinoin; and clotting problems. Each type of treatment may have additional contraindications, and these are discussed in the appropriate section below.

New products and techniques are being developed at a rapid pace in numerous countries. Clinical trials are in progress for many products. Product availability varies widely, and a variety of products are being used off-label. Dermatologists and cosmetic surgeons should regularly review treatment options to provide the best care possible for patients.

## 6.1.1 Overview of Common Injectable Fillers

### 6.1.1.1 Fat

Fat transfer remains a popular treatment option because there is no cost for materials and no risk of rejection. The source of the fat is a metabolically resistant part of the body, usually the lateral hip, abdomen, or flank. The donor site is infused with tumescent local anesthesia for collection of the adipose tissue, which is aspirated or manually excised and placed in storage. At a later date, a saline suspension of this tissue is injected into the cutaneous layer for treating lipoatrophy, rhytids, and folds [4].

Fat autograft muscle injection (FAMI) is a modification of existing methods for fat trans-

fer that creates a natural living graft that is long lasting or permanent [5]. Unlike traditional fat-grafting methods, in this procedure, fat is injected solely into the muscle and immediately adjacent tissues in the direction of the muscle fibers. This allows immediate incorporation into the atrophied space and subsequent hypertrophy of the muscle. Seven specifically sized cannulas are used for each area to be injected. Fat injected into the muscle has greater longevity than when it is injected into the cutaneous layer. Preliminary findings reported that 30% of patients followed for 5 years retained at least 80% of the FAMI graft [6].

### 6.1.1.2 Autologous

Autologous collagen is derived from the patient's own skin. The skin is usually removed during surgery that involves tissue excision, such as abdominoplasty. The collagen is processed in a laboratory and kept frozen until ready for injection, which occurs within 48 h of harvesting [7]. Because the collagen is autologous, no allergy test is required [4, 8].

### 6.1.1.3 Cadaver-Derived

These implants are derived from donor tissue obtained at the time of death. The cadaver's dermis, muscle fascia, or tissue-derived collagen is harvested and brought to a special laboratory for testing and processing where its immunogenic components removed.

### 6.1.1.4 Collagen

Injectable collagen has been used since the early 1980s to improve facial rhytids. Collagen is a naturally occurring fibrous protein found in humans and animals. Injection of collagen into rhytids will replenish collagen matrix and restore the face to a more youthful appearance. In general, the effect will last from several weeks to several months [9].

### 6.1.1.5 Hyaluronic Acid

Hyaluronic acid is a natural cosmetic dermal filler that restores volume to moderate to severe facial rhytids and folds in the skin. Hyaluronic acid is found in all tissues of human and animal species and is biodegradable and biocompatible. Hyaluronic acid is currently obtained from biofermentation or from the combs of roosters. Depending on the source, allergy testing may be required. Current studies show that hyaluronic acid products last twice as long as collagen-based filler products.

### 6.1.1.6 Poly-L-lactic Acid

Poly-L-lactic acid (PLA) is a sterile synthetic polymer that is biodegradable and biocompatible. Once injected into the deep dermis, the PLA microparticles stimulate the formation of collagen. It has been approved in Europe since 1999 for soft tissue augmentation and is currently approved in the United States for HIV-associated lipoatrophy.

### 6.1.1.7 Silicone Oil

Silicone in the form of purified, medical grade, polydimethylsiloxane oil is considered permanent filler. It is used for the correction of moderate-depth lines and depressions. Microdroplets of silicone oil are dispersed within the dermal tissues, and fibrosis around these droplets localizes the material and provides “bulk” [10].

## 6.2 Scientific Background

### 6.2.1 Autologous Material

Materials used in autologous implants and injections are generally obtained during the course of other procedures that involve tissue excision. These include abdominoplasty, face-lift, breast reduction, breast lift, etc. The tissue is sterile-packed and frozen until it is processed for use. In theory, because the materials used in

autologous implants and injectables are from the patient’s own body, there should be no risk of rejection. In rare cases, however, problems arise. In addition, the patient’s body absorbs these natural fillers over time [8] (Table 6.1).

### 6.2.1.1 Fat Transfer

The use of autologous fat in soft tissue augmentation dates back to 1893 when Neuber reported the harvesting of blocks of free fat from the arms to reconstruct depressed facial defects. The technique was further advanced in the early 1900s by Lexer, who treated a malar depression and receding chin using single large block grafts, and by Bruning, who was the first to use a syringe to inject small cubes of surgically harvested adipose tissue into the subcutaneous space. Although these methods had excellent short-term results, the inability to prevent significant resorption of the transplant led to the investigation of other techniques for soft tissue augmentation [8].

Currently, fat transfer is a temporary treatment that lasts from several months to several years. During injection, an overcorrection is made, as resorption of saline occurs [11]. Advances in methodology, including, for example, reinjection of fat suspended in the patient’s plasma, have increased the longevity of the procedure.

### 6.2.1.2 Fat Autograft Muscle Injection

The FAMI technique uses specialized, anatomically curved cannulas. Donor sites of fat include the buttocks, lateral thighs, abdomen, or medial knees [5].

### 6.2.1.3 Cultured Human Fibroblasts

Cultured human fibroblasts (example: Autologen) from the patient’s own body are reinjected into the patient where they work as a biocatalyst. The effect reportedly is indefinite, although the collagen is susceptible to natural aging. The use of cultured human fibroblasts is in

**Table 6.1.** Autologous fillers

Filler	Indications	Treatment	Complications and potential adverse reactions
Fat transfer		Fat transfer: Injected into the subcutaneous fat layer and/or muscle. Overcorrection is necessary	Prolonged edema, bruising, under-/ overcorrection, migration, clumping, irregularities, fat necrosis, and infection [10]
Fat autograft muscle injection (FAMI)		FAMI: The face requires anesthetizing with a series of nerve blocks. Tiny puncture wounds are made at the superior central forehead at the hairline, zygomatic arches, oral commissures, and lateral chin. Injections are made into the muscle and immediate surrounding planes. Monthly visits may be necessary as needed. The effect is permanent or long lasting [5]	Rare complications may include swelling, bruising, infection, scarring, and dyspigmentation [5]
Autologous cultured human fibroblasts	Stimulates cutaneous collagen formation	Soft tissue defects should be overcorrected by at least 20–30%. Injections are more painful, and nerve blocks or local or topical anesthesia may be needed. A minimum of three injections are required over several weeks. Skin testing not required. Effect lasts 3–6 months [10]	No risk for disease transmission or allergic reaction because material is autologous [10]

6

the process of clinical trials in the United States [12].

### 6.2.2 Cadaver-derived Implants

A summary of cadaver-derived implants is provided in Table 6.2.

#### 6.2.2.1 Acellular Allogeneic Dermis

An acellular allogeneic dermis (example: AlloDerm) is composed of cadaveric dermis and an extracellular cell matrix that has been processed to remove immunogenic components [13].

#### 6.2.2.2 Injectable Microparticulate Acellular Allogeneic Dermis

Acellular allogeneic dermis is available in an injectable microparticulate form (example: Cytra). This preparation of collagens and elastin provide structure for cell repopulation. Preserved proteoglycans and proteins direct the patient’s own cells to initiate revascularization and cell repopulation, integrating into the patient’s own tissue.

#### 6.2.2.3 Lyophilized Human Particulate Fascia Lata

Another preparation contains lyophilized human particulate fascia lata (example: Fascian)

Table 6.2. Cadaver-derived implants

Implants	Indications	Treatment	Complications and potential adverse reactions
AlloDerm	FDA-approved for lip augmentation in the USA [14]. The allograft scaffold is also used for burn injuries and cancer excisions and to correct soft tissue defects [8]	Tiny incisions are made at both corners of the lip. An instrument is passed from one incision to the other to make a tunnel. The implant is passed from one end of the incision toward the other end [14]. Reports of longevity vary, ranging from 6–12 months to several years [4]	The major complication is overcorrection. The risk of this is minimized by the physicianfully understanding the patient's expectations [14]
Acellular allogeneic dermis Cymetra	FDA-approved for treatment of rhytids, nasolabial folds, and lips	Injection at the midreticular level is optimal until the majority of the gentian lines have been removed or the deepest plane has been reached [4]. Double allergy testing is recommended [15], and patients shown to be allergic to bovine collagen might find this preparation to be a feasible alternative. Its longevity is normally 3–6 months	Bruising, redness, swelling, and wrinkling of skin [8]
Injectable, micro-particulate acellular allogenic dermis Human cadaver tissue		Augmentation reportedly lasts longer than does bovine collagen [16].	
Fascian Lyophilized human particulate fascia lata Human cadaver tissue	FDA-approved for stimulation of cutaneous collagen formation [17]	Reports claim the effect lasts 3–6 months while the manufacturer states 6–8 months [4]	Complications may include edema, erythema, and ecchymosis, and later complications may include post-inflammatory hyperpigmentation. The larger particle sizes appear to be associated with side effects that are more persistent [4]. Painful to inject; bruising [17]

from donor cadavers. It is available in particulate and line-like sheets and must be rehydrated prior to use with saline or a saline/lidocaine mixture [8].

### 6.2.3 Temporary

Collagen serves to provide structural support for bones, skin, tendons, and blood vessels and lends stability to the body's tissues. With age, the body's collagen weakens and loses its elasticity, leading to, among other effects, the vari-

ous signs of aging. The main sources of collagen for this purpose are bovine, porcine, and human. Bovine collagen is very similar to the human molecule, with specific differences only in the end peptides (telopeptides). These regions can be removed in processing, leaving a core protein similar to that of a humans [9] (Table 6.3).

### 6.2.3.1 Animal-Based Collagen

#### Bovine Dermal Collagen Dispersed in Phosphate-Buffered Physiological Saline Containing 0.3% Lidocaine

These substances (example: Zyderm) are composed of highly purified bovine dermal colla-

Table 6.3. Temporary fillers

Implants	Indications	Treatment	Complications and potential adverse reactions
Zyderm Bovine dermal collagen dispersed in phosphate-buffered physiological saline containing 0.3% lidocaine	FDA-approved for the correction of facial rhytids, scars, and lip augmentation [10, 17]. The low-concentration filler is used to treat fine lines, rhytids, shallow scars, and thin-skinned areas, and the high-concentration filler is used to treat moderate lines, rhytids, and scars [15]	Injected intradermally. Infiltrated into the superficial papillary dermis. Requires second skin test on the contralateral arm [15]. Topical anesthesia may be required. Overcorrection is mandatory because water in the suspension is reabsorbed within 24 h after injection [10]. The average longevity of both fillers is 3–6 months [10, 18]	Bovine collagen may induce an allergic reaction [10]
Zyplast Bovine collagen cross-linked with glutaraldehyde and suspended in saline and 3 mg/ml lidocaine	FDA-approved for the correction of facial rhytids, scars, and lip augmentation [10, 17]. Often, this filler is used as a foundation in the nasolabial folds or oral commissure with non-cross-linked bovine collagen injected as an overlay. Cross-linked bovine collagen is also used to enhance the vermilion border, but it should be avoided in treatment of fine lines or in the glabella [18]	Placed into the midreticular or deep reticular dermis at the dermal subcutaneous interface. Requires second skin test on the contralateral arm. Topical anesthesia may be required. Overcorrection is mandatory because water in the suspension is reabsorbed within 24 h after injection [10]	Bovine collagen may induce an allergic reaction [10]
CosmoDerm Human-based collagen isolated from human fibroblast cell cultures	Used for superficial skin defects [4]. FDA-approved for rhytids and scars [17]	May require pretreating with topical anesthetic cream [9]. Allergy test not required. Longevity is generally 3–6 months	Short-term complications may include mild swelling, erythema, bruising, and rarely, palpable lumps [9]
CosmoPlast Human-based collagen cross-linked with glutaraldehyde	Reserved for deeper lines but can be used off-label for the lips. FDA-approved for rhytids and scars [17]	May require pretreating with topical anesthetic cream [9]. Because of the low incidence of sensitivity, an allergy test is not required. Longevity is generally 3–6 months	Short-term complications may include mild swelling, erythema, bruising, and rarely, palpable lumps [9]



Table 6.3. Continued

Implants	Indications	Treatment	Complications and potential adverse reactions
Restylane Hyaluronic acid derived from bacterial biofermentation process	Perlane: 20 mg/ml stabilized hyaluronic acid with approximately 10,000 gel particles/ml is recommended for nasolabial folds and lips (fullness and pouting)	Perlane: Injected into the deep layer of the dermis and/or surface layer of the subcutis	Temporary skin reactions [23], including redness, swelling, localized granulomatous reactions, bacterial infection, acneiform, and cystic lesions. Hypersensitivity, although declining after introduction of more purified hyaluronic acid raw material [24]. However, no long-range problems [9]
	Restylane: 20 mg/ml stabilized hyaluronic acid with approximately 100,000 gel particles/ml is recommended for rhytids such as glabellar, oral commissures. Lips: fullness, pouting, and vermilion border	Restylane: Injected into the mid part of the dermis	
	Restylane fine lines: 20 mg/ml stabilized hyaluronic acid with approximately 200,000 gel particles/ml is recommended for thin superficial lines, such as worry lines, periorbital lines, perioral lines	Restylane fine lines: Injected into upper part of the dermis	
	FDA-approved [9]	None of the three should be overcorrected. Various injection techniques apply, depending on the type of correction and product used. These techniques include linear threading, serial puncture, fanning, and cross-hatching [23]	
Juvederm [18, 24, 30] Viscoelastic, nonanimal hyaluronic acid gel	18 mg/g, designed for the superficial dermis, specifically for fine lines and rhytids	The first is designed for injection in the superficial dermis, the second is designed for injection in the mid dermis, and the third is designed for injection in the mid to deep dermis. Not permanent. Eventually absorbs into the body; typically last 3–6 months.	Temporary skin reactions [23] including redness, swelling, localized granulomatous reactions, bacterial infection, acneiform, and cystic lesions. Hypersensitivity, although declining after introduction of more purified hyaluronic acid raw material [24]. However, no long-range problems [9]
	24 mg/g, designed for the mid dermis, specifically for deeper rhytids		
	30 mg/g, designed for the mid to deep dermis, specifically for deeper furrows such as nasolabials and for lip and cheek augmentation. Not available in the USA. Outside the USA, approved for a wide range of facial applications, from lip augmentation and superficial lines to frown lines and deep rhytids [25]		

Table 6.3. Continued

Implants	Indications	Treatment	Complications and potential adverse reactions
Hylaform Viscoelastic hyaluronic acid gel from rooster combs	FDA-approved for cosmetic use	May require local anesthetic or a regional block for pain. May require skin testing because of avian source. Immediate results, effect lasts 2–3 months [17]	Delayed inflamma- tory skin reactions have been reported [23]
Sculptra/New-Fill Poly-L-lactic acid	FDA-approved for use in absorbable suture material and treatment of HIV-asso- ciated lipoatrophy. FDA ap- proval pending for the treat- ment of fine lines, rhytids, and more marked furrows or creases, as well as for the augmentation of the tissue volume in certain areas of the face (cheek bones, cheek depressions, chin, etc.) [17]	Correct placement in the deep dermal and/or deep dermal subcutaneous plane is impor- tant; too shallow and visible nodules and/or blanching of the skin occurs [26]. Takes effect in 4–6 weeks, lasts 12–18 weeks [17]	Infection, allergic reaction, and in- flammatory granulomas [27]
Poly-L-lactic acid			Injection site reac- tions. Rare, nonvis- ible nodules [17]

gen that has been dispersed in phosphate-buffered physiological saline containing 0.3% lidocaine [10, 18]. Concentrations include 35 mg/ml and 65 mg/ml of purified bovine dermal collagen.

### Bovine Collagen Cross-Linked with Glutaraldehyde and Suspended in Saline and 3 mg/ml Lidocaine

Another injectable bovine collagen (example: Zypplast) is cross-linked with glutaraldehyde and suspended in saline and 3 mg/ml lidocaine. Cross-linking with glutaraldehyde adds strength and makes the collagen more resistant to proteolytic degradation. The implant will retain its integrity and its inherent water content to a greater degree than is the case for non-cross-linked bovine collagen [18].

### 6.2.3.2 Non-Animal-Based Collagen

#### Human-Based Collagen Isolated from Human Fibroblast Cell Cultures

Highly purified human-based collagen (example: CosmoDerm) is dispersed in phosphate-buffered physiological saline containing 0.3% lidocaine. The source material is isolated from human fibroblast cells grown under controlled laboratory conditions. Two forms of this human-based collagen are available and differ by the amount of collagen contained in the preparation [4].

#### Human-Based Collagen Cross-Linked with Glutaraldehyde

Another highly purified human-based collagen (example: CosmoPlast) is cross-linked with

glutaraldehyde and dispersed in phosphate-buffered physiological saline containing 0.3% lidocaine and is used for deeper defects.

### 6.2.3.3 Hyaluronic Acid

Hyaluronic acid is a polysaccharide, glycosaminoglycan, that is chemically identical across all species and tissue types [19]. Hyaluronic acid was first used commercially in 1942 when Endre Balazs applied for a patent to use it as a substitute for egg white in bakery products [20]. It plays an important role in giving volume to the skin, shape to the eyes, and elasticity to the joints. As humans age, cells lose their ability to produce hyaluronic acid, and the skin becomes drier, thinner, and looser, leading eventually to wrinkling, among other changes.

Two main sources of hyaluronic acid have been developed to create a filling agent able to correct moderate rhytids and folds and augment lips: (1) nonanimal hyaluronic acid derived from bacteria in a biofermentation process, and (2) hyaluronic acid from the combs of roosters. Its ability to bind large volumes of water makes hyaluronic acid attractive for dermal implantation [21]. Although the effect of hyaluronic acid is temporary, it is very long lasting [8]. Hyaluronic acid is cross-linked with ester and ether linkages to stabilize the molecule for dermal purposes. The amount of cross-linking of the molecule affects biocompatibility of hyaluronic acid: Less cross-linking of the molecule achieves greater biocompatibility.

#### Hyaluronic Acid Derived from Bacterial Biofermentation Process

Several preparations of nonanimal hyaluronic acid (example: Restylane) are derived from *Streptococcus* bacteria in a biofermentation process. Three forms differ in terms of concentration, volume, needle size, and recommended usage [9]. Restylane contains hyaluronic acid particle size of 200  $\mu\text{m}$  and 1% cross-linking; 20 mg/ml hyaluronic acid is cross-linked with ester and ether linkages to stabilize the molecule. Some theorize that the less cross-linking

of molecules, the more biocompatible the hyaluronic acid.

In a randomized, double-blind, multicenter comparison of the efficacy and tolerability of nonanimal hyaluronic acid versus bovine collagen cross-linked with glutaraldehyde for the correction of nasolabial folds, it was shown that less injection volume was required for “optimal cosmetic result” with hyaluronic acid gel than with bovine collagen. Moreover, both patients and investigators judged hyaluronic acid more effective in maintaining cosmetic correction [22].

#### Viscoelastic, Nonanimal Hyaluronic Acid Gel Derived from Bacterial Biofermentation

Another family of products containing a viscoelastic nonanimal hyaluronic acid gel (example: Juvederm) is available in three different concentrations (18 mg/ml, 24 mg/ml, and 30 mg/ml) to address different correction needs. Hyaluronic acid gel is eventually absorbed into the body.

#### Viscoelastic Hyaluronic Acid Gel from Rooster Combs

Another hyaluronic viscoelastic gel contains hyaluronic acid derived from the combs of roosters (example: Hylaform). Hylaform contains 5.5 mg/ml hyaluronic acid with a particle size of 500  $\mu\text{m}$ . It has 20% cross-linking as a result of using glutaraldehyde and vinyl sulfone for hyaluronic acid stabilization. According to the manufacturer, the product's high molecular weight makes it more viscous and longer lasting than the hyaluronic acid produced from bacteria.

### 6.2.3.4 Poly-L-lactic Acid

The vial of dry lactic acid monomers is reconstituted with bacteriostatic water to form the PLA (example: Sculptra/New-Fill). When in-

jected into the deep dermis or dermal-subcutaneous plane, PLA causes an immediate physical improvement to the appearance. The PLA hydrogel is slowly degraded into lactic acid microspheres and carbon dioxide, thus leaving behind the crystals to stimulate collagen and non-allergic granulomatous reaction leading to dermal thickening.

## 6.2.4 Semipermanent

A summary of semipermanent fillers is provided in Table 6.4.

### 6.2.4.1 Synthetic Calcium Hydroxylapatite Microspheres Suspended in Aqueous Polysaccharide Gel

Calcium hydroxylapatite has been safely used for many applications, including dental work, reconstruction, tissue-marking orthopedics, bone repair, and in block form for cosmetic applications such as cheek, jaw, cranial, and chin implants [4].

In general, calcium hydroxylapatite works by creating a stable scaffold in which soft tissue can grow. Calcium hydroxylapatite (example:

Radiesse) is injected by threading the solution into the deep dermis where the microspheres are held in place until the product is resorbed and collagenation occurs. In this process, fibroblasts build a non-scar-tissue type of collagen, thus creating volume in the area under treatment [4].

## 6.2.5 Permanent

A summary of permanent fillers is provided in Table 6.5.

### 6.2.5.1 Polymethylmethacrylate Microspheres in Denatured Bovine Collagen

This synthetic implant (example: Artecoll/Artefill) is composed of polymethylmethacrylate (PMMA) microspheres suspended in 3.5% denatured bovine collagen mixed with 0.3% lidocaine. PMMA has been used in medical implants for many years, and it is found in numerous products today. The PMMA is formulated into microspheres and mixed with denatured bovine collagen and lidocaine in a phosphate-buffered saline solution. PMMA is an inert substance, well tolerated by the body, and reports of allergic reactions to it are rare [18, 28].

**Table 6.4.** Semipermanent filler

Implants	Indications	Treatment	Complications and potential adverse reactions
Radiesse/ Radiesse Synthetic calcium hydroxylapatite microspheres suspended in polysaccharide gel	FDA-approved only for vocal cord augmentation and urinary incontinence [17]	Injected into the subdermis. Intradermal placement can result in swelling, pain, persis- tent erythema, and visible or palpable granules. Slight over- correction is recommended. Massage area once the injec- tion is completed. Repeat injec- tions 1–3 months after the initial treatment. Skin testing is mandatory [8, 10]	Pruritus or hypertrophic- scarring can occur and im- plantation site allergic reac- tions and granulomas aqueous may occur. Removal of calcium hy- droxylapatite is not easy. If excessive collagen produc- tion is observed, it can be dealt with using corticoster- oid injections [4]

Table 6.5. Permanent fillers

Implants	Indications	Treatment	Complications and potential adverse reactions
Artecoll/Artefill Polymethylmethacrylate microspheres in denatured bovine collagen	Indicated for the correction of facial rhytids and scars and lip augmentation [10]. It is useful especially for correcting depressions and deeper creases [18, 28]. FDA approval pending US clinical testing	Injected into the junction of the dermis and the subcutaneous space using a tunneling technique in which the material is injected as the needle is withdrawn. Use of a small needle often gives a more even result. Overcorrection is not recommended, and it may take several sessions to obtain the desired correction [18, 28]. Repeat treatment every 6 weeks until adequate augmentation [10]. It is used for the correction of moderate-depth lines and depressions [4]. An allergy test is required because bovine collagen is used as a carrier [18, 28]	May cause inflammation, induration, discoloration, ulceration, migration, and formation of granulomas [10, 18, 28]
Silskin AdatoSil 5000 Silikon 1000 Silicone Oil	FDA-approved for ocular medical purposes. The FDA has not approved silicone oil for cosmetic use in the USA. However, it is used in Europe, Mexico, and some parts of Canada for cosmetic purposes, and off-label use within the USA does occur. It is used for the correction of moderate-depth lines and depressions. Silicone has been approved by the FDA for use in treatment of retinal detachment and/or hemorrhage [4]	Microdroplets of silicone oil are dispersed within the dermal tissues, and fibrosis around these droplets localizes the material and provides "bulk." No allergy testing is required as silicone oil in small amounts is well tolerated [4]	Risks of infection, generally due to granuloma formation as the silicone becomes encapsulated as a foreign body in a chronic inflammatory reaction. Several other disadvantages exist as well, including the risk of possible migration to other organs and the lymph nodes [4]

### 6.2.5.2 Silicone Oil

Silicone compounds must be synthesized because they do not naturally exist. Silicone oil varies in chemical structure, physical properties, purity, sterility, and biocompatibility. Silicone oils used for medical purposes (example: Silikon 1000) contain long polymers of dimethylsiloxanes. As opposed to use in manufactur-

ing, etc., silicone oil used in medical applications should undergo several additional steps of purification and testing. Serious complications can result from the use of adulterated or impure silicone oils. In fact, impurities present in silicone oil can cause granulomas up to 11 years after implantation [8].

Viscosity of silicone oil is measured in centistokes (cs), a unit of kinematic viscosity. Higher viscosity is denoted by larger centistoke



values. For example, Silikon 1,000 has a viscosity of 1,000 cs. Two silicone oil formulations have been FDA-approved for ophthalmologic purposes but not for cutaneous use. In fact, in certain states in the United States, it is illegal to inject silicone oil into human skin. However, one formulation, PMS-350 (viscosity of 350 cs), has European approval for treatment of glabellar lines, nasolabial folds, perioral lines, lip augmentation, atrophic disorders, and scars [8].

Silicone in the form of purified, medical-grade polydimethylsiloxane oil is considered permanent filler. Silicone oil is chemically well tolerated in small amounts [4, 8].

### 6.2.6 Implants

A summary of implants is provided in (Table 6.6).

Numerous materials have been used in the development of injectable microimplants. These include calcium hydroxylapatite microspheres, hydrophilic polyacrylamide gel, PMMA microspheres, solid, vulcanized methylpolysiloxane microspheres suspended in polyvinylpyrrolidone, hydroxymethylmethacrylate, and ethylmethacrylate. These all share some element of providing a “structural” framework, usually involving microspheres in a carrier, and are generally considered permanent or semipermanent.

Table 6.6. Implants

Implants	Indications	Treatment	Complications and potential adverse reactions
UltraSoft, SoftForm Expanded polytetrafluoroethylene	Indicated for subdermal soft tissue augmentation. SoftForm is used for the lip border, smile lines (nasolabial fold), and frown lines; UltraSoft is used for cheek and temple. Implants made of ePTFE are most applicable in lip enhancement, although they can also be used to ameliorate perioral rhytids [29]	Under local anesthesia, the patient has the appropriate length and width of the implant inserted subdermally via a 14- to 16-gauge angiocatheter	Appear to have a higher rate of infection than permanent injectable microimplants, but the problems can be corrected more easily [29]
Gore-Tex Dual-porosity expanded polytetrafluoroethylene	FDA-approved for vascular grafts, implant material, and soft tissue repair	Under local anesthesia, the patient has the appropriate length and width of the implant inserted subdermally via a 14- to 16-gauge angiocatheter	Complications range from transient bruising and swelling to infection of the implant site, formation of fistula, and implant extrusion, among others. These more serious complications are considered less common
Advanta Facial Implant Dual-porosity expanded	FDA-approved to fill deep wrinkles or folds or to enhance, augment, or repair soft tissues of the facial area, such as the lips [25]	Requires local anesthesia [25]	Low incidence of complications [25]

### 6.2.6.1 Expanded Polytetrafluoroethylene

Synthetic implants are usually made from expanded ePTFE, a nonreactive, nontoxic polymer that has been safely used in medical implants for many years for vascular grafts and soft tissue reconstruction. Depending on its design (tubular or in sheets) and varying porosities, the implant can feel anywhere from slightly firm to quite soft. Such implants are permanent [29].

In a study comparing the biomechanical effects of ePTFE implant structure on the stability of a soft tissue implant, the authors used an *in vivo* porcine model to look at implant retention, fixation strength, and removability in both tubular and solid-strip ePTFE implants. They found that tubular implants facilitated growth of soft tissue through the tube's lumen, which increased the attachment to surrounding soft tissues, increasing fixation strength and decreasing extrusion rate but still allowing easy removal. The authors concluded that these properties might improve clinical applications in facial implantation [29].

### 6.2.6.2 Gore-Tex

Gore-Tex implants are composed of sterile, medical-grade ePTFE. The Gore-Tex implant has pores that are 10–30  $\mu\text{m}$  in diameter that allow the body's own tissue to attach itself to the implant. Gore-Tex implants are available in both tubular form and in sheets. Gore-Tex implants are extremely strong and are not likely to tear or disintegrate. The implant is permanent but reversible. Gore-Tex implants are not widely used.

### 6.2.6.3 Dual-Porosity Expanded Polytetrafluoroethylene

One of the newer implants containing dual-porosity ePTFE (example: UltraSoft, SoftForm) consists of a soft, high-porosity center integrated with a smooth, medium-porosity outer sur-

face layer, and it has the benefit of readily accepting a patient's collagen. As a result, a more natural tissue healing response may be achieved. This facial implant has a low incidence of complications. The implant is permanent but reversible.

In a study comparing the biomechanical effects of ePTFE implant structure on the stability of a soft tissue implant, the authors used an *in vivo* porcine model to look at implant retention, fixation strength, and removability in both tubular and solid-strip ePTFE implants. They found that tubular implants facilitated growth of soft tissue through the tube's lumen, which increased the attachment to surrounding soft tissues, increasing fixation strength and decreasing extrusion rate but still allowing easy removal.

## 6.3 Indications

Soft tissue augmentation is indicated for use in rhytids, creases, scars, and lip augmentation. Many are approved for nasolabial folds. See Tables 6.1, 6.2, 6.3, 6.4, 6.5, and 6.6 for specific indications.

## 6.4 Patient Selection

Soft tissue augmentation is suitable for all skin types (Fitzpatrick I–VI). Patients should be counseled about temporary augmentation to manage expectations and maximize satisfaction. Additionally, recommendations of temporary soft tissue augmentation in regard to aging changes and consideration of permanent augmentation for scars should be addressed [30]. Common contraindications of dermal-enhancing procedures are listed below. Persons on certain medications or having the following conditions may not be good candidates for dermal enhancement.

### 6.4.1 Contraindications

Contraindications for soft tissue augmentation are:

- Isotretinoin for 6 months prior or following treatment because it may increase chances of keloid-like scarring
- Collagen/scarring/connective tissue disorders
- Lupus for patients seeking bovine or porcine collagen. Other products may cause flare-ups as well.
- Active diseases may affect outcome or increase risks
- Diabetes may affect outcome or increase risks
- Coagulation problems
- Excessive oral plaque or dental abscesses
- Herpes labialis
- Pregnant or lactating women
- Psychological conditions

### 6.4.2 Specific Product Contraindications

Following is a list of contraindications to specific products used for soft tissue augmentation:

- Bovine dermal collagen (Zyderm, Zyplast): adverse reaction to allergy test, the presence of severe allergies manifested by a history of anaphylaxis, or of multiple severe allergies. In addition, patients with known lidocaine hypersensitivity should not be injected with these fillers, nor should patients with a history of allergies to any bovine collagen product. Contraindicated for use in the glabellar region

- Injectable microparticulate acellular allogenic dermis (Cymetra): autoimmune connective-tissue disease, infected or nonvascular surgical sites unless specifically prescribed by a physician, patients sensitized to the specific antibiotics used in the manufacture of this preparation, and in periocular line correction or glabellar contouring
- Human-based collagen cross-linked with glutaraldehyde (CosmoPlast/CosmoDerm): severe allergies manifested by a history of anaphylaxis and in patients with known lidocaine hypersensitivity. Contraindicated for use in the glabellar region, breast augmentation, and for implantation into bone, tendon, ligament, or muscle
- Viscoelastic, nonanimal hyaluronic acid (Juvederm): autoimmune diseases, pregnancy, lactation, allergies to hyaluronic acid, and direct sunlight or intense heat on the treatment area for several days postinjection.
- Hyaluronic acid (Hylaform): poultry allergy

### References

1. Donofrio L (2000) Fat distribution: a morphologic study of the aging face. *Dermatol Surg* 26:1107–1112
2. Guttman C (2004) A generation speaks: dermatology answers growing desire to fight aging skin. *Dermatology Times* p 56–60
3. Guttman C (2004) Advances in anti-aging: new techniques technology should match demand. *Dermatology Times*
4. Bisaccia D, Scarborough D (1992) The esthetic correction of the aging mouth. *Cosmetic Dermatol (11)*:8–11
5. Schwanke J (2003) Emerging technique restores volume: Fat autograft muscle injection deemed long-lasting natural filler. *Dermatology Times* p 84
6. Fat Autograft Muscle Injection (FAMI) 2003 Draft (2003). In: Thompson advanced therapeutics communications
7. West TB, Alster TS (1998) Autologous human collagen and dermal fibroblasts for soft tissue augmentation. *Dermatol Surg* 24(5):510–512

8. Klein AW, Elson ML (2000) The history of substances for soft tissue augmentation. *Dermatol Surg* 26(12):1096–1105
9. Glogau R, Narins R, Weiss R (2004) Advances in cosmetic procedures. Fall Clinical Dermatology Conference Supplement Proceedings. Supplement to skin and aging 20–27
10. Cheng JT, Perkins SW, Hamilton MM (2002) Collagen and injectable fillers. *Otolaryngol Clin North Am* 35(1):73–85
11. Scarborough D, Bisaccia E (1997) CO<sub>2</sub> laser resurfacing with fat grafting for rhytids and acne scars. *Cosmetic Dermatol* (10):7–12
12. Isolagen anti-aging product scar tissue treatment for wrinkle scar treatment acne scar therapy—trials scar removal 2004
13. Rohrich RJ et al (2000) Early results of vermilion lip augmentation using acellular allogeneic dermis: an adjunct in facial rejuvenation *Plast Reconstr Surg* 105(1):409–418
14. AlloDerm lip augmentation: Complications 2004
15. Klein AW (1989) In favor of double testing. *J Dermatol Surg Oncol* 15(3):263
16. Warmuth L et al (1998) Correction of the aging mouth. *Cosmetic Dermatol* 11(12):9–12
17. Sculptra Advisory Board briefing document
18. Elson M (1999) Soft tissue augmentation techniques: Update on available materials. *Cosmetic Dermatol* (May):13–15
19. Larsen NE et al (1993) Hylan gel biomaterial: dermal and immunologic compatibility. *J Biomed Mater Res* 27(9):1129–1134
20. Uneet Co, Inc. (2002) Synthovial 7 with medical grade hyaluronic acid for joint lubrication
21. Lupton JR, Alster TS (2000) Cutaneous hypersensitivity reaction to injectable hyaluronic acid gel. *Dermatol Surg* 26(2):135–137
22. Narins RS et al (2003) A randomized double-blind multicenter comparison of the efficacy and tolerability of Restylane versus Zyplast for the correction of nasolabial folds. *Dermatol Surg* 29(6):588–595
23. Lowe NJ et al (2001) Hyaluronic acid skin fillers: adverse reactions and skin testing. *J Am Acad Dermatol* 45(6):930–933
24. Friedman PM et al (200) Safety data of injectable nonanimal stabilized hyaluronic acid gel for soft tissue augmentation. *Dermatol Surg* 28(6):491–494
25. Beautysurge.com (2004) Cosmetic plastic surgery information. <http://www.beautysurge.com>. Cited 18 Nov 2004
26. Valantin MA et al (2003) Poly-lactic acid implants (New-Fill) to correct facial lipoatrophy in HIV-infected patients: results of the open-label study VEGA. *AIDS* 17(17):2471–2477
27. Saylan Z (2003) Facial fillers and their complications *Aesthetic Surg J* 23(3):221–224
28. Lemperle G, Romano JJ, Busso M (2003) Soft tissue augmentation with Artecoll: 10-year history indications techniques and complications. *Dermatol Surg* 29(6):573–587
29. Greene D, Pruitt L, Maas CS (1997) Biomechanical effects of e-PTFE implant structure on soft tissue implantation stability: a study in the porcine model. *Laryngoscope* 107(7):957–962
30. Tolleth H (1985) Long-term efficacy of collagen. *Aesthetic Plast Surg* 9(2):155–158

# Laser Skin Resurfacing

Tina S. Alster, Seema Doshi

## Core Messages

### Ablative laser skin resurfacing:

- Significant improvement of facial rhytids, atrophic scars, and various epidermal/dermal lesions is possible with pulsed high-energy CO<sub>2</sub> or erbium laser tissue ablation.
- The rate of complications is related to operator experience/technique and patient variables, especially in darker skin types (Fitzpatrick skin type IV–VI).
- Transient hyperpigmentation is a common postlaser side effect that can be treated with a variety of topical bleaching or peeling agents.

### Nonablative laser skin resurfacing:

- Multiple nonablative laser, light sources, and radiofrequency devices can lead to collagen remodeling and effect improvement of rhytids and atrophic scars.
- All nonablative systems incorporate a cooling device to protect the epidermis during laser irradiation. Side effects and complications of nonablative treatments are generally mild and transient and therefore can be used in all skin phototypes.
- Intense pulsed light treatments are most effective for irregular skin pigmentation and least effective for dermal collagen remodeling.
- Radiofrequency (RF) treatments are “color blind” and can be used to tighten skin and offer subtle collagen remodeling in all skin phototypes.

## Contents

7.1	<b>Introduction</b> . . . . .	111
7.2	<b>Ablative Laser Skin Resurfacing</b> . . .	112
7.2.1	Carbon Dioxide Laser . . . . .	112
7.2.2	Erbium:Yttrium-Aluminum-Garnet Laser . . . . .	115
7.2.3	Adverse Effects and Complications . .	117
7.3	<b>Nonablative Laser Skin Resurfacing</b> .	118
7.3.1	Intense Pulsed Light Source . . . . .	118
7.3.2	Pulsed Dye Laser . . . . .	118
7.3.3	Midinfrared Lasers . . . . .	119
7.4	<b>Nonablative Radiofrequency Technology</b> . . . . .	119
7.5	<b>Adverse Effects and Complications (Non-Ablative Lasers/Radiofrequency)</b> . . . . .	122
7.6	<b>Conclusion</b> . . . . .	122
7.7	<b>Summary</b> . . . . .	122
	<b>References</b> . . . . .	124

## 7.1 Introduction

The cutaneous application of laser technology was launched in 1959 with the development of the 694-nm ruby laser by Maiman [1]. Over the next two decades, the argon laser, used to treat vascular lesions, and the carbon dioxide (CO<sub>2</sub>) laser, used to vaporize epidermal and dermal lesions, became the focus of research and development [2]. Because these lasers yielded a high rate of hypertrophic scarring and pigmentary alteration due to excessive thermal injury to dermal tissue, their use in dermatology was limited. The theory of selective photothermolysis, developed by Anderson and Parrish in the early 1980s, literally transformed the field of



cutaneous laser surgery by delivery of targeted thermal energy [3]. Laser surgery has since continued to be refined and is now considered an excellent, often primary, treatment choice for a wide variety of cutaneous applications.

The laser–tissue interaction first studied by Anderson and Parrish is based on three fundamental principles—wavelength, pulse duration, and fluence. The wavelength of emitted laser light is absorbed preferentially by a selected tissue target, or chromophore (e.g. hemoglobin, melanin, tattoo ink, water). Energy density (fluence) must be high enough to destroy the target within a set amount of time, also called pulse duration. The pulse duration ideally should be shorter than the target chromophore’s relaxation time (defined as the time required for the targeted site to cool to one half of its peak temperature immediately after laser irradiation). Optimization of these three parameters permits delivery of maximum energy to target structures with minimal collateral thermal damage.

The early argon and carbon dioxide lasers were continuous wave (CW) lasers, emitting a constant light beam with long tissue exposure durations, resulting in widespread thermal injury. Quasi-CW mode lasers, which shutter the CW beam into short segments, provided further refinement of this technology. As the thermal relaxation times of most chromophores are short, development of pulsed laser systems,

which emit high-energy laser light in ultrashort pulse durations with relatively long time periods (0.1–1 s) between each pulse, marked a significant advancement in cutaneous laser surgery [4].

The use of lasers for aesthetic purposes has undergone exponential growth in the last decade to meet the demand for anti-aging technology. Currently, an abundance of laser and nonlaser technology exists for skin rejuvenation, scar revision, collagen tightening, and correction of cutaneous dyschromias. Treatment can be tailored to match the patient’s lifestyle and desired outcome (Table 7.1).

7

## 7.2 Ablative Laser Skin Resurfacing

### 7.2.1 Carbon Dioxide Laser

Skin resurfacing with the CO<sub>2</sub> laser remains the gold standard technology for production of the most dramatic clinical and histologic improvement in severely photodamaged and scarred facial skin [5]. It was the development of high-energy pulsed CO<sub>2</sub> systems in the early 1990s that revolutionized aesthetic laser surgery and ushered in a new decade of rapidly evolving laser technology. Producing a wavelength of 10,600 nm, the CO<sub>2</sub> laser penetrates approximately 30 μm into the skin by absorption and

**Table 7.1.** Skin resurfacing laser and other systems. *IPL* intense pulsed light, *RF* radiofrequency, *N/A* not applicable

	System types	
	Ablative	Nonablative
	CO <sub>2</sub> (10,600 nm) Erbium (2,940 nm)	Pulsed dye (585–595 nm) Nd: YAG (1,320 nm) Diode (1,450 nm) Er: Glass (1,540 nm) IPL (515–1,200 nm) RF (N/A)
Advantages	Best clinical outcomes Single procedure	No postoperative recovery Minimal risk of side effects
Disadvantages	Prolonged recovery Increased side effects	Subtle clinical effect Multiple sessions required

vaporization of water-containing tissue. Older continuous-wave CO<sub>2</sub> lasers produced an unacceptable amount of thermal destruction (up to 200 µm–2 mm beyond the target area) [6]. The new generation of pulsed and scanned CO<sub>2</sub> lasers limit this thermal damage by delivery of high-energy laser light with tissue dwell times shorter than the thermal relaxation time of the 30 µm of targeted tissue (about 1 ms). Energy densities of approximately 5 J/cm<sup>2</sup> must be applied in order to achieve tissue ablation [7]. Vaporization of very thin (20–30 µm) layers of skin occurs with each laser pass, leaving a small amount of residual thermal necrosis [8]. With each subsequent laser pass, further tissue ablation occurs, but because the area of residual thermal necrosis increases (effectively reducing the amount of tissue water), the amount of ablation with each pass diminishes until a peak of approximately 100 µm is reached [9]. Delivering more than three to four passes or use of excessive energy densities significantly increases the risk of excessive thermal injury and subsequent scarring [10].

Use of the CO<sub>2</sub> laser for skin resurfacing yields an additional benefit of collagen tightening through heating of dermal collagen. The triple helical structure of collagen is altered, resulting in shortening of the fibers by one third [11]. Persistence of this collagen contraction results, in part, from these shortened fibers serving as a scaffold for neocollagenesis. Beyond this time, wound healing and fibroblast up-regulation of immune modulating factors leading to persistent collagen remodeling may explain continued clinical improvement seen up to 1 year after the procedure [12, 13, 14].

Several CO<sub>2</sub> laser systems are available and can be separated into two distinct groups: pulsed and scanned. The high-energy pulsed CO<sub>2</sub> lasers (e.g., Ultrapulse by Lumenis, Santa Clara, CA, USA) produce single short (1 ms) pulses of very high energies (up to 7 J/cm<sup>2</sup>). Scanned laser systems (e.g., FeatherTouch) utilize a computerized scanning device to deliver the laser energy rapidly over the skin, thus limiting the tissue dwell time in any one area. A study comparing four different CO<sub>2</sub> lasers found that the pulsed systems produced the

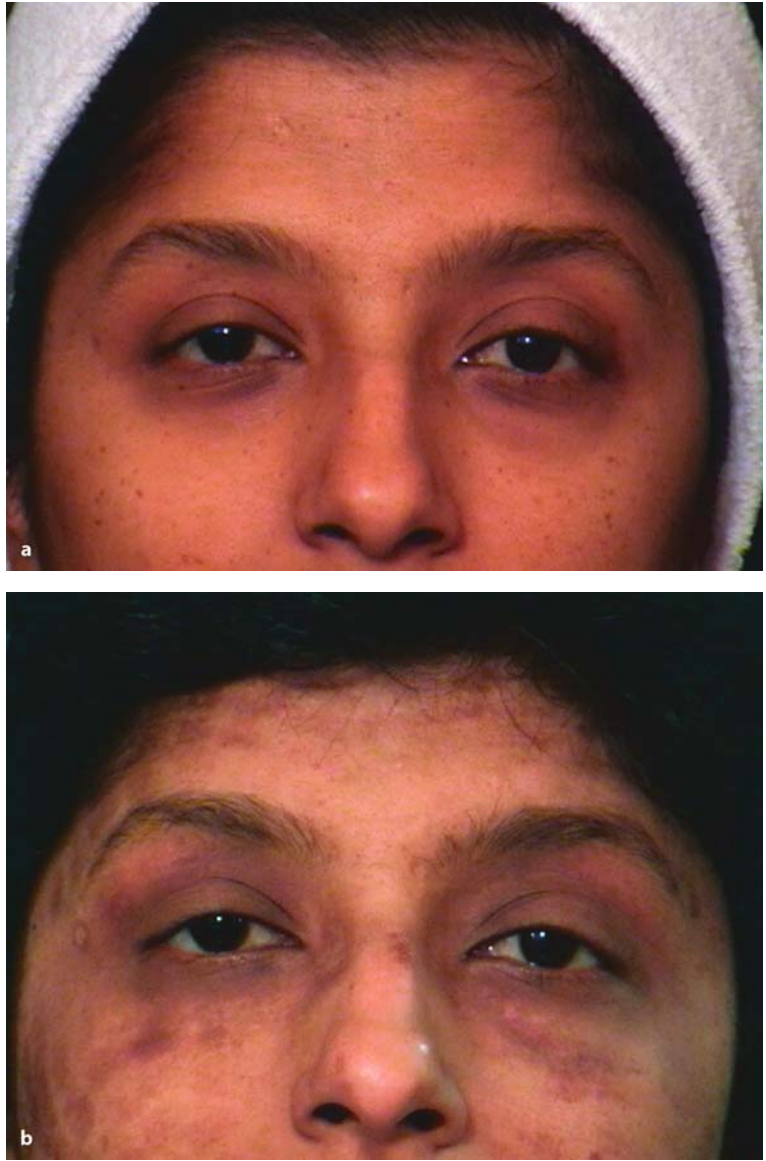least amount of thermal necrosis with the greatest subsequent collagen formation (compared with the scanned systems), but equivalent clinical outcomes between all four lasers were observed [13].

Although techniques and applied settings vary with each patient, practitioner, and type of laser used, general principles should be followed to maximize outcome while minimizing postoperative complications. Care must be taken to avoid overlapping or stacking of laser scans or pulses in order to reduce the risk of tissue scar formation and subsequently scarring. Similarly, it is important to thoroughly remove partially desiccated tissue between each laser pass. If only a single pass is performed, partially desiccated tissue can remain intact to serve as a biologic wound dressing [15]. It is best to avoid resurfacing areas such as the neck and chest due to the scarcity of pilosebaceous units in these regions with resultant slow re-epithelialization and potential for scarring [16].

Careful patient selection is critical in optimizing outcomes from laser skin resurfacing. Non-movement-associated rhytids, especially in the periorbital and perioral areas (Fig. 7.1a–c), are very responsive to laser resurfacing whereas movement-associated rhytids, such as in the glabella and forehead areas, fail to show as dramatic a response to laser treatment. In addition to ameliorating facial rhytids, the CO<sub>2</sub> laser has been shown to provide tissue tightening even as much as to exert a lifting effect on tissue. Upper eyelid dermatochalasis has been shown to be significantly improved after periocular CO<sub>2</sub> laser skin resurfacing [17]. When used with traditional surgical lifting techniques, it enhances the overall cosmetic outcome [18]. The CO<sub>2</sub> laser has also been used effectively to treat atrophic and other scars [12, 19]. Sculpting of scars with the laser yields a more uniform skin texture and stimulates new collagen formation within the dermal defects. Patients can expect a mean improvement of 50–80% in moderate atrophic scars, with continued collagen remodeling and scar effacement for 12–18 months postoperatively [12, 19]. Patients with scars previously treated with dermabrasion or deep chemical peels may have additional fibrosis, which is more difficult to vaporize, thereby re-

**Fig. 7.1a–c.**

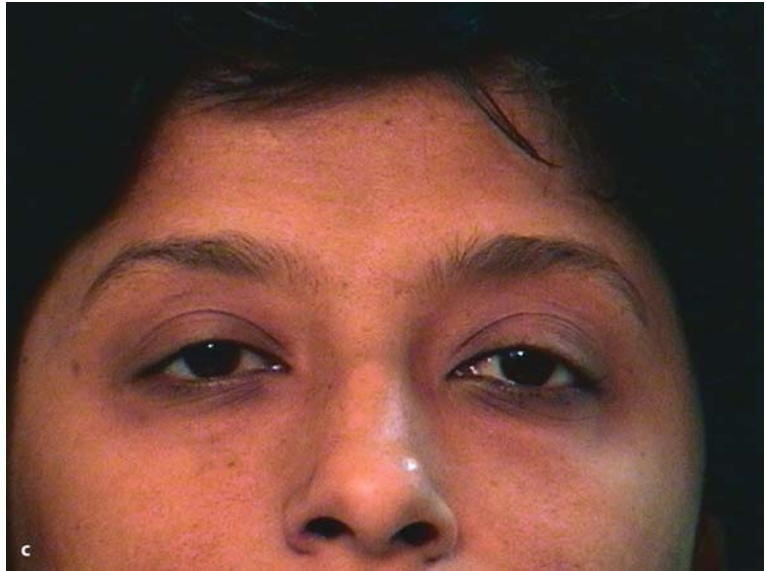Infraorbital rhytids and hyperpigmentation in a patient with skin phototype IV (a). Postinflammatory hyperpigmentation was observed 1 month following single-pass CO<sub>2</sub> laser skin resurfacing (b). Final results 1 month later with use of topical bleaching and peeling agents (c)



ducing their potential outcome. In addition, these patients also may have concealed hypopigmentation that could become more apparent after laser skin resurfacing [16, 19]. Although patients with paler skin tones are at lower risk for developing postoperative hyperpigmentation, those with darker skin tones can successfully undergo CO<sub>2</sub> laser resurfacing. Finally, and perhaps most importantly, patients

must have realistic expectations of postoperative outcomes and mentally prepare themselves for the convalescence and potential for prolonged erythema and skin sensitivity.

Fig. 7.1c.



### 7.2.2 Erbium:Yttrium-Aluminum-Garnet Laser

Because of the potential morbidity associated with the CO<sub>2</sub> laser, efforts in the mid-1990s were directed at developing alternative resurfacing modalities. The short-pulsed erbium:yttrium-aluminum-garnet (Er:YAG) laser was developed in an attempt to replicate the results of the CO<sub>2</sub> laser while minimizing the side-effect profile. The emitted wavelength of 2,900 nm is absorbed 12–18 times more efficiently by superficial cutaneous tissues, and approximately 2–5 μm of ablation occurs per pass with equally narrow zones of thermal necrosis [20]. Clinically, this translates into a shorter postoperative healing time with much less posttreatment erythema and risk of hyperpigmentation than CO<sub>2</sub> lasers. However, immediate collagen contraction is only about 1–4%, and long-term collagen remodeling ranges from 0–14% [5]. Multiple passes with this laser are necessary to ablate to a similar depth as one pass of the CO<sub>2</sub> laser, and because the Er:YAG effects are photomechanical instead of photothermal (like the CO<sub>2</sub>), intraoperative hemostasis is difficult to achieve [5, 21]. Therefore, the short-pulsed Er:YAG laser

is limited in its utility for moderate-to-severe acne scars and photo-induced rhytids (Fig. 7.2).

Several studies have documented the effectiveness of the Er:YAG laser in the treatment of mild-to-moderate rhytids, photodamage, and atrophic scars, with the use of multiple passes, high fluences, and/or multiple sessions yielding improved clinical outcomes [22, 23, 24, 25]. The Er:YAG laser has also proven a good option for treatment of patients with darker skin types due to its lower risk of pigmentary alteration [26] and has even been used to treat melasma [27].

To address the limitations of short-pulsed systems, novel modulated systems have been developed to allow deeper zones of thermal damage and a greater level of hemostasis. Hybrid Er:YAG/CO<sub>2</sub> laser systems (e.g., Derma-K, Lumenis, Santa Clara, CA, USA) are capable of delivering both CO<sub>2</sub> energy for coagulation and Er:YAG energy for fine tissue ablation. The dual mode Er:YAG (e.g., Contour, Sciton, Palo Alto, CA, USA) combines short pulses (for ablation) with longer pulses (for coagulation). The variable-pulsed Er:YAG (CO<sub>2</sub>, Cynosure, Chelmsford, MA, USA) system has a range of pulse durations from 500 μs to 10 ms, with the longer pulses effecting coagulation and thermal injury

**Fig. 7.2a-c.**

Atrophic acne scars in a patient with skin phototype IV before (a) erbium laser resurfacing. Postinflammatory hyperpigmentation was evident 3–4 weeks after the procedure (b), which resolved with topical use of lightening agents and mild glycolic acid peels (c)

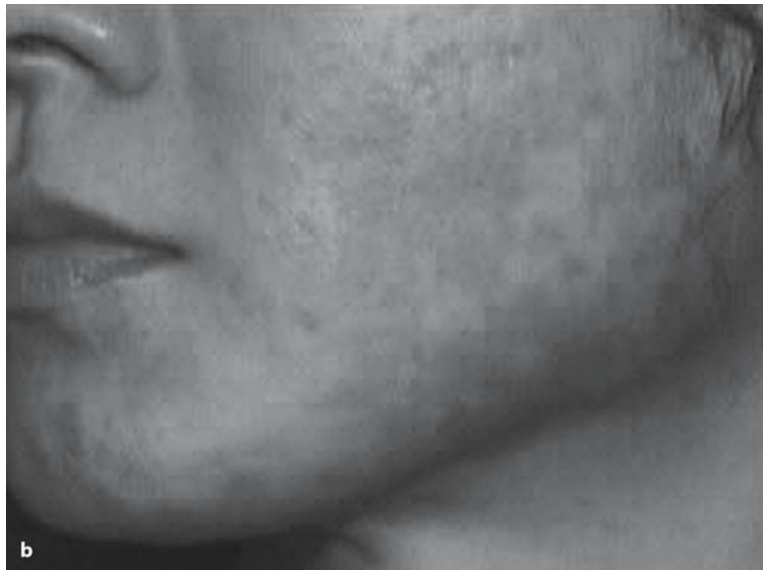
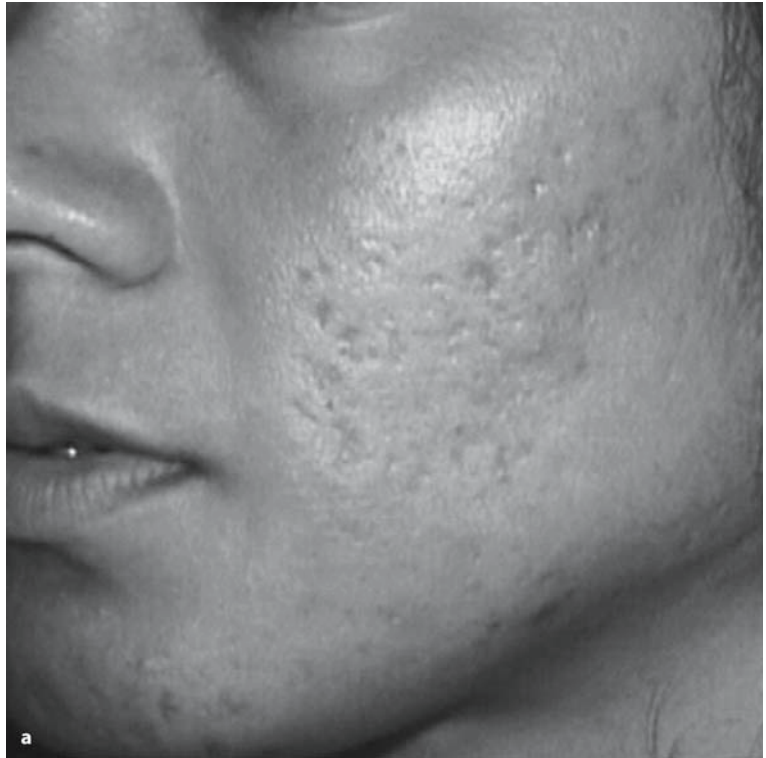
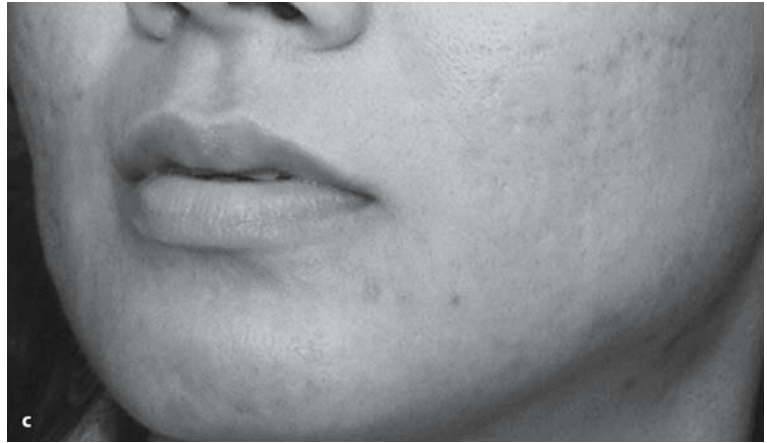

Fig. 7.2c.



similar to the CO<sub>2</sub> laser [28]. As a group, these lasers have been shown to produce deeper tissue vaporization, greater control of hemostasis, and collagen contraction. This translates into greater clinical improvement in mild-to-moderate acne scars and photodamage than their short-pulsed predecessors and thus represent a good compromise between CO<sub>2</sub> and earlier generation Er:YAG lasers [29, 30, 31, 32, 33].

### 7.2.3 Adverse Effects and Complications

Side effects and complications are varied and greatly influenced by postoperative care, patient selection, and operator skill. In general, the side-effect profile after Er:YAG laser resurfacing is similar but less severe and more transient when compared with those experienced after CO<sub>2</sub> laser resurfacing [34, 35, 36] (Table 7.2). Postoperative erythema, lasting an average of 4.5 months, is an expected occurrence in all

CO<sub>2</sub> laser-treated patients and is a normal consequence of the wound-healing process. Erythema after short-pulsed Er:YAG resurfacing is comparably transient of 2–4 weeks duration [5, 22]. Even after the dual-mode Er:YAG laser treatment, erythema persists beyond 4 weeks in only 6% of patients [34]. Time to re-epithelialization averages 8.5 days after multipass CO<sub>2</sub> laser resurfacing compared with 5.5 days after Er:YAG resurfacing [5]. Hyperpigmentation is a relatively common side effect—typically seen within 3–6 weeks after the procedure. After CO<sub>2</sub> resurfacing, the reported incidence is 5% in the periorbital area and 17–83% in other facial sites, with an even greater incidence in patients with darker skin tones [16, 32]. Hyperpigmentation also occurs after Er:YAG laser resurfacing and is more persistent if a variable-pulsed Er:YAG is used. However, when compared with multipass CO<sub>2</sub> resurfacing, hyperpigmentation after dual-mode Er:YAG resurfacing resolves 6 weeks earlier [32]. Single-pass CO<sub>2</sub> laser resurfacing and multipass Er:YAG resurfacing, however, are

**Table 7.2.** Side effects and complications of ablative laser skin resurfacing

Side effects	Mild complications	Moderate complications	Severe complications
Transient erythema	Prolonged erythema	Pigmentary change	Hypertrophic scar
Localized edema	Milia	Infection, (bacterial, fungal, viral)	Ectropion
Pruritus	Acne		
	Contact dermatitis		

comparable in terms of posttreatment erythema, re-epithelialization time, and hyperpigmentation [35]. Hyperpigmentation typically fades spontaneously but dissipates more rapidly with application of any of a variety of glycolic, azelaic, or retinoic acid creams, light glycolic acid peels, and/or hydroquinone compounds. Other mild and transient side effects that have been reported during wound healing include milia formation, acne exacerbation, and irritant or contact dermatitis [5, 16, 34, 36]. Hypopigmentation, on the other hand, is long standing, delayed in its onset (>6 months postprocedure), and is difficult to treat. Fortunately, it is seen far less frequently than is hyperpigmentation. Excimer laser and topical photochemotherapy have each shown some success in repigmenting affected areas [37].

A potentially more serious complication of laser skin resurfacing is infection—viral, bacterial, or fungal. Even with appropriate antiviral prophylaxis, herpes infection (usually reactivation of latent virus) occurs in 2–7% of patients postoperatively [15, 38, 39]. While antiviral prophylaxis is commonly prescribed, the use of postoperative antibacterials remains controversial, with one study showing no significant effect of antibacterial prophylaxis on infection rate [40]. What is widely agreed upon is that patients must be followed closely during the postoperative period and placed on appropriate antibiotics if bacterial infection is suspected. If infections are left undiagnosed or untreated, systemic infection or even scarring could result [41]. Scarring has also been attributed to the use of aggressive laser parameters and/or overlapping or stacking of laser pulses, which leads to excessive residual thermal necrosis of tissue [5, 12, 16]. Improvement of these laser-induced burn scars has been affected by 585-nm pulsed dye laser irradiation, presumably by its vascular specificity as well as through stimulation of cellular mediators critical to wound healing [42].

### 7.3 Nonablative Laser Skin Resurfacing

While ablative skin resurfacing with CO<sub>2</sub> and Er:YAG lasers has been proven highly effica-

cious in reversing the signs of facial photoaging and atrophic scars, the associated lifestyle hindrance and potential complications are often unacceptable to patients. In recent years, focus has shifted towards nonablative technologies that deliver either laser, light-based, or radio-frequency energies to the skin. Inconsistent and often only modest clinical results are the accepted tradeoffs for a virtually nonexistent recovery period and a low side-effect profile. A myriad of systems with “subsurfacing” capabilities has been studied, including intense pulsed light (IPL) and pulsed dye, Nd:YAG, diode, and Er:Glass lasers [43, 44, 45]. Typically, a series of monthly treatments are advocated. Each treatment generates thermal injury in the dermis with subsequent inflammation, cytokine up-regulation, and fibroblast proliferation [46]. Over several months, deposition of papillary dermal collagen in a parallel array occurs [45, 46].

#### 7.3.1 Pulsed Dye Laser

Although used predominantly for the treatment of vascular lesions and hypertrophic scars [2, 47], clinical studies have demonstrated the ability of 585nm and 595nm pulsed dye laser (PDL) to reduce mild facial rhytides with few side effects [48–51]. The most common side effects include mild edema, purpura, and transient post-inflammatory hyperpigmentation. Although increased extracellular matrix proteins and types I and III collagen and procollagen have been detected following PDL treatment, the exact mechanism whereby wrinkle improvement is effected remains unknown. It has been hypothesized that the selective heating of dermal vessels leads to release of endothelial-derived growth factors and cytokines that up-regulate fibroblasts in treated skin, thereby resulting in neocollagenesis and rhytide reduction.

#### 7.3.2 Mid-infrared lasers

Laser systems operating in the mid-infrared portion of the electromagnetic spectrum, in-

cluding the 1320 nm Nd:YAG, 1450 nm diode, and 1540 Er:Glass lasers, possess optimal wavelengths for water-based non-ablative skin remodeling [52]. The majority of ultraviolet induced sun damage occurs at dermal depths of 100–400  $\mu\text{m}$  and, because the water absorption coefficient is low at wavelengths longer than 700 nm, infrared lasers (>1000 nm) are able to better deliver energy at these tissue depths [44].

To protect the epidermis, dynamic cooling is employed. The handpiece contains a thermal sensor to assist in maintaining the epidermal temperature below 50°C. At 40–45°C, the dermis is heated to a temperature reached of 60–65° [44, 53]. The latest generation of the 1320 nm Nd:YAG laser (CoolTouch II, ICN Pharmaceuticals, Costa Mesa, CA) delivers energies ranging 28–38 J/cm<sup>2</sup> with a pulse duration of 350  $\mu\text{s}$  through a 10 mm spot size handpiece. Treatments are usually performed every month for a series of at least three sessions. Multiple studies have shown efficacy in the treatment of rhytides and atrophic facial scars with only mild edema and erythema post-procedure [53–57].

The 1450 nm diode laser (*SmoothBeam*, Candela Corp., Wayland, MA), which shortly followed the development of the 1320 nm CoolTouch laser, also targets water in deep dermal tissue. At the 1450 nm wavelength, lower peak powers are generated so delivery at longer pulse durations is necessary to achieve optimal fluences. For epidermal protection, tissue cooling is applied at brief intervals before, during, and after laser exposure [58]. In recent clinical trials, the *SmoothBeam* laser was shown to be effective in the treatment of facial and neck rhytides, acne, and atrophic scars [58–62]. Periorcular rhytides, in particular, appear to be most amenable to 1450 nm diode laser irradiation, with marked clinical improvement observed after a series of four treatments [58, 59]. Fluences used for treatment ranged 12 to 14 J/cm<sup>2</sup> with a 6 mm spot. Maximal clinical improvement is delayed for 6 months after the series of treatments, presumably because of slow collagen remodeling and synthesis.

A study comparing the 1320 nm Nd:YAG to the 1450 nm diode laser for treatment of atrophic acne scars revealed that the 1450 nm

laser effected more significant change in the scar appearance and skin texture [57]. Both mid-infrared lasers, however, induced clinical improvement. With the additional positive effect of the 1450 nm diode laser on active acneiform lesions [62], this system may be preferable for those patients with concomitant acne and atrophic facial scars.

Like the two aforementioned infrared lasers, the 1540 nm erbium-doped phosphate glass (erbium glass) system targets deep dermal water but is least absorbed by melanin, offering a potential advantage to the other nonablative lasers when treating darker skin types. The 1540 nm erbium glass laser has been used successfully to treat facial rhytides at 10 J/cm through a 4 mm collimated beam (Aramis, Quantal Medical, France) [63,64].

### 7.3.3 Intense Pulsed Light Source

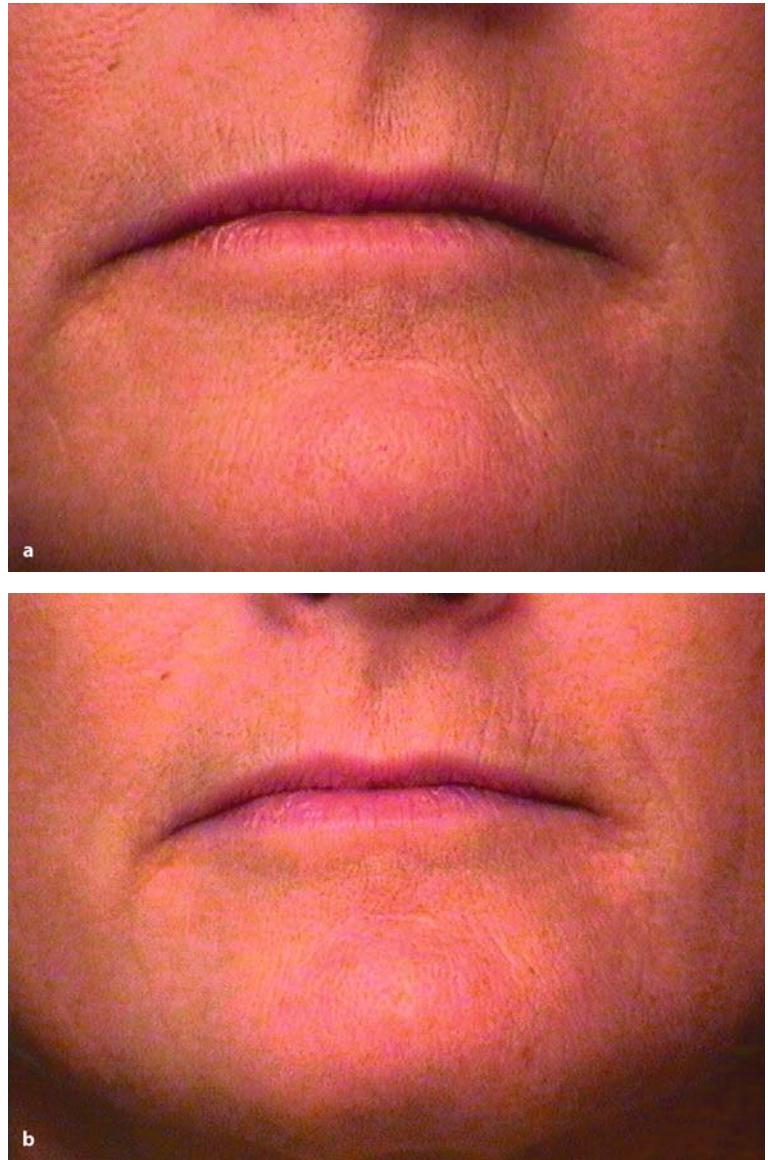Several investigators have shown successful rejuvenation of photodamaged skin after intense pulsed light (IPL) treatment [65–67]. The IPL source emits a broad, continuous spectrum of light in the range of 515 nm to 1200 nm. Depending on the clinical application, cut-off filters are used to eliminate shorter wavelengths, with shorter filters favoring heating of melanin and hemoglobin. Improvement in skin coarseness, irregular pigmentation, pore size, and telangiectasia is typical after a series of IPL treatments (fluences 30–50 J/cm<sup>2</sup>), however, neocollagenesis and dermal collagen remodeling with subsequent improvement in rhytides following treatment has been more modest. The mild effect on dermal collagen is thought to be induced by heat diffusion from the vasculature with subsequent release of inflammatory mediators stimulated by vessel heating [68].

### 7.4 Nonablative Radiofrequency Technology

The latest device to be initiated for non-ablative skin treatments involved radiofrequency (RF) technology. Unlike laser or light sources, which generate heat when selective targets, such as

**Fig. 7.3a,b.**

Perioral rhytides in a patient with skin phototype II before (a) and after (b) the third nonablative 1,320 nm Nd: YAG laser treatment



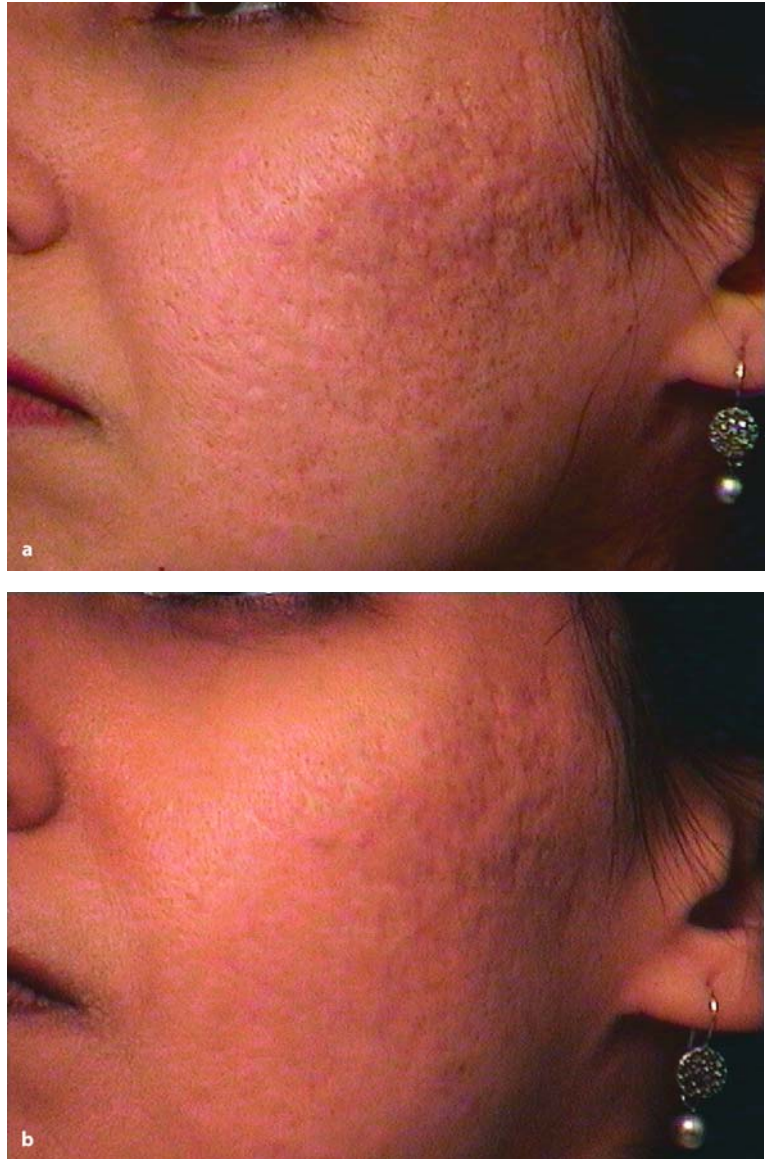microvasculature, absorb photons, the radiofrequency device delivers an electric current that nonselectively generates heat by the tissue's natural resistance to the flow of ions. As melanin absorption is not an issue, this RF device can be safely applied regardless of skin type. Radiofrequency technology has previously been used for aesthetic cutaneous surgery, albeit for a limited time and with equivocal results. High frequency, low voltage energy was

delivered through conducting media for epidermal ablation (cold ablation) [69,70]. Reconfiguration of this technology resulted in the ThermoCool TC™ System (Thermage, Inc., Hayward, CA), which has a unique treatment tip with a coupled electrode design that allows for uniform volumetric heating of the deep dermis. To prevent epidermal ablation, cryogen spray cooling is delivered prior to, during, and after the emission of radiofrequency energy.



**Fig. 7.4a,b.**

Atrophic acne scars in a patient with skin phototype III/IV before (a) and after (b) three consecutive monthly nonablative long-pulsed 1,450-nm diode laser treatments



Heating of the deep dermis and subcutaneous tissue occurs; with the depth determined by treatment tip geometry and the impedance levels in varying tissues (as opposed to wavelength with laser irradiation). Heat-induced collagen denaturation and contraction account for the immediate skin tightening seen after treatment [67]. As with all other non-ablative devices, further neocollagenesis takes place over the ensuing months, effecting further reduction of rhy-

tides and tissue tightening [71–74]. Periocular rhytides and brow rhytides have shown significant improvement after a single treatment, as have cheek and neck laxity [71–74]. Maximal clinical results are observed 3 to 6 months after treatment and additional treatments can be applied for additive effect [74].



## 7.5 Adverse Effects and Complications (Non-Ablative Lasers/ Radiofrequency)

Side effects of non-ablative lasers and radiofrequency treatments are generally mild and transient. Local erythema and edema are typically observed in treated skin; however, a small percentage of patients in these studies experience superficial burns, ecchymoses, dysesthesias, and vesiculation [59, 71–74]. Mild to moderate discomfort which intensifies at higher fluences is typical despite the use of topical anesthesia and tissue cooling techniques, thereby leading many practitioners to add oral sedation and/or anesthetic nerve blocks.

## 7.6 Conclusion

Skin remodeling using ablative and nonablative laser and other technologies is an area of continued growth and evolution. Further refinement of technology will serve to enhance clinical outcomes whilst minimizing side effects. Nonablative procedures for rhytides, scars, and tissue tightening offer a variable degree of improvement over a 3 to 6 month period. Results after treatment will disappoint patients who desire dramatic improvement in a short period of time. Additionally, although these technologies have a much lower side effect profile, they are not devoid of risks. For patients with frequent oral herpes outbreaks, antiviral prophylaxis should be considered prior to treatment with any laser or light source application due to possible viral activation. Patients with darker skin tones are at higher risk of hyperpigmentation after treatment with many lasers and light sources, therefore fluences and cryogen spray times should be adjusted accordingly and patients should be forewarned of this reversible complication.

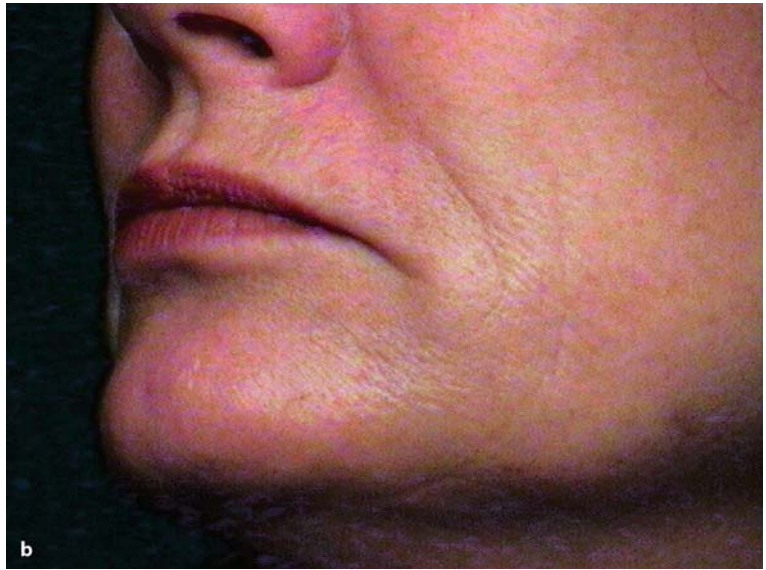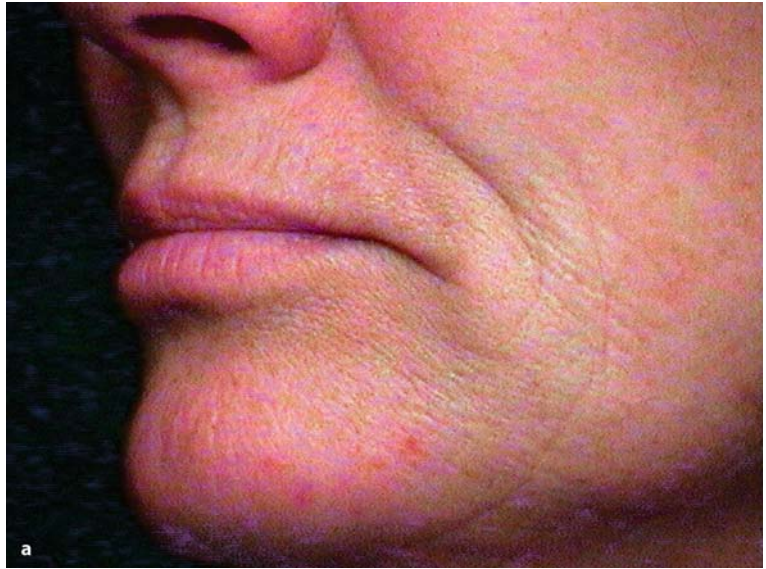## 7.7 Summary

Ablative laser skin resurfacing has revolutionized the approach to photodamaged facial skin.

Technology and techniques continue to evolve, further enhancing the ability to achieve substantial clinical improvement of rhytides and dyspigmentation with reduced postoperative morbidity. Utilizing proper technique and treatment parameters, excellent clinical results can be obtained with any one or combination of CO<sub>2</sub> and Er:YAG laser systems available. Therefore, the best choice of laser ultimately depends on the operator's expertise, clinical indication, and individual patient characteristics. Regardless of the type of ablative resurfacing laser used, the importance of careful postoperative follow-up cannot be overemphasized.

For those patients who desire a less aggressive approach to photorejuvenation, non-ablative dermal remodeling represents a viable alternative for patients willing to accept modest clinical improvement in exchange for ease of treatment and a favorable side-effect profile. Treatments are typically delivered at monthly time intervals with final clinical results taking several months after laser irradiation to be realized. Although clinical outcomes with these non-ablative systems are not yet comparable with those of ablative CO<sub>2</sub> or Er:YAG lasers, they do improve overall skin texture, tone and elasticity – subjective findings often difficult to represent in photographs. None of the non-ablative laser systems has yet emerged as being clearly superior – each produces similar degrees of improvement in dermal pathology after multiple sessions at standard treatment parameters. With continued research efforts focused on non-ablative laser skin remodeling, it is possible that further refinements and advances in this technology will more closely approximate the effects of ablative laser treatment without its associated complications and risks.

**Fig. 7.5a,b.**  
Cheek and neck skin laxity  
before (a) and after (b) a sin-  
gle radiofrequency skin treat-  
ment



## References

1. Maiman T (1960) Stimulated optical radiation in ruby. *Nature* 187:4
2. Tanzi EL, Lupton JR, Alster TS (2003) Review of lasers in dermatology: four decades of progress. *J Am Acad Dermatol* 4:1-31
3. Anderson RR, Parrish JA (1983) Selective photothermolysis: precise microsurgery by selective absorption of pulsed radiation. *Science* 220:524-527
4. Alster TS, Lupton JR (2001) Lasers in dermatology: an overview of types and indications. *Am J Clin Dermatol* 2:291-303
5. Alster TS (1999) Cutaneous resurfacing with CO<sub>2</sub> and Erbium:YAG lasers; preoperative, intraoperative, and postoperative considerations. *Plast Reconstr Surg* 103:619-632
6. Lanzafame RJ, Naim JO, Rogers DW, et al (1988) Comparisons of continuous-wave, chop-wave, and superpulsed laser wounds. *Lasers Surg Med* 8:119-124
7. Alster TS, Garg S (1996) Treatment of facial rhytides with a high energy pulsed carbon dioxide laser. *Plast Reconstr Surg* 98:791-794
8. Alster TS, Kauvar ANB, Geronemus RG (1996) Histology of high-energy pulsed CO<sub>2</sub> laser resurfacing. *Semin Cutan Med Surg* 15:189-193
9. Fitzpatrick RE, Smith SR, Sriprachya-anunt S (1999) Depth of vaporization and the effect of pulse stacking with a high-energy, pulsed carbon dioxide laser. *J Am Acad Dermatol* 40:615-622
10. Alster TS, Lupton JR (2001) An overview of cutaneous laser resurfacing. *Clin Plast Surg* 28:37-52
11. Ross E, Naseef G, Skrobal M, et al (1996) In vivo dermal collagen shrinkage and remodeling following CO<sub>2</sub> laser resurfacing. *Lasers Surg Med* 18:38
12. Walia S, Alster TS (1999) Prolonged clinical and histologic effects from CO<sub>2</sub> laser resurfacing of atrophic acne scars. *Dermatol Surg* 25:926-930
13. Alster TS, Nanni CA, Williams CM (1999) Comparison of four carbon dioxide resurfacing lasers: A clinical and histopathologic evaluation. *Dermatol Surg* 25:153-159
14. Alster TS (1998) Commentary on: Increased smooth muscle actin, factor XIIIa, and vimentin-positive cells in the papillary dermis of carbon dioxide laser-debrided porcine skin. *Dermatol Surg* 24:155
15. Alster TS, Hirsch RJ (2003) Single-pass CO<sub>2</sub> laser skin resurfacing of light and dark skin: extended experience with 52 patients. *J Cosmetic Laser Therapy* 5:39-42
16. Alster TS, Lupton JR (2002) Prevention and treatment of side effects and complications of cutaneous laser resurfacing. *Plast Reconstr Surg* 109:308-316
17. Alster TS, Bellew SG (2004) Improvement of dermatochalasis and periorbital rhytides with a high-energy pulsed CO<sub>2</sub> laser. *Dermatol Surg* 30:483-487
18. Alster TS, Doshi SN, Hopping SB (2004) Combination surgical lifting with ablative laser skin resurfacing: a retrospective analysis. *Dermatol Surg* 30:1191-1195
19. Alster TS, West TB (1996) Resurfacing of atrophic facial acne scars with a high-energy, pulsed carbon dioxide laser. *Dermatol Surg* 22:151-154
20. Kaufmann R, Hibst R (1996) Pulsed erbium:YAG laser ablation in cutaneous surgery. *Lasers Surg Med* 19:324-330
21. Walsh JT Jr, Deutsch TF (1989) Er:YAG laser ablation of tissue: Measurement of ablation rates. *Lasers Surg Med* 9:327-337
22. Alster TS (1999) Clinical and histologic evaluation of six erbium:YAG lasers for cutaneous resurfacing. *Lasers Surg Med* 24:87-92
23. Goldberg DJ, Cutler K (1999) The use of the erbium:YAG laser for the treatment of class III rhytides. *Dermatol Surg* 24:619-621
24. Weiss RA, Harrington AC, Pfau RC, et al (1999) Periorbital skin resurfacing using high-energy erbium:YAG laser: results in 50 patients. *Lasers Surg Med* 24:81-86
25. Kye YC (1997) Resurfacing of pitted facial scars with a pulsed Er:YAG laser. *Dermatol Surg* 23:880-883
26. Polnikorn N, Goldberg DJ, Suwanchinda A, et al (1998) Erbium:YAG laser resurfacing in Asians. *Dermatol Surg* 24:1303-1307
27. Manaloto RMP, Alster TS (1999) Erbium:YAG laser resurfacing for refractory melasma. *Dermatol Surg* 25:121-123
28. Sapijaszki MJA, Zachary CB (2002) Er:YAG laser skin resurfacing. *Dermatol Clin* 20:87-96
29. Tanzi EL, Alster TS (2002) Treatment of atrophic facial acne scars with a dual mode Er:YAG laser. *Dermatol Surg* 15:33-36
30. Trelles MA, Mordon S, Benitez V, Levy JL (2001) Er:YAG laser resurfacing using combined ablation and coagulation modes. *Dermatol Surg* 27:727-734
31. Rostan EF, Fitzpatrick RE, Goldman MP (2001) Laser resurfacing with a long pulse Erbium:YAG laser compared to the 950 ms pulsed CO<sub>2</sub> laser. *Lasers Surg Med* 29:136-141
32. Alster TS, Lupton JR (2001) Erbium:YAG cutaneous laser resurfacing. *Dermatol Clin* 19:453-466
33. Teikemeier G, Goldberg DJ (1997) Skin resurfacing with the erbium:YAG laser. *Dermatol Surg* 23:685-687
34. Tanzi EL, Alster TS (2003) Single pass carbon dioxide versus multiple-pass Er:YAG laser skin resurfacing: a comparison of postoperative wound healing and side effect rates. *Dermatol Surg* 29:80-84
35. Tanzi EL, Alster TS (2003) Side effects and complications of variable-pulsed Erbium:Yttrium-Aluminum-Garnet laser skin resurfacing: extended experience with 50 patients. *Plast Reconstr Surg* 111(4):1524-1529
36. Nanni CA, Alster TS (1998) Complications of carbon dioxide laser resurfacing: An evaluation of 500 patients. *Dermatol Surg* 24:315-320

37. Friedman PM, Geronemus RG (2001) Use of the 308-nm excimer laser for postresurfacing leukoderma. *Arch Dermatol* 137: 824–825
38. Alster TS, Nanni CA (1999) Famciclovir prophylaxis of herpes simplex virus reactivations after laser skin resurfacing. *Dermatol Surg* 25 (3): 242–246
39. Bernstein LJ, Kauvar AN, Grossman MC, Geronemus RG (1997) The short and long-term side effects of carbon dioxide laser resurfacing. *Dermatol Surg* 23: 519–525
40. Walia S, Alster TS (1999) Cutaneous CO<sub>2</sub> laser resurfacing infection rate with and without prophylactic antibiotics. *Dermatol Surg* 25: 857–886
41. Sriprachya-Anunt S, Fitzpatrick RE, Goldman MP, et al (1997) Infections complicating pulsed carbon dioxide laser resurfacing for photoaged facial skin. *Dermatol Surg* 23: 527–536
42. Alster TS, Nanni CA (1998) Pulsed dye laser treatment of hypertrophic burn scars. *Plast Reconstr Surg* 102: 2190–2195
43. Alster TS, Lupton JR (2002) Are all infrared lasers equally effective in skin rejuvenation. *Semin Cutan Med Surg* 21: 274–279
44. Hardaway CA, Ross EV (2002) Non-ablative laser skin remodeling. *Dermatol Clin* 20: 97–111
45. Alam M, Hsu T, Dover JS, Wrone DA (2003) Nonablative laser and light treatments: Histology and tissue effects – a review. *Lasers Surg Med* 33: 30–39
46. Ross EV, Sajben FP, Hsia J, Barnette D, Miller CH, McKinlay JR (2000) Nonablative skin remodeling: Selective dermal heating with a mid-infrared laser and contact cooling combination. *Lasers Surg Med* 26: 186–195
47. Lupton JR, Alster TS (2002) Laser scar revision. *Dermatol Clin* 20: 55–65
48. Zelickson BD, Kilmer SL, Bernstein E, Chotzen VA, Dock J, Mehregan D, et al (1999) Pulsed dye therapy for sun damaged skin. *Lasers Surg Med* 25: 229–236
49. Bjerring P, Clement M, Heikerndorff L, Egevisst H, Kiernan M (2000) Selective nonablative wrinkle reduction by laser. *J Cutan Laser Ther* 2: 9–15
50. Rostan EF, Bowes LE, Iyer S, Fitzpatrick RF (2001) A double-blind side-by-side comparison study of low fluence long pulse dye laser to coolant treatment for wrinkling of the cheeks. *J Cosmetic Laser Ther* 3: 129–136
51. Tanghetti EA, Sherr EA, Alvarado SL (2003) Multi-pass treatment of photodamage using the pulse dye laser. *Dermatol Surg* 29: 686–691
52. Alster TS, Tanzi EL (2004) Benign manifestations of photodamage: laser and light source treatment. In: Goldberg DB (ed) *Photodamaged Skin*. Marcel Dekker Inc, New York, pp 115–143
53. Kelly KM, Nelson JS, Lask GP, Geronemus RG, Bernstein LJ (1999) Cryogen spray cooling in combination with nonablative laser treatment of facial rhytides. *Arch Dermatol* 135: 691–694
54. Goldberg DJ (1999) Nonablative subsurface remodeling: Clinical and histologic evaluation of a 1320 nm Nd:YAG laser. *J Cutan Laser Ther* 1: 153–157
55. Trelles MA, Allones I, Luna R (2001) Facial rejuvenation with a nonablative 1320 nm Nd:YAG laser: A preliminary clinical and histologic evaluation. *Dermatol Surg* 27: 111–116
56. Fatemi A, Weiss MA, Weiss RS (2002) Short-term histologic effects of nonablative resurfacing: Results with a dynamically cooled millisecond-domain 1320 nm Nd:YAG laser. *Dermatol Surg* 28: 172–176
57. Tanzi EL, Alster TS (2004) Comparison of a 1450 nm diode laser and a 1320 nm Nd:YAG laser in the treatment of atrophic facial scars: a prospective clinical and histologic study. *Dermatol Surg* 30: 152–157
58. Goldberg DJ, Rogachefsky AS, Silapunt S (2001) Non-ablative laser treatment of facial rhytides. A comparison of 1450-nm diode laser treatment with dynamic cooling as opposed to treatment with dynamic cooling alone. *Lasers Surg Med* 30: 79–81
59. Tanzi EL, Alster TS (2003) Treatment of facial rhytides with a 1450-nm diode laser: A controlled clinical and histologic study. *Dermatol Surg* 29: 124–128
60. Tanzi EL, Alster TS (2002) Treatment of transverse neck lines with a 1,450 diode laser. *Lasers Surg Med* 14 (Suppl): 33
61. Hardaway CA, Ross EV, Barnett DJ, Paithankar DY (2002) Non-ablative cutaneous remodeling with a 1.45  $\mu$ m mid-infrared diode laser: phase I. *J Cosmetic Laser Ther* 4: 3–8
62. Paithankar DY, Ross EV, Saleh BA, Blair MA, Graham BS (2002) Acne treatment with a 1450 nm wavelength laser and cryogen spray cooling. *Lasers Surg Med* 31: 106–114
63. Lupton JR, Williams CM, Alster TS (2002) Nonablative laser skin resurfacing using a 1540nm erbium: glass laser: A clinical and histological analysis. *Dermatol Surg* 28: 833–835
64. Fournier N, Dahan S, Barneon G, et al (2002) Non-ablative remodeling: a 14-month clinical ultrasound imaging and profilometric evaluation of a 1540 nm Er: glass laser. *Dermatol Surg* 28: 926–931
65. Goldberg DJ, Cutler KB (2000) Nonablative treatment of rhytids with intense pulse light. *Lasers Surg Med* 26: 196–1931
66. Bitter PH (2000) Non-invasive rejuvenation of photodamaged skin using serial, full face intense pulsed light treatments. *Dermatol Surg* 26: 835–843
67. Weiss RA, Weiss MA, Beasley KL (2002) Rejuvenation of photoaged skin: 5 years experience with intense pulsed light of the face, neck, and chest. *Dermatol Surg* 28: 1115–1119
68. Zelickson B, Kist D (2000) Effect of pulse dye laser and intense pulsed light source in dermal extracellular matrix remodeling. *Laser Surg Med* 12: 68

69. Sarradet MD, Hussain M, Goldberg DJ (2003) Electrosurgical resurfacing: a clinical, histologic, and electron microscopic evaluation. *Lasers Surg Med* 32:111-114
70. Alster TS (2001) Electrosurgical ablation: a new mode of cutaneous resurfacing. *Plast Reconstr Surg* 107:1890-1894
71. Ruiz-Esparza J, Gomez JB (2003) The medical face lift: a noninvasive, nonsurgical approach to tissue tightening in facial skin using nonablative radiofrequency. *Dermatol Surg* 29:325-332
72. Fitzpatrick R, Geronemus R, Goldberg D, et al (2003) First multicenter study of noninvasive radiofrequency for periorbital tissue tightening. *Laser Surg Med* 33:232-242
73. Hsu TS, Kaminer MS (2003) The use of nonablative radiofrequency technology to tighten the lower face and neck. *Semin Cutan Med Surg* 22:115-123
74. Alster, TS, Tanzi EL (2004) Improvement of neck and cheek laxity with a non-ablative radiofrequency device: a lifting experience. *Dermatol Surg* 30:503-507



## Core Messages

- Advances in the development of treatment of leg veins have resulted in the practice of sclerotherapy flourishing in the United States and abroad.
- The most common vascular disorders of the lower extremities are varicose veins, reticular veins, and telangiectatic veins.
- Hereditary factors, increased deep vein pressure, and primary or secondary valvular incompetence are the common factor involved in the development of small and large varicosities.
- Sclerosants used in sclerotherapy are available in liquid and foam preparations.

## Contents

8.1	<b>Introduction</b> . . . . .	128
8.2	<b>Venous Anatomy of the Lower Extremity</b> . . . . .	128
8.2.1	The Deep Venous System . . . . .	129
8.2.2	The Superficial Venous System . . . . .	129
8.2.3	Other Superficial Veins of the Leg . . . . .	130
8.2.4	Perforating Veins . . . . .	131
8.2.5	The Venous Valvular System . . . . .	131
8.3	<b>Indications for Sclerotherapy</b> . . . . .	132
8.4	<b>Clinical Evaluation of the Venous System of the Lower Extremity</b> . . . . .	134
8.5	<b>Diagnostic Examination of the Venous System of the Lower Extremity</b> . . . . .	135
8.6	<b>Treatment of Telangiectasias</b> . . . . .	140
8.6.1	Venous Segment Preparation . . . . .	140
8.6.2	Sclerotherapy Technique for Telangiectasias . . . . .	143
8.7	<b>Sclerotherapy Techniques for the Treatment of Varicose Veins</b> . . . . .	148
8.8	<b>Compression Foam Sclerotherapy</b> . . . . .	150
8.8.1	The History of Sclerosing Foams . . . . .	150
8.8.2	Compression Foam Sclerotherapy . . . . .	153
8.8.3	Methods for the Preparation of Sclerosing Foam . . . . .	154
8.8.4	Indications for Foam Sclerotherapy . . . . .	157
8.8.5	Body Position . . . . .	157
8.8.6	Recommended Volume of Sclerosing Foam . . . . .	157
8.8.7	Injection Variables . . . . .	158
8.9	<b>Complications and Risks</b> . . . . .	158
8.9.1	Postsclerotherapy Hyperpigmentation . . . . .	159
8.9.2	Edema . . . . .	160
8.9.3	Telangiectatic Matting . . . . .	160
8.9.4	Localized Urticaria . . . . .	161
8.9.5	Tape Compression Blister Formation . . . . .	161
8.9.6	Tape-Induced Folliculitis . . . . .	161
8.9.7	Vessel Recurrence . . . . .	161
8.9.8	Vasovagal Reactions . . . . .	161
8.9.9	Cutaneous Necrosis . . . . .	162
8.9.10	Allergic Reactions . . . . .	162
8.9.11	Superficial Thrombophlebitis . . . . .	162
8.9.12	Arterial Injection . . . . .	163
8.9.13	Pulmonary Embolism/Deep Venous Thrombosis . . . . .	163
8.9.14	Nerve Damage . . . . .	163
8.10	<b>Conclusion</b> . . . . .	163
	<b>References</b> . . . . .	165

## 8.1 Introduction

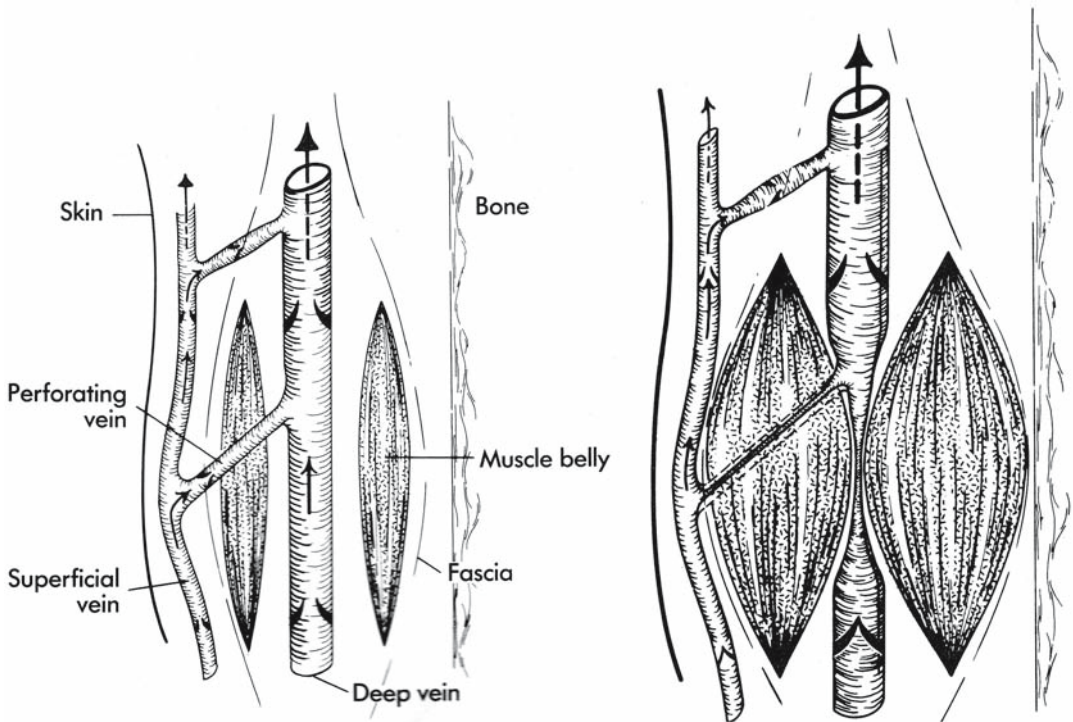
Varicose veins and the subset of small varicosities referred to as telangiectatic and reticular veins are the most common vascular disorders of the lower extremities. Up to 60% of American adults are affected with varicose veins, and the incidence increases with age [1]. Many of these patients are affected not only by their appearance, but also by the quality of life that can accompany varicose veins. Varicosities can be associated with varying degrees of discomfort and pain, lipodermatosclerosis, venous ulcerations, thrombophlebitis, and deep vein thrombosis.

Sclerotherapy involves the introduction of a sterile foreign chemical by injection into an intracutaneous, subcutaneous, trans fascial or subfascial abnormal venous lumen, resulting in transmural denaturation of the vessel wall and subsequent panvascular fibrosis and destruction of the vessel. Controversy concerning the precise mechanism of action of sclerotherapy persists. The term sclerotherapy was first introduced in 1936. However, intravascular sclerotherapy of varicose veins was initially performed in 1840, shortly after the development of the hypodermic needle, utilizing a solution of absolute alcohol [2]. Increasing sophistication in the discipline of sclerotherapy over the years has led to continued refinement of sclerotherapy techniques. Advances in the development of sclerosing solutions, prolonged post-sclerotherapy compression, accurate methods of detecting valvular incompetence and venous hypertension, and the refinement of foam sclerotherapy techniques for the closure of incompetent saphenous trunks and perforating veins have resulted in the practice of sclerotherapy flourishing in the United States and abroad.

## 8.2 Venous Anatomy of the Lower Extremity

An understanding of the venous system of the lower leg is important for proper treatment of varicose and telangiectatic veins. The venous systems of the leg are divided into two systems:

deep and superficial. These two systems run parallel to the long axis of the leg. Ninety percent of the deoxygenated blood returning from the lower extremities is carried by the veins of the deep venous system [3]. The main function of the vessels of the superficial venous system is drainage of the venules of the skin into the deep venous system. The deep and superficial venous systems directly communicate through a series of perforating veins and also at venous junctions, where the blood of the superficial venous system drains into the deep venous system [4]. The veins of the deep venous system lie within the muscular system of the leg deep in its fascial compartment. The superficial veins course through the skin and subcutaneous tissue peripheral to the deep fascia. The perforating veins run an oblique course through the deep fascia, between muscle bundles, connecting the two systems. The mechanism of transporting venous blood from the legs is accomplished by contraction of the calf muscles (the calf-muscle pump or the peripheral heart) [2]. Therefore, the deep venous system is an important component in maintaining function of the cardiovascular system. During muscle relaxation, deep venous blood reflux in the leg is prevented by means of a passive one-way valve system (Fig. 8.1). Blood flow from the superficial to the deep venous system occurs via the perforating veins and the venous junctions during muscle relaxation when the hydrostatic pressure in the deep venous system falls below the pressure in the superficial veins (Fig. 8.1). The hydrostatic pressure in the saphenous veins of the lower extremities can be as high as 90–120 mmHg or more at the ankle when standing erect and motionless [2]. In contrast, the hydrostatic pressure at the distal aspect of the upper extremity at rest and upright is only 35 mmHg [5]. Pressure generated in the deep venous system can reach 200–300 mmHg during calf-muscle contraction, such as with walking (Fig. 8.1). Clearly, any source of prolonged increased hydrostatic pressure, such as prolonged standing or sitting in one place, will adversely affect the effectiveness of the calf-muscle pump.



**Fig. 8.1a,b.** Schematic diagram of the calf-muscle pump. **a** Relaxed state: all valves are open allowing blood to flow in a proximal direction. Blood flows proximal in both the superficial vein and through the perforating vein into the deep veins. **b** With muscle contraction, the

perforating veins are squeezed closed. Valves distal to the compression are closed to prevent distal blood flow. (Reprinted with permission from Goldman MP (1991) *Sclerotherapy: Treatment of varicose and telangiectatic leg veins*. Mosby, St. Louis.)

### 8.2.1 The Deep Venous System

The principle veins of the deep venous system of the lower extremity consist of the anterior tibial, the posterior tibial and the peroneal veins, named for their corresponding paired arteries. These veins originate in the foot as plantar digital veins. At the level of the knee, these three veins join into a single popliteal vein (Fig. 8.2). The popliteal vein becomes the femoral vein (sometimes called the superficial femoral vein) once within the thigh (Fig. 8.2). The deep femoral vein (also referred to as the profunda femoris vein) joins the superficial femoral vein of the deep venous system proximally to form the common femoral vein.

### 8.2.2 The Superficial Venous System

The greater (or long) saphenous vein (LSV) and the lesser (or short) saphenous vein (SSV) comprise the larger veins of the superficial venous system. These vessels are superficial to the deep fascia and muscles of the leg. The majority of cutaneous and subcutaneous veins empty into one of these two veins or their tributaries [3]. Superficial veins can also drain directly into perforating veins or anastomose with branches of the abdominal, pudendal, perineal, and gluteal venous systems, thereby bypassing the long and short saphenous systems [3]. The greater saphenous vein begins on the dorsum of the foot and ascends anteriorly and medially to join the common femoral vein of the deep venous system at the saphenofemoral junction (Fig. 8.2). The lesser saphenous vein is the most

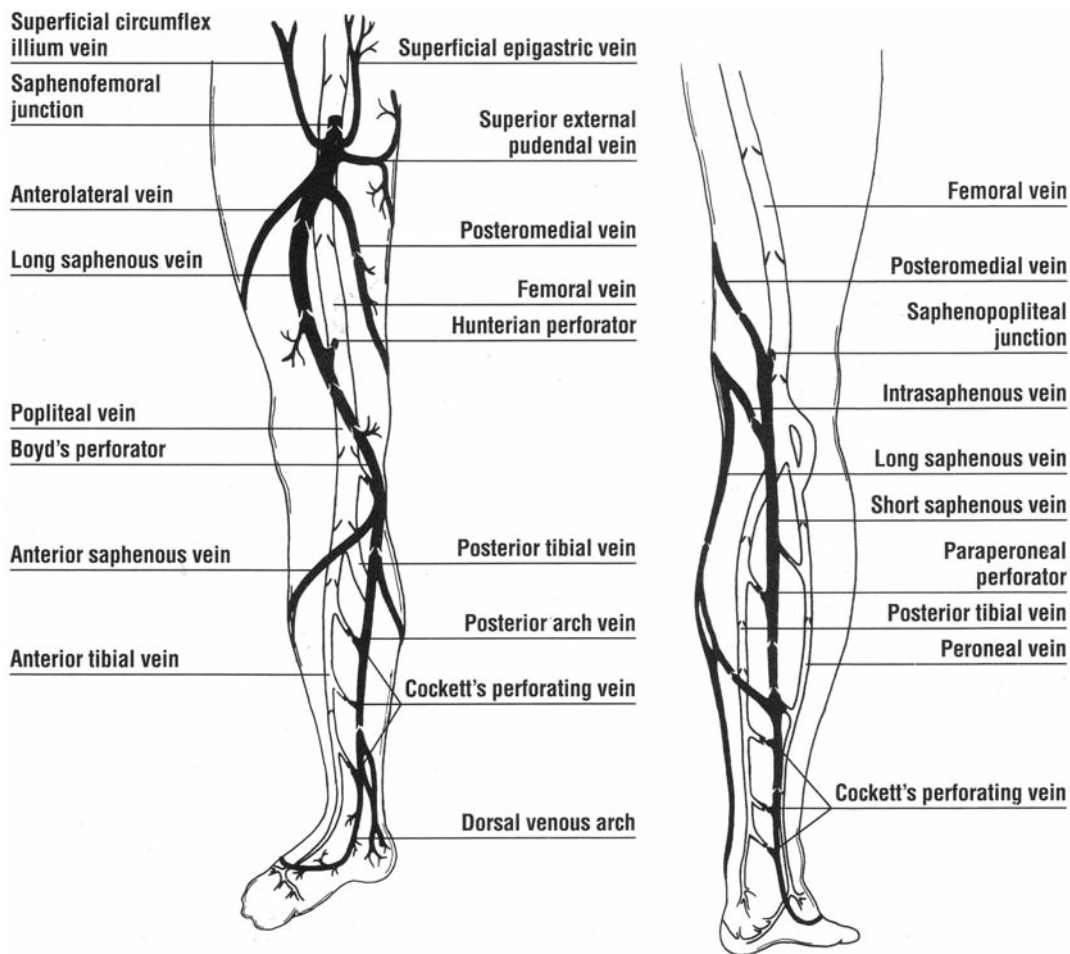


Fig. 8.2. Simplified diagram of major veins in the legs. The superficial veins are shown in solid black. (Reprinted with permission from Goldman MP (1991) *Sclero-*

*therapy: Treatment of varicose and telangiectatic leg veins.* Mosby, St. Louis.)

prominent superficial vein below the knee and ascends from the lateral aspect of the foot and posteriorly up the calf. It terminates in the popliteal vein of the deep venous system at the saphenopopliteal junction (Fig. 8.2). Superficial veins provide a pathway for venous return from the cutaneous and subcutaneous systems. The superficial venous arrangement exhibits a marked diversity in anatomy, however.

### 8.2.3 Other Superficial Veins of the Leg

The accessory saphenous vein is a fairly constant vein that courses from the lateral knee to the saphenofemoral junction. Other prominent and consistent superficial veins include the anterior crural vein, which runs from the lower lateral calf to the medial knee, and the infragenicular vein, which drains the skin around the knee. The reticular or connecting branch veins may represent a normal network of blue-green-colored subcutaneous veins or when associated

with venous hypertension may be tortuous and varicose.<sup>2</sup>

### 8.2.4 Perforating Veins

Perforating/communicating veins connect the veins of the superficial venous system to the deep venous system by directing the one-way flow of blood into the deep venous system (Fig. 8.2). The only exception to this inward flow of blood is in the foot, where perforating veins with valves allow blood flow from the deep to the superficial veins [2]. Additionally, the majority of pedal-perforating veins usually do not contain valves. Therefore, a muscle pump in the foot must also provide a mechanism for venous return, which is activated by weight bearing. Perforating veins are present from the ankle to the groin. The number of perforating veins per leg is variable, with as few as 64 to as many as 155 per leg [2]. Most perforating veins contain one to three valves. The valvular system is unidirectional, with blood flowing from superficial veins to deep veins. This prevents the high venous pressure from muscle contractions of the deep venous system from being transmitted to the superficial veins (Fig. 8.1). The typical perforating vein is a 1- to 2-mm thin-walled vessel. When perforating veins become incompetent, the high pressure from the deep veins of the calf-muscle pump is transmitted to the superficial veins by way of the perforating veins. When incompetent, perforating veins become thick-walled and may reach a diameter of 5 mm or more. In the thigh, the Hunterian (or Dodd's) perforating veins are relatively constant and are associated with the medial intramuscular septum of the thigh (Fig. 8.2). These perforating veins connect the long saphenous vein to the femoral vein in the middle medial thigh and the lower third of the thigh. These perforating veins do not pierce muscle and consequently lose the benefit of protection from becoming incompetent by lack of support from the surrounding thigh muscles within the deep fascial compartment [3]. Hence, incompetence of the Hunterian/Dodd's perforating veins is a common cause for medial thigh varicosities in patients with a competent

saphenofemoral junction. Many smaller perforating veins may also be present in the middle third of the lateral aspect of the thigh and the midline posterior thigh, connecting the long saphenous vein and its tributaries to the profunda femoris vein (deep femoral vein).

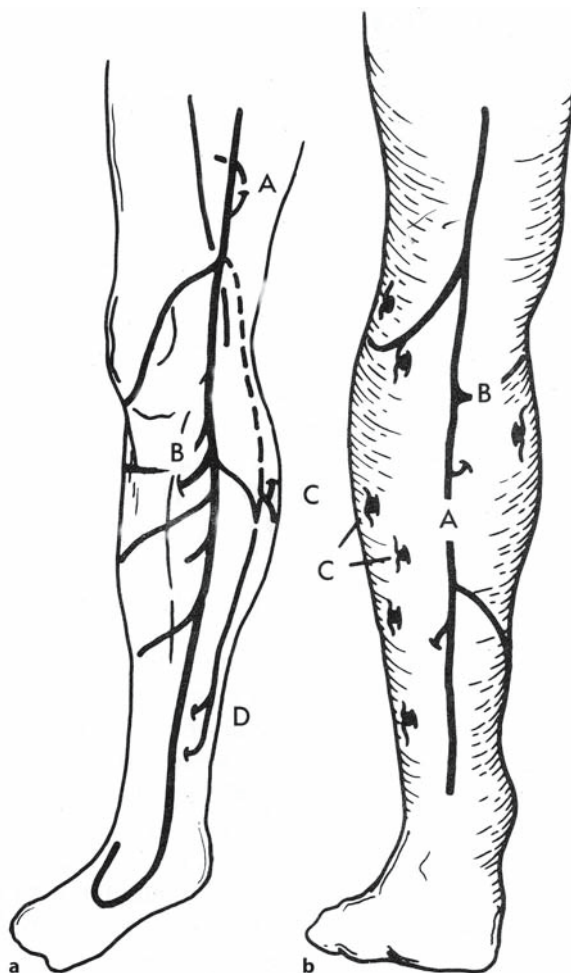
The posterior tibial perforating vein occurs in almost all limbs approximately 5–10 cm distal to the knee on the medial calf (Fig. 8.3). It connects the long saphenous vein to the posterior tibial vein. Cockett's perforating veins are comprised of a group of perforating veins located along the medial ankle coursing superiorly to the medial calf (Figs. 8.2 and 8.3). They do not drain directly into the long saphenous vein but connect the posterior arch vein of the calf to the posterior tibial vein (Figs. 8.2 and 8.3). Multiple perforating veins are also found with regularity along the medial calf. Some of these perforating veins drain into the posterior tibial vein, the gastrocnemius vein, and the soleal vein. Boyd's perforating vein is another clinically important perforating vein, located approximately 10 cm below the medial joint of the knee. Perforating veins, therefore, play a fundamental roll in the development of varicose veins.

### 8.2.5 The Venous Valvular System

The number of venous valves of the leg veins has been found to be decreased in patients with varicose veins when compared with patients without varicose veins [2]. Age or gender does not correlate with a decrease in valvular number. Therefore, other factors must contribute to the decrease in the number of venous valves. Additional potential mechanisms of valvular dysfunction contributing to varicose veins include fibrosis of these valves caused by turbulent high-pressure blood flow, a hereditary defect in either vein wall and/or valvular structure, and an increase in deep venous pressure (Table 8.1). Since competent venous valves are able to withstand pressures of up to 3 atmospheres, the normal vein diameter must first dilate in order to cause valvular incompetency [2]. Chronic venous dilation from chronic venous hypertension may likely produce stress on



**Fig. 8.3.** **a** Typical course of the long saphenous vein (LSV), including its common tributaries and perforating veins. **A** Hunterian perforating vein, **B** posterior tibial perforating vein, **C** calf perforator in the location of the intrasaphenous vein, **D** medial ankle, or Cockett perforators. **b** Typical course of the SSV with termination above the popliteal fossae and associated perforator veins. **A** SSV, **B** intersaphenous vein with calf perforator, **C** paraperoneal perforating veins. (Reprinted with permission from Goldman MP (1991) *Sclerotherapy: Treatment of varicose and telangiectatic leg veins*. Mosby, St. Louis.)



the valvular system, leading to dysfunctional fibrosis of the valves(s). These dysfunctional valves lead to the development of valvular insufficiency, which in turn causes a reversal of blood flow from the deep venous system to the superficial veins through incompetent perforating/communicating veins. This reversal of flow by incompetent valves of perforating veins may be beneficial, however, during sclerotherapy. When a superficial varicosity is injected, the reversal of blood flow forces the direction of the sclerosant to flow distally to the smaller branching veins away from the deep veins thereby preventing thromboembolic disease of the deep venous system. In summary, pathologic development of incompetent valves and vari-

cose veins can be divided into the following four categories: increased deep venous pressure, primary valvular incompetence, secondary valvular incompetence, and heredity factors.

### 8.3 Indications for Sclerotherapy

The objectives of sclerotherapy include the treatment of varicosities, telangiectasias, and/or reticular veins of the lower extremity (Tables 8.2 and 8.3) and prevention of possible complications; reduction or elimination of existing symptoms; improvement in altered hemodynamics; and achievement of a final result

**Table 8.1.** Factors involved in the development of varicose veins

Increased deep venous pressure
Proximal causes
Pelvic obstruction (indirect venous obstruction)
Increased intraabdominal pressure (straining at defecation or micturition, wearing constrictive clothing, prolonged standing, chair sitting, leg crossing, squatting, obesity, or running)
Saphenofemoral incompetence
Venous obstruction
Distal causes
Communicating or perforating vein valvular incompetence
Venous obstruction
Arteriovenous anastomoses
Primary valvular incompetence
Venous obstruction (thrombosis)
Thrombophlebitis with destruction of venous valves
Congenital absence of the venous valves (agenesis)
Decreased number of venous valves
Secondary valvular incompetence
Deep venous obstruction
Increased venous distensibility
Hormonal (pregnancy; estrogens, progesterone, and their relative concentrations)
Heredity
Vein wall weakness
Inherited deficiency of vein wall collagen
Primary valvular dysfunction / agenesis
ABO blood group

Source: This has been modified from Goldman MP (1991) *Sclerotherapy: Treatment of varicose and telangiectatic leg veins*. Mosby, St. Louis, p 56, with permission from the author

**Table 8.2.** Classification of abnormal veins

Vein type	Diameter	Color
Telangiectasia (spider veins)	0.1–1.0 mm	Red to cyanotic
Telangiectatic matting	<0.2 mm	Red
Communicating telangiectasia <sup>a</sup>	0.1–1.0 mm	Red to cyanotic
Telangiectatic and varicose vein mixture <sup>b</sup>	1.0–6.0 mm	Cyanotic to blue
Nonsaphenous varicose veins (reticular veins)	2–8 mm	Blue to blue-green
Saphenous varicose veins	>8 mm	Blue to blue-green

Source: This has been modified from Goldman MP (1991) *Sclerotherapy: Treatment of varicose and telangiectatic leg veins*. Mosby, St. Louis, p 56, with permission from the author

<sup>a</sup> Veins that communicate directly with varicose veins of the saphenous system

<sup>b</sup> Veins that do not communicate directly with the saphenous system

**Table 8.3.** Types of veins responsive to sclerotherapy

Truncal veins
Incompetent perforating veins
Communicating/side branch varicosities
Reticular veins
Venulectases
Telangiectasias (spider veins)
Postsclerotherapy and postsurgical recurrent varicose veins

that satisfies aesthetic and functional criteria [6]. Sclerotherapy is considered the first line of treatment for small, intracutaneous varicose veins (reticular varicose veins and telangiectatic veins). With regard to the elimination of collateral and incompetent perforating veins, sclerotherapy competes with phlebextraction and with ligation of perforating veins or endoscopic dissection of perforating veins. A discussion of these latter techniques is beyond the scope of this chapter. In the treatment of valvular insufficiency of truncal veins with elimination of the proximal leakage point, as well as the incompetent venous portion, surgery is currently considered to be the method of first choice. However, treatment of incompetent perforating veins and truncal veins, particularly by foam sclerotherapy, is also possible and promising, as will be later discussed.

#### 8.4 Clinical Evaluation of the Venous System of the Lower Extremity

A screening examination of the venous system should be performed before performing sclerotherapy. Prior to treatment, the phlebologist must first investigate three conditions: the presence of poorly visible varicose veins proximal to or underlying the veins to be treated, deep venous or perforator valvular insufficiency, and deep venous thrombosis [5]. If there is a proximal source of superficial or deep venous reflux of blood, injection of distal telangiectasias solely will not defend against a recurrence. Subsequently, treatment of these “feeder” ves-

sels may be necessary to ensure complete eradication of the problem. Successful sclerosis of superficial varicose veins may be rendered unsuccessful if perforating vein valvular insufficiency goes untreated. Perforating vein valvular insufficiency can lead to the development of other varicosities or telangiectasias. If the patient has deep venous valvular insufficiency, sclerotherapy of superficial varicose veins may also be inadvisable. In this setting, it is possible that the patient may encounter more severe pain when walking following sclerotherapy treatment, as the development of superficial varicose veins may have been a compensatory mechanism for an incompetent deep venous system. This is known as venous claudication [5]. Finally, because varicose veins are a risk for the development of deep venous thrombosis, a screening procedure to rule out this condition is required.

Examination of the venous system of the lower extremities can be performed without the aid of technologically advanced equipment. With the patient's entire leg exposed, visual inspection is performed. A diagram of the visual varicosities and telangiectasias, noting bulges and fascial defects, is recorded. Importantly, fascial defects may be associated with incompetent perforator veins 50–70% of the time [4]. With the patient's leg elevated, detection of fascial defects is performed by running the examiner's finger along the course of a varicosity. Depressions within the subcutaneous tissue should be marked. Incompetence of these perforating veins can be detected by having the patient stand while the examiner holds pressure on these points. If the varicose vein fails to reappear with the patient standing, release of each finger, one at a time, distally to proximally, is performed. The release point at which the varicosity reappears is marked. This site represents the most distal incompetent perforating vein [4, 5].

A clinical sign of valvular incompetence of the saphenous venous system is demonstrated by palpating for an impulse over a segment of the greater saphenous vein when the patient coughs. The presence of an impulse with coughing implies incompetence of the valve(s) proximal to this segment (cough test) [2, 4].

The percussion/Schwartz test is performed by placing one hand over the saphenofemoral junction or the saphenopopliteal junction while the other hand is used to tap lightly on a distal portion of the long or short saphenous vein. The presence of an impulse implies valvular insufficiency in the segment between the two hands [2, 4]. Palpating over the long or short saphenous vein while tapping on a dilated tributary, or vice versa, can detect whether the tributary is in direct connection with the long or short saphenous vein. False negatives can be seen in patients with previous groin surgery, obesity, and in patients with variations in their venous anatomy.

Once the dilated veins of the leg are marked, the Brodie-Trendelenburg test can be performed. With the patient in the supine position and the leg elevated 60°, emptying the varices of blood by stroking distally to proximally is performed, and a tourniquet is placed around the proximal thigh. The patient then stands up, and the leg is observed for 30 s with the tourniquet in place. The following responses can be seen:

- “Nil” test: (Competent valves of the deep and perforating veins and at the saphenofemoral junction):  
No distention of the veins for 30 s both with the tourniquet in place and after removal
- “Positive” test: (Incompetent valve at the saphenofemoral junction):  
Distention of the veins only after release of the tourniquet
- “Double” positive test: (Incompetent deep and perforating veins, with reflux through the saphenofemoral junction):  
Distention of veins with the tourniquet in place and further distention after release
- “Negative” test: (Deep and perforating valvular insufficiency):  
Distention of veins within 30 s of the tourniquet in place, and no increased

filling after release of the tourniquet. However, filling of the vein(s) after 30 s of tourniquet placement does not imply competence of perforating veins (Fig. 8.4) [2].

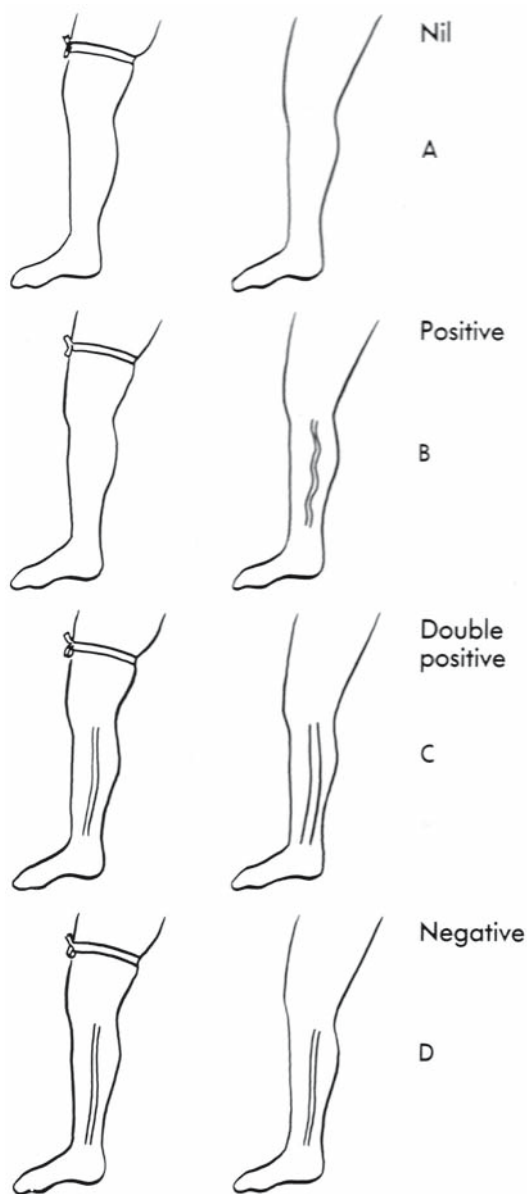
The Perthes’ test is performed by placing a tourniquet around the proximal thigh with the patient in the supine position. Then, as the patient ambulates, a decrease in distension of varicosities implies a primary process without existing deep venous system disease. A constant distention implies a secondary process with impairment of the calf-muscle pump and deep venous patency, and an increase in distention implies deep venous obstruction [2, 4, 5].

Placing a tourniquet around the calf right below the popliteal fossae with the patient in the supine position can help to determine perforator valvular dysfunction. An indication of incompetent perforating veins occurs when the veins become more prominent and dilated as the patient ambulates [2, 4, 5].

These “hands-on” tests supply information but are not precise. These tests also do not recognize deep vein thrombosis and are not the most effective means of localizing abnormal valves. Discussion of noninvasive diagnostic techniques follows.

## 8.5 Diagnostic Examination of the Venous System of the Lower Extremity

Varicose vein disease is the abnormal functioning of the venous system of the lower extremity due to valvular dysfunction, which includes ectatic veins and varicosities. When considering sclerotherapy treatment, the phlebologist must first evaluate the patient to determine whether the venous segment is simply a case of telangiectatic veins or more serious varicose veins. The examination begins with the patient’s venous history, including duration of condition, prior treatments such as sclerotherapy, ligation, phlebectomy, and endoscopic dissection,



**Fig. 8.4A-D.** Interpreting the Brodie-Trendelenburg test. **A Nil:** no distention of the veins for 30 s both while the tourniquet remains on and also after it is removed implies a lack of reflux. **B Positive:** distention of the veins only after the tourniquet is released implies reflux only through the saphenofemoral junction (SFJ). **C Double positive:** distention of the veins while the tourniquet remains on and further distention after it is removed implies reflux through perforating veins as well as the SFJ. **D Negative:** distention of the veins while the tourniquet remains on and no additional distention once it is removed implies reflux only through perforating veins. (Reprinted with permission from Goldman MP (1991) *Sclerotherapy: Treatment of varicose and telangiectatic leg veins*. Mosby, St. Louis.)

any history of deep vein thrombosis or superficial thrombophlebitis, and the severity of symptoms and their affect on the patient, such as with extensive standing, walking or leg elevation.

Indications of varicose vein disease include:

- Pain and/or aching in the leg(s) that is alleviated with leg elevation, exercise, or compression hosiery
- History of phlebitis
- Large, long-standing varicose veins
- Abundance of telangiectatic veins near the medial malleolus
- Venous stasis dermatitis
- Ulceration
- Rubor

Patients who should be evaluated with venous Doppler ultrasound are those with hemodynamically significant varicose veins [5, 7, 8]. Also, the presence of a radiating flare of telangiectasias from a central point may indicate an underlying incompetent perforator vein [4]. Untreated deep venous or perforator valvular insufficiency may prevent successful sclerotherapy of the superficial varicose vein, or treatment may be contraindicated in cases where superficial varicosities serve as a compensatory mechanism. Poorly visible varicose veins proximal to or underlying the veins to be treated will also need to be investigated. Patient selection for examination with venous Doppler includes:

- Varicosities greater than 4 mm in diameter
- Any varicosity over 2 mm in diameter extending throughout the entire calf or thigh
- Any varicosity extending into the groin or popliteal fossae



- A “star-burst” cluster of telangiectasias, especially if over the usual points of perforating veins (midposterior calf, medial knee, medial mid thigh, medial distal calf)
- Previous venous surgery or sclerotherapy with poor results or recurrence of varicosities
- Obesity

Instrumentation for the lower-limb Doppler examination should use ultrasound imaging frequencies in the 5- to 10-MHz range [4, 5, 7, 8]. Generally, a 7.5- to 10-MHz imaging probe is used to visualize superficial and perforating veins, and a 5- to 7.5-MHz probe is used for imaging deep and muscle veins [5]. The five important Doppler features of blood flow in normal veins are listed in Table 8.4.

Continuous wave Doppler ultrasound emits a continuous beam of ultrasound waves that detect red blood cells moving within the vessel. Sound waves reflect back to the receiving probe at a different frequency. This change in frequency is converted to an audible sound. Frequencies in the 7- to 10-MHz range are optimal for examining superficial vessels whereas lower frequencies (5–7 MHz) are required for examination of deeper vessels. When incompetent valves are present, compression of the muscles proximal to the Doppler probe produces a long sound while blood flows unhindered distally through incompetent valves [4]. When compression is released, flow stops, as does the

**Table 8.4.** Important Doppler features of blood flow in normal veins

1. Spontaneous flow in the proximal deep veins with the patient at rest
2. Phasic flow with respiration
3. Cessation of blood flow in response to the Valsalva maneuver
4. Augmentation of blood flow by circumferential compression of the extremity distal to the site of Doppler examination
5. Unidirectional flow towards the heart

emitted sound. During compression of incompetent valves distal to the probe, normal proximal flow is heard, but when compression is released, blood flows distally emitting a prolonged sound because incompetent valves cannot prevent retrograde flow [4, 5].

The deep venous system is evaluated for acute or chronic damage to the valvular system and for the presence of deep vein thrombosis. Demonstration of normal, one-way flow at the iliofemoral junction in the groin, the popliteal vein in the popliteal fossae, and the posterior tibial vein in the medial malleolar region should be evaluated in a warm room to reduce venoconstriction and with the patient lying down. Examination of the superficial venous system is usually performed with the patient standing.

Examination of the superficial venous system begins with the patient in the standing position, which will enhance ultrasound imaging. The examination is facilitated with the patient standing on a stool (approximately 6 in. off the floor). With the patient bearing weight on the opposite extremity, the limb under study is abducted at the hip with the knee slightly flexed. The common femoral vein in the groin is imaged first and followed proximally to image the external iliac vein. Doppler recordings are taken during the Valsalva maneuver with spontaneous and phasic flow and with manual calf or thigh compression and release. The vein should be imaged in the sagittal plane with the angle of the Doppler probe less than 60°. Reflux is designated by a reverse flow signal for longer than 0.5 s after release of compression. Similar studies and maneuvers are performed on the common femoral vein. The saphenofemoral junction is next identified. The long saphenous vein just distal to this junction is examined during calf or thigh compression and release. During a Valsalva maneuver, a continuous and pronounced reflux signal is a reliable sign of valvular insufficiency. However, mild and brief reflux can be found in 15% of normal individuals. An equivocal result may require a Duplex ultrasound (DUS) examination [4].

Assessments of long saphenous vein competence in the proximal, mid, and distal thigh are then performed. Assessments with calf compression are made. During the thigh exam, any

8

perforating veins penetrating the muscle fascia that communicate with the long saphenous system and femoral vein should be examined. Perforating veins should be assessed for competency. Incompetence of perforator veins exists if there is deep-to-superficial flow for longer than 0.5 s on manual compression above or below the ultrasound transducer [9]. The popliteal vein is examined in three segments: distal to, proximal to, and at the same level of the saphenopopliteal junction. The saphenopopliteal junction, if located, should be assessed. The short saphenous vein is examined for competence in the proximal, mid, and distal calf segments. Examination of the medial and lateral calf veins takes place with the patient sitting with the leg extended horizontally and the foot resting on the examiner's knee with the calf muscle relaxed. Assessment of the proximal calf segment of the long saphenous vein is examined for competence and patency from the knee to ankle. The posterior arch vein can also be located and assessed in most patients. Calf-perforating veins from the posterior arch complex (gastrocnemius and soleal perforators or posterior tibial perforators) can be identified and examined for competency by compression above and below the transducer [9].

Deep-to-superficial blood flow greater than 0.5 s on calf or foot compression is considered incompetent. Distal segments of the gastrocnemius vein can similarly be assessed. Doppler studies should also be performed on the posterior tibial vein from the proximal calf to the ankle. The peroneal vein is examined from the same transducer position. The anterior tibial vein only needs assessment in suspected cases of deep venous thrombosis. Routine assessment of the lateral calf and soleal veins is unnecessary unless there are obvious lateral calf varices [9].

Duplex venous scanning is the most advanced modality used to investigate venous disease in the sclerotherapy patient. Duplex scanning is important in the clinical decision-making process as well as being useful in the serial assessment of disease progression and treatment effectiveness. Duplex sonography combines venous Doppler blood flow analysis with pictorial anatomic information of ultraso-

nography. This system is commonly used for evaluation of the deep venous system for thrombosis. Most technicians can accurately evaluate the superficial venous system as well, including detection of blood flow and velocity and vessel structure and diameter. The scanning device involves a B-mode imaging ultrasound probe combined with a 3-MHz directional pulsed Doppler ultrasound [9]. Visual assessment of blood flow is made possible with color-duplex imaging, which superimposes blood flow information from the pulsed Doppler onto the B-mode ultrasound image. Color duplex stands apart from the standard duplex instrument because color duplex allows for both anatomic structures and flow patterns to be visualized in one image, allowing the vessel to be located and followed more easily than with standard duplex instrumentation [9]. Blood flow is displayed in color while stationary anatomic structures are represented in shades of gray [9].

Areas of phlebology where duplex examination is essential as a diagnostic tool include the diagnosis and evaluation of the extent of deep venous thrombosis. Accuracies of over 90% have been achieved in the femoropopliteal segment and in 80% of the diagnosis of calf vein thrombosis [9]. Another application of duplex examination is in the evaluation of deep and superficial venous insufficiency. This pretreatment evaluation will ensure that all significant areas of reflux are addressed. Duplex scan is the most important diagnostic tool in the management of recurrent varicose veins where primary anatomy is altered by previous surgical procedures. Duplex examination is also utilized to accurately guide sclerosant injections into incompetent perforator and impalpable superficial axial incompetent veins and reduce adverse effects, including intraarterial injections and deep venous thrombosis [7–9]. And finally, duplex examination is used in saphenous vein mapping prior to procedures such as coronary bypass surgery to ensure venous patency, size (diameter greater than 3.0 mm), and length, and to confirm that the long saphenous vein is not serving as collateral circulation in chronic deep venous insufficiency [9] (Tables 8.5, 8.6).

**Table 8.5.** Diagnostic evaluation of the venous system of the lower extremity

	Preferred method	Pitfalls	Additional methods
Deep veins	Doppler ultrasound	Differentiation SFJ versus CFV SPJ versus popliteal vein	PPG/LRR Venography Duplex
Saphenous trunks	Doppler ultrasound	Differentiation SFJ versus CFV SPJ versus popliteal vein	Percussion Trendelenburg Venography Duplex
Tributaries of saphenous trunks	Doppler ultrasound	N/A	Percussion Duplex
Perforating veins	Clinical exam and Doppler ultrasound	50–80% accurate	Venography Duplex Thermography Fluorescein
Contribution of superficial versus deep reflux	PPG/LRR	N/A	AVP Duplex velocities
Functional evaluation	PPG/LRR	N/A	AVP Foot volumetry
Vulvar varices	Clinical exam for LSV reflux	N/A	Varicography

PPG photoplethysmography, LRR light reflection rheography, SFJ saphenofemoral junction, CFV common femoral vein, SPJ saphenopopliteal junction AVP ambulatory venous pressure, LSV lesser saphenous vein

**Table 8.6.** Doppler ultrasound versus duplex scanning

	Doppler	Duplex
Portability	Portable	Not easily portable “Luggable” units available
Ease of use	Requires short period of training and experience	Requires longer period of training
Cost (approximate)	Unidirectional: \$300 Bidirectional: \$2,500	Grey scale: \$40,000 Color: \$150,000 and up
Information obtained	1. Patency, competence of venous valves 2. DVT in thigh (? calf)	1. Patency, competence of venous valves 2. DVT with greater accuracy 3. Velocity of reflux 4. Anatomy and anomalies of venous system 5. Termination of SSV 6. Thrombosis versus sclerosis
Reliability	Less reliable because of blind, nonpulsed sound beam	More reliable because of actual visualization of vein being examined

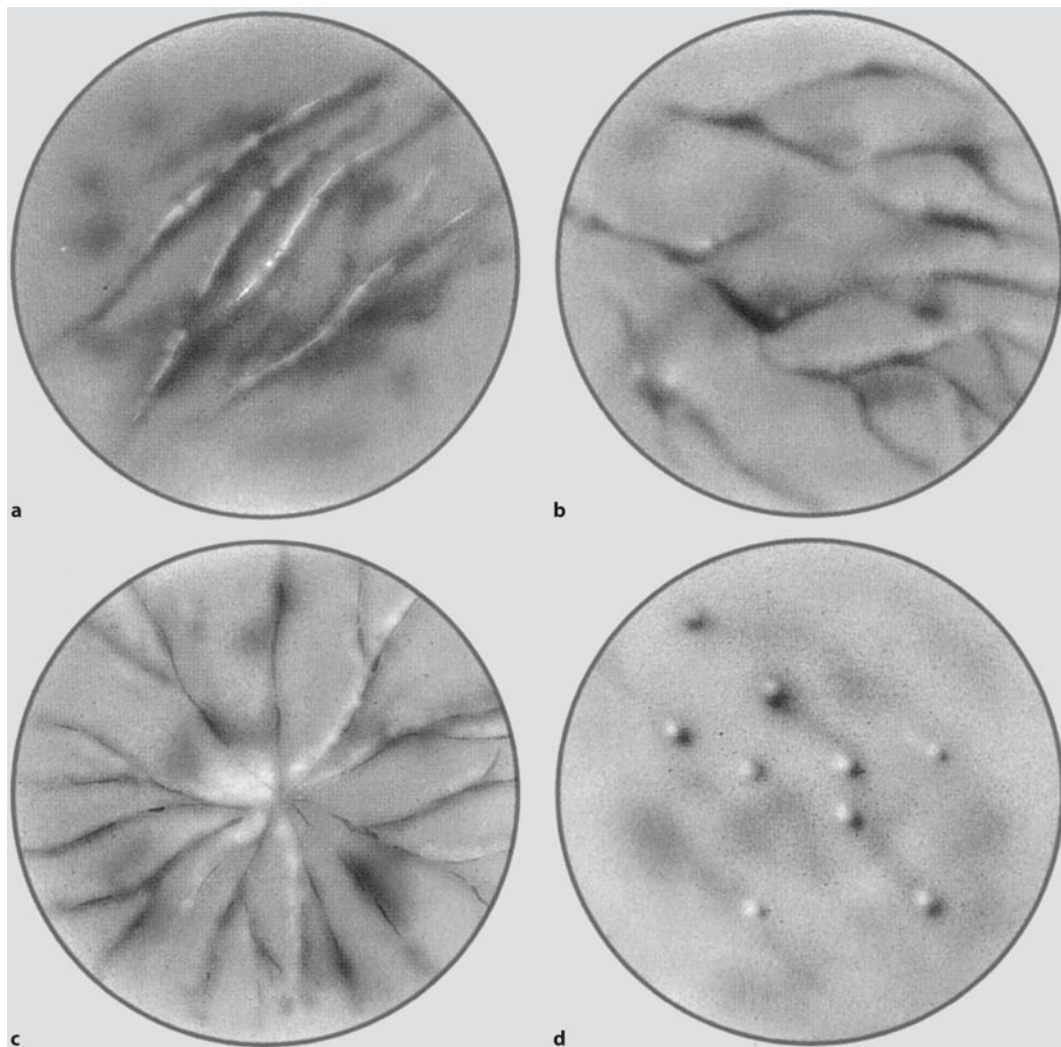
DVT deep vein thrombosis, SSV short saphenous vein

## 8.6 Treatment of Telangiectasias

Telangiectasias and varicose veins less than 2 mm in diameter may safely and effectively be treated with sclerotherapy alone (Fig. 8.5). However, it is important to emphasize that thorough assessment for any significant underlying incompetent vessels be completed first.

### 8.6.1 Venous Segment Preparation

Sclerotherapy of telangiectatic veins should be performed with the patient in the supine position and the phlebologist comfortably seated. The surface of the injection site should first be drenched with 70% isopropyl alcohol. This not only cleanses the site, but it also enhances visualization of the telangiectasia(s) because alcohol changes the index of refraction of the skin



**Fig. 8.5a–d.** Four types of telangiectasias: **a** Simple, **b** arborized, **c** spider, **d** papular. (Reprinted with permission from Goldman MP (1991) *Sclerotherapy: Treatment of varicose and telangiectatic leg veins*. Mosby, St. Louis.)

causing it to become more transparent. Additionally, the alcohol may also cause vasodilatation of the telangiectasias [2]. Alternative techniques used to enhance visualization include wiping the skin with a solution composed of 70% isopropyl alcohol and 0.5% acetic acid, recommended by Sadick who found this solution to better improve the angle of refraction than alcohol alone, and by rubbing a very small amount of the sclerosing solution into the skin, as practiced by Scarborough and Bisaccia [2].

These phlebologists also use Aethoxysklerol (polidocanol), which contains alcohol [2]. Magnifying devices with a 2+ or 3+ diopter should also be used to further enhance visualization of the telangiectasia(s) (Table 8.7). The use of a lamp, or any other source of direct lighting, over the injection site should be avoided because this will produce a glare. Visualization is maximized with indirect, shadow-free lighting.

To distend the diameter of vessels that appear to be too small for injection, either the pa-

**Table 8.7.** Sclerotherapy supplies and distributors

Supplies	Distributors
Magnifying glasses	Clip-on Loupes: Almore International Portland, OR 97225, USA Opticald: Edroy Products Co., Inc. Nyack, NY 10960, USA
Headband-mounted simple binocular magnifiers	Mark II Magni-Focuser: Edroy Products Co., Inc. Nyack, NY 10960, USA Optivisor: Donegan Optical Company 15549 West 108th Street Lenexa, KS 66219, USA
Simple binocular loupes	Multidistance Headband Loupe: Edroy Products Co., Inc. Nyack, NY 10960, USA Precision Binocular Loupe: Almore International Portland, OR 97225, USA
Binocular loupes	Design for Vision New York, NY 10010, USA N1064 Oculus: Storz Instrument Company St. Louis, MO 63122, USA Westco Medical Corporation San Diego, CA 92138, USA See Better Loupe: Edroy Products Co., Inc. Nyack, NY 10960, USA
Syringes	Luer Lok or non-Luer Lok: Becton-Dickinson & Company Rutherford, NJ 07070, USA Plastipak Eccentric Syringe: Becton-Dickinson & Company Rutherford, NJ 07070, USA



Table 8.7. Continued

Supplies	Distributors
Material for foam generation	Injekt syringe with Luer-Lock (green) 10 ml, for foam generation; No. 4606728 B, BRAUN, Melsungen Combidityn adapter, f/f, for the safe connection of the syringes during foam generation; No. 5206634 B, BRAUN, Melsungen Omnifix syringe with Luer-Lock 10 ml, for foam generation; No. 4617100 B, BRAUN, Melsungen www.bbraunusa.com/ 824 Twelfth Ave., Bethlehem, PA 18018, USA
Material for sterile filtration of ambient air	Sterifix 0.2 µm sterile filter no. 4099206 B, BRAUN, Melsungen www.bbraunusa.com/ 824 Twelfth Ave., Bethlehem, PA 18018, USA
Compression hosiery	Camp: Camp International, Inc. P.O. Box 89 Jackson, MI 49204-0089, USA Jobst: The Jobst Institute, Inc. P.O. Box 652 Toledo, OH 43694, USA JuZo: Julius Zorn, Inc. (JuZo) P.O. Box 1088 Cuyahoga Falls, OH 44223, USA Legato: Freeman Manufacturing Co. 900 W. Chicago Rd. Sturgis, Michigan 49091-9756, USA Medi: Medi USA (American Weco) 76 W Seegers Rd. Arlington Heights, IL 60005, USA Sigvaris: Sigvaris P.O. Box 570 Branford, CT 06405, USA Venosan: Freeman Manufacturing Co. 900 W Chicago Rd. Sturgis, Michigan 49091-9756, USA
Foam pads	Reston: 3M Health Care St. Paul, MN 55144-1000, USA or: D-46325 Borken, Germany STD Pharmaceutical Field Yard, Plough Lane Hereford HR4 0EL, UK
Color-duplex scanner	Apogee 800: Advanced Technology Laboratories Solingen, Germany

Table 8.7. Continued

Supplies		Distributors
Needles	21-, 23-, or 25-gauge butterfly	Abbott Hospitals, Inc. North Chicago, IL 60064, USA Surflo Winged Infusion Set: Terumo Corporation Tokyo, Japan
	26- or 27-gauge	Allergy: Becton-Dickinson & Company Ft. Lauderdale, FL 33314, USA Yale: Becton-Dickinson & Company Ft. Lauderdale, FL 33314, USA
	30-gauge	Acuderm: Acuderm, Inc. Ft. Lauderdale, FL 33314, USA Delasco: Dermatologic Lab and Supply, Inc. Council Bluffs, IA 51503, USA Precision Glide: Becton-Dickinson & Company Rutherford, NJ 07070, USA
	33-gauge	Delasco: Dermatologic Lab and Supply, Inc. Council Bluffs, IA 51503, USA Hamilton: Hamilton Company Reno, NV, USA (800) 648-5950
Tape dressings	Localized pressure	Coban Tape: Medical Surgical Division/3M St. Paul, MN 55144, USA Medi-Rip Bandage: Conco Medical Company Bridgeport, CT 06610, USA
	Minimal pressure	3M Microfoam Surgical Tape: Medical Surgical Division/3M St. Paul, MN 55144, USA Tubigrip Tubular Support Bandage: Seaton Products, Inc. Montgomeryville, PA, USA

tient stands for 5 min and is then placed in the Trendelenburg position or a blood pressure cuff is inflated to approximately 40 mmHg proximal to the injection site while the patient is supine.

### 8.6.2 Sclerotherapy Technique for Telangiectasias

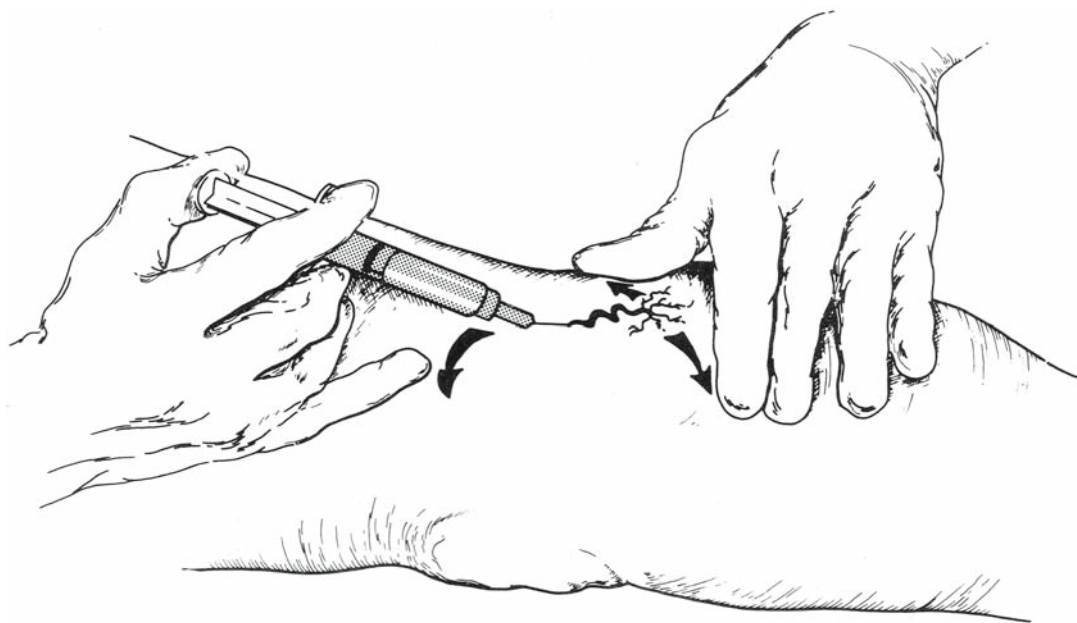
When performing sclerotherapy, the skin should be held taut to facilitate cannulating the vessel. This can be achieved by stretching the skin in opposite directions perpendicular to the vessel with one hand. Then, with the opposite hand that is holding the syringe, the fifth finger

is used to stretch the skin in a third direction away from the vessel. These three tension points ensure that the skin is taut and ready for injection (Fig. 8.6). The ultimate goal is to enter the vessel and inject the sclerosant within, and not outside, the vessel wall [2]. A 30-gauge needle will usually yield the desired results, with maximum comfort for the patient as well. However, some phlebologists recommend using either a 32- or 33-gauge stainless steel needle for the intravascular injection of smaller telangiectatic vessels, even though these needles are nondisposable, require sterilization, and dull and bend easily. Also recommended is a 3-ml syringe filled with 2 ml of sclerosant, as this allows for slow, low-pressure injection of the sclerosing solution and avoids “blow-out” of the vessel and extravasation. Each injection should take approximately 5–15 s [1]. The 3-ml syringe is also an ideal size and can be manipulated easily (Table 8.7) [2].

I prefer to aspirate enough air to occupy the needle hub prior to injecting. The air that enters the vessel displaces the blood and assures

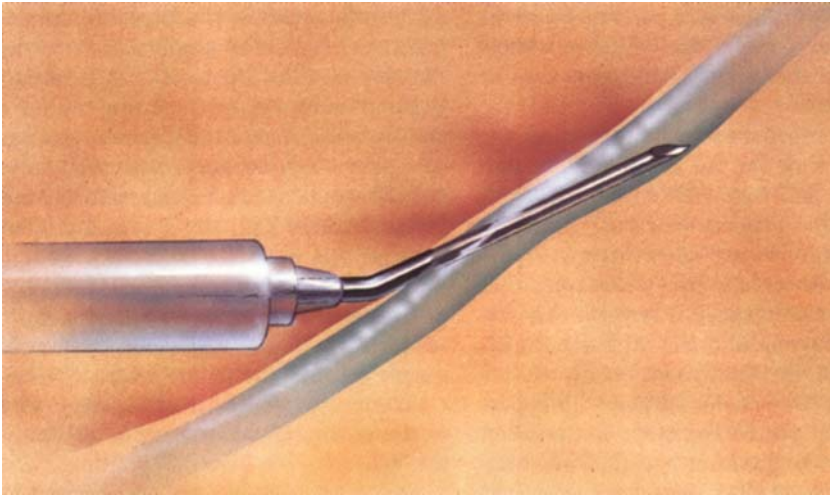
that the needle is in the vein. If a diffuse urticarial-like blanching is observed, the needle is not in the lumen (the air has entered the surrounding tissue). Additionally, as the air pushes the blood through the vessel, the sclerosant makes undiluted contact with the intima, maximizing irritation. Missing the lumen is probably due to the needle being under and not within the vessel.

Since most telangiectatic leg veins are located in the superficial dermis of the skin, I recommend placing the needle flat against the skin and penetrating the skin almost parallel to the surface. To ensure depth of penetration and that the vessel is not exceeded, the needle should be bent approximately 45° with the bevel up (Fig. 8.7) [2]. Injecting the vessel with the bevel up lessens the chance of transection. With proper technique and magnification, visualization of the bevel/tip of the needle through the skin and into the vessel is possible to ensure correct placement within the vessel lumen. Further advancement is not required or recommended. Whether sclerotherapy should pro-



**Fig. 8.6.** Illustration of proper hand placement to exert three-point traction to aide in needle insertion. Injection is made into the feeding “arm” of the “fingers” of

the spider vein. (Reprinted with permission from Goldman MP (1991) *Sclerotherapy: Treatment of varicose and telangiectatic leg veins*. Mosby, St. Louis.)



**Fig. 8.7.** The needle is bent to 45° with the bevel up to facilitate accurate insertion into the superficial telangiectasia. (Reprinted with permission from Goldman MP

(1991) *Sclerotherapy: Treatment of varicose and telangiectatic leg veins*. Mosby, St. Louis.)

ceed proximally to distally (the French school), distal to proximal (the Swiss school), or random-site injection, is acceptable and under ongoing discussion. Injecting the most proximal “feeder” vessel in a telangiectatic cluster is preferred. I also advise injecting the “straightest” and largest vessel within the cluster, no matter the direction of orientation, to avoid vascular transection. Edema (urticarial) and erythema become apparent in 2–30 s postinjection and may last 30 min to several hours. The patient may also complain of muscle cramps in the calf or thigh with hypertonic saline and hypertonic glucose/saline injections. This usually lasts less than 3 min, and the patient should be forewarned. Gentle massaging may help with cramping. A bleb at the site of the needle may appear during injection. Removal of the needle and application of digital massage should be performed immediately. I prefer to inject a generous amount of normal saline or 1% lidocaine if this occurs to reduce the pain and help dilute the sclerosant in the tissue. These small infiltrates may leave small brown macules, which usually disappear in 3–12 weeks. It is important to watch the needle site while injecting, rather than the course of the sclerosing solution through the vessel, and to avoid pushing the in-

jecting hand forward while pushing the plunger. If the injection site and needle placement are carefully monitored, then extravasation can be limited. Repeat treatment on persistent vessels can be performed as early as 3 weeks after the previous treatment. Larger-diameter vessels (greater than or equal to 2 mm) may thrombose. This is easily recognized when the patient returns for follow-up and may be apparent as early as 1 week postsclerotherapy. The vessel appears bluish-purple and does not blanch under pressure. Treatment consists of making a small “stab” incision over the vessel with a number 11 blade and milking out the dark, syrupy blood. The wound is covered with a topical antibiotic ointment and bandage and usually heals well. Maximum recommended dosages of sclerosants vary with the different types and concentrations (Tables 8.8 and 8.9). Many phlebologists recommend a treatment session time of approximately 15–30 min and not more than 12 cc of sclerosant per session [10]. Sclerotherapy requires great concentration and a steady hand. Clinician fatigue greatly reduces efficacy.

Compression should be applied to the injected site immediately postinjection. Massaging the injected vein(s) immediately after with-

Table 8.8. Sclerosing agents

Classes	Agents	FDA approval	Ingredients	Advantages	Disadvantages
Osmotic agents	Hypertonic saline	Approved abortifacient	18–30% saline	Lack of allergenicity	Damage to cellular tissues Produce ulcerations Necrosis Hyperpigmentation Pain Muscle cramping
	Hypertonic glucose/saline (Sclerodex)	Not approved	250 mg/ml of dextrose, 100 mg/ml of sodium chloride, 100 mg/ml of propylene glycol, and 8 mg/ml of phenethyl alcohol	Minimized pain Less muscle cramping	Superficial necrosis Allergic reaction Hyperpigmentation Mild pain
Chemical irritants	Chromated glycerin (Scleremo)	Not approved	1.11% chromated glycerin	Rare posttreatment hyperpigmentation, necrosis, and bruising, even if injected extravascularly	Weak agent, therefore requires more treatment sessions High viscosity Pain
	Polyiodinated iodine (Variglobin, Sclerodine)	Not approved	A water solution of iodide ions, sodium iodine, and benzyl alcohol	Direct destruction of the endothelium	Necrosis Pain
Detergent sclerosing solutions	Sodium morrhuate	Approved	Sodium salts of the saturated and unsaturated fatty acids in cod-liver oil	N/A	Extremely caustic Necrosis Allergic reactions, including anaphylaxis Pain
	Ethanolamine oleate (Ethamolol)	Not approved	Ethanol amine and oleic acid	Decreased risk of allergic reaction	Hemolysis <sup>a</sup> Renal failure with recovery <sup>a</sup> Constitutional symptoms <sup>a</sup> Pulmonary toxicity Allergic reactions Pain
	Sodium tetradecyl sulfate	Approved	Sodium 1-isobutyl-4-ethyloctyl sulfate, benzoyl alcohol 2% (anesthetic), and phosphate	N/A	Epidermal necrosis Allergic reaction Hyperpigmentation <sup>b</sup> Pain
	Polidocanol (Aethoxysklerol)	Pending	Hydroxypolyethoxydodecane, distilled water, and ethyl alcohol	Will not produce ulcerations Necrosis is very rare Allergic reaction is very rare Less hyperpigmentation Painless	Necrosis (rare) <sup>a</sup> Allergic reaction (rare)

<sup>a</sup> Dose related    <sup>b</sup> Posttreatment hyperpigmentation is worse than with that of all other sclerosing solutions



**Table 8.9.** Recommended concentration/volume of sclerosing solutions

Agents	Vein diameter	Recommended concentrations	Recommended maximum quantity injected per treatment session
Chromated glycerin (Scleremo)	<0.4 mm	50% 100%	N/A
Ethanolamine oleate (Ethamolin)	20.4–0.5 mm 20.6–2 mm	2% 5%	<12 ml
Hypertonic glucose/saline (Sclerodex)	0.4–0.5 mm 0.6–2 mm	N/A	10 ml; 1 ml per injection site, with 5 cm between each site
Hypertonic saline	20.4–0.5 mm 0.6–2 mm	11.7% 23.4%	N/A
Polidocanol (Aethoxysclerol)	20.4–0.5 mm 0.6–2 mm 3–5 mm >5 mm	0.25% 0.5% 0.75% 1–2% 3–5%	10 ml of a 6% solution
Polyiodinated iodine (Sclerodine) (Variglobin)	0.4–0.5 mm 0.6–2 mm 3–5 mm >5mm	0.1% 1% 2% 3–12%	3 ml of a 6% solution
Sodium morrhuate	20.4–0.5 mm 0.6–2 mm 3–5 mm	1% 2.5% 5%	N/A
Sodium tetradecyl sulfate	20.4–0.5 mm 0.6–2 mm 3–5 mm >5 mm	0.1% 0.25% 0.5–1% 2–3%	4 ml of a 3% solution by British manufacturers, and 10 m of a 3% solution by United States and Canadian manufacturers

drawing the needle, using firm pressure and “milking” the sclerosant toward the smallest telangiectatic branches, provides immediate compression and decreases the chance of sclerosant and venous blood reflux from the puncture site and into the surrounding tissue. Massaging may also limit bruising and minimize stinging and burning. Adequate compression following each sclerotherapy session is essential for optimization of both short- and long-term treatment results. Direct contact of the sclerosed endothelium via compression results in more effective fibrosis and allows for the use of lower concentrations of sclerosant [11, 12, 13]. Compression also reduces the extent of thrombus formation, which in turn decreases the incidence of vessel recanalization. Postsclerosis

hyperpigmentation and telangiectatic matting (TM) have also been shown to be reduced with the use of postsclerotherapy compression [12, 14]. Compression following treatment also improves efficacy of the calf-muscle pump and aids in more rapid dilution of the sclerosant from the deep venous system, thereby reducing the risk of deep venous thrombosis [2, 11, 12].

Patients who undergo sclerotherapy for uncomplicated telangiectasias usually can wear lighter-weight, graduated compression stockings (class I, 20–30 mmHg). These garments are applied at the end of the treatment session, with the treated leg(s) elevated approximately 45° above the horizontal. Additionally, postsclerotherapy cotton balls or rolls or foam pads are applied over the larger treated vessels and ap-

plied firmly in place with adequate pressure with a wide elastic bandage prior to application of the graduated compression garment (Table 8.7). Intravascular clots and phlebitis often occur when larger vessels are not additionally compressed with padding. Some phlebologists advocate removal of the compression garment 6 weeks after sclerotherapy, while others advocate wearing compression for no more than 8 h postsclerotherapy [10, 11, 12, 13]. Those who advocate 8 h of postsclerotherapy compression for telangiectasias feel the final outcome is no different than with patients who wear compression for 6 weeks [14]. The general recommended duration for wearing compression stockings varies from 3 days to 6 months, depending on—among other things—the diameter of the vessel(s). Studies show the maximum benefits of compression garments, no matter how long they were worn, were seen between 3–6 months following treatment [12]. The most improvement was seen in patients who wore the compression stockings for 6 months. However, some improvement can be seen in patients who wear the compression stockings for only a few days [12]. Some phlebologists give the patient the option of wearing graduated compression stockings for a period of 1–3 weeks, after expressing to the patient that optimization of treatment is reached with a longer duration of compression. In general, small telangiectasias less than 1 mm in diameter may not require any postsclerotherapy compression [6].

After completion of the sclerotherapy session, the patient should walk for approximately 10–30 min immediately following the procedure. The patient should maintain normal day and nighttime activities, including at least a 1 h walk per day for 1 week. Hot showers or baths and strenuous physical activity (aerobics, weight lifting, squatting, etc.) should be avoided for the first week after treatment. Sclerotherapy is considered the standard treatment for intracutaneous varicose veins (spider, telangiectatic, and reticular veins), with an 80–90% improvement rate [15].

## 8.7 Sclerotherapy Techniques for the Treatment of Varicose Veins

Varicose veins usually develop from reticular veins or larger veins (including the saphenous veins and their tributaries) that reside in or below the subcutaneous fat [12]. The production of an intravascular thrombus produced by sclerotherapy has generally been felt to be a prerequisite for successful varicose vein sclerosis. However, the presence of an intravascular thrombus can serve as an impediment to complete resorption of the vein as a result of subsequent vessel-wall repair and recanalization [3]. Often, it may be more than a year before the recanalized, reconstituted vein can be visibly or palpably discerned [3]. Intravascular thrombosis is minimized utilizing the ultrasound-guided microfoam sclerosing technique, which “pushes” the blood out of the vessel segment, and by applying post-injection-sustained compression to the treated vein. Immediate and sustained compression minimizes the duration required for complete resorption of the vein because adequate compression applied immediately postinjection diminishes the volume of the intraluminal thrombus, even if full-thickness mural destruction has occurred [3]. The goal of varicose vein sclerotherapy, therefore, is transformation of the target vessel into a fibrous chord without the possibility of recanalization.

Varicose vein sclerotherapy requires thorough pretreatment evaluation and planning. Proper patient selection is critical and should include a history and physical examination appropriate for the extent of venous disease and, when indicated, laboratory studies to rule out altered coagulable states [16] (Table 8.10). The patient should also be educated about the procedure, including limitations, alternative treatments, potential adverse side effects, risks, and complications (Table 8.11). Baseline and follow-up photographs are useful to document the clinical extent of disease, location of treatment vessels, any preexisting pigmentation or scarring, and postsclerotherapy outcome and response to treatment. DUS, ve-

**Table 8.10.** Contraindications to sclerotherapy treatment

Absolute	
	Acute superficial or deep vein thrombosis
	Advanced peripheral arterial occlusive disease (stages 3 or 4)
	Confinement to bed
	Hyperthyroidism <sup>a</sup>
	Immobility
	Known allergy to the sclerosant
	Local infection in the treatment site, or severe generalized infection
	Pregnancy <sup>b</sup>
	Severe systemic disease
Relative	
	Allergy to heparin or aspirin
	Bronchial asthma
	History of coagulopathies
	Inability to ambulate
	Late complications of diabetes
	Leg edema
	Marked allergic diathesis
	Peripheral arterial occlusive disease (stage 2)
	Poor general health
	Thrombophilia with history of deep vein thrombosis
	Use of medications that may affect clotting mechanisms or platelet functions (estrogens, progesterones, etc.)

<sup>a</sup> Only when sclerosing agent contains iodine

<sup>b</sup> Within the first trimester and after the 36th week of gestation

**Table 8.11.** Complications and risks of sclerotherapy

Allergic reaction, including anaphylaxis
Hyperpigmentation
Necrosis
Nerve damage
Orthostatic hypotension
Scintillating scotomas
Telangiectatic matting
Thromboembolism
Thrombosis (deep or superficial) pulmonary embolism
Thrombophlebitis

nous Doppler studies, photoplethysmography (PPR), light-reflection rheography (LRR), air plethysmography, and other diagnostic studies should be reserved for appropriate patients with symptoms of venous disease, large diameter vessels (greater than 4 mm in diameter), or large numbers of telangiectasias indicative of venous hypertension (Table 8.5). The routine use of these expensive modalities in the presence of limited numbers of telangiectasias or vessels less than 1 mm in diameter is discouraged [16]. Diagnostic studies may be appropriate in patients with exacerbation or rapid recurrence of their disease process after sclerotherapy.

There are no uniformly agreed upon techniques or standards available for sclerotherapy of large varicose veins. A common assumption exists that veins larger than 10 mm in diameter are sclerosant resistant and require surgical removal, especially when associated with saphenofemoral incompetence. However, Kanter has nicely demonstrated that treatment of these large-caliber incompetent veins utilizing ultrasound-guided sclerotherapy (UGS) and 3% sodium tetradecyl sulfate (STS) is possible, with an overall recanalization rate of 10% at 2-year follow-up [7, 8]. Furthermore, Kanter also showed that injection of a 2-ml volume of sclerosant is less effective and is associated with more side effects than a 1-ml volume of sclerosant [8]. Sclerotherapy is generally performed in order of leakage points and from the largest to smallest varicose vein(s), proximal to distal. Recommended concentrations and volumes of sclerosants are listed in Table 8.9. A smooth-moving, disposable or glass 3-cc syringe is required for sclerotherapy, as well as a half- to 1-inch long small diameter cannula or butterfly catheter (23–27 gauge). The various concentrations of the sclerosant used should be carefully labeled on each syringe prior to use. Cotton balls or other padding, and precut tape attached to the side of the surgery tray, should be readily available. Equipment and medications for use in case of allergic reactions should also be on hand. DUS scanning during sclerotherapy allows the phlebologist to precisely locate and treat the pathologic components of the venous system under direct observation and is far

superior to the handheld Doppler, especially when sclerosing incompetent saphenous junctions, adjacent truncal veins, and perforating veins [15] (Tables 8.5 and 8.6). Although cannulation of the treatment vessel can be performed with the patient standing, injection of the sclerosant is usually performed with the patient in the horizontal position. Areas of reflux are identified with Doppler or duplex scanning and prepped prior to injection. The venous segment to be treated is punctured, preferably during UGS or DUS visualization, so that the intravascular injection can be controlled. When treating saphenofemoral incompetence, the injection site should not be less than 3–4 cm distal to the saphenofemoral junction to prevent injection into the femoral vein [7]. Visualization by DUS scanning ensures that the sclerosant is prevented from actually being deposited at the level of the saphenofemoral junction into the femoral vein [3]. However, even if the sclerosant enters the femoral vein, significant mural damage is unlikely because of the rapid dilution associated with the large volume of intravascular blood and the dynamic rate of flow in the vein [3]. Some authors recommend intermittent compression postinjection utilizing the ultrasound transducer [15]. Compression with the probe provides assessment of venous spasm as well as the length of sclerosis of the treated segment. The treatment of large varicose veins requires greater volumes and higher concentrations of sclerosant than smaller ectatic veins [7, 8]. Volumes ranging from 1 to 12 ml per injection site have been recommended. Each milliliter of sclerosant should be injected over an 8- to 15-s period, with 30- to 90-s intervals between injections. Immediate and sustained postinjection compression should be performed. The procedure is repeated proximally to distally along the vessel at approximately 5- to 10-cm intervals for a maximum total volume of 15 ml. A “second look” DUS examination, repeated 1–2 min postinjection, can reveal any persistently patent segment(s) for reinjection, provided the recommended volume of sclerosant has not been exceeded. Immediately postsclerotherapy, class II (30–40 mmHg) or class III (40–50 mmHg) graduated thigh-high, compression stockings are applied with the patient’s legs ele-

vated approximately 45°, along with focal padding over treated areas. Sustained postsclerotherapy compression may be required for 2–8 weeks or, rarely, longer, with a class II or class III graduated compression garment to be worn while awake. Local compression with padding or foam can be removed as early as the same evening, according to some authors, or several days to weeks later. Currently, there is no general agreement regarding duration or type of compression. I prefer the use of a self-adhesive foam padding manufactured by 3M (Reston self-adhering foam pad) and class II thigh-high graduated compression stockings to be worn for 1 week. Patients should be instructed to walk posttreatment (the recommended length of time currently is not defined). Patients are encouraged to refrain from vigorous activity, as per postoperative sclerotherapy instructions, for treatment of telangiectasias. Follow-up examinations with DUS are recommended at 2 weeks and 6, 12, and 24 months. Thrombus formation, recanalization, persistent reflux, and postsclerotherapy side effects are evaluated and treated, as necessary.

## 8.8 Compression Foam Sclerotherapy

The use of foamed sclerosants in the treatment of varicose veins is not new. Worldwide interest in this technique has shown a recent rebirth in foam sclerotherapy. Extensive work has been carried out in the field of foam sclerotherapy by numerous phlebologists over the past six decades, especially in Europe. The following section summarizes a timetable that describes an overview of the major developments of foam sclerotherapy.

### 8.8.1 The History of Sclerosing Foams

The first recorded use of a foam sclerosant for the treatment of telangiectatic veins was in 1939 by Stuard McAusland. McAusland’s technique consisted of shaking a rubber-capped bottle filled with sodium morrhuate, creating a froth. This froth was then transferred into a syringe and injected into the varicose veins. The treated

areas were observed to immediately turn pink, sometimes retract, and instantly disappear [17]. The next recorded treatment was that of Egmont James Orbach in 1944. Orbach took a different approach that did not include the use of foam. Instead, he used two “conventional liquid” techniques, one known as the “full-vein technique” for smaller veins, where the veins were injected while the patient was standing, and the empty-vein technique for larger veins. This technique required the varicose vein segment to first be isolated with two tourniquets. Then, following venipuncture, the leg was raised approximately 45° to 90°. The release of the proximal tourniquet allowed the blood to flow centrally. The purpose of the distal tourniquet was to reduce or even stop the blood supply to the area being treated. This technique lessened the dilution of the sclerosing liquid agent. Through trial and error, Orbach later discovered that reducing the diameter of the vein and clearing it of blood before injecting the sclerosing agent increased the contact between the sclerosing agent and the endothelium. He then injected small amounts of air into the veins to rid them of any remaining blood. Orbach used this air-blocking technique only on small and medium-sized veins [17]. That same year, Robert Rowden Foote’s sclerotherapy technique was published in London discussing his rendition of the empty-vein technique. He injected the veins with a soapy froth produced by shaking up 1 cc of ethamoline (ethanolamine oleate) in a 2-cc syringe. Foote believed the “feeder” vein should be treated first. In order to be distinguished as a foam, the gas portion must be greater than 0.52, so Foote’s sclerosant was not considered a foam. This technique was geared toward the treatment of smaller and medium-sized veins. Foote’s 1+1 air:sclerosant ratio froth was more a liquid than foam and thus could not be used to displace blood in larger veins. Today, ethanolamine oleate is not manufactured in most countries; consequently, this technique is no longer practiced [17].

In 1949, Karl Sigg embraced an air-block technique similar to that created by Orbach five years earlier. However, Sigg’s technique was to be used on larger as well as smaller veins. Sigg

later combined the air-block technique created by Orbach and the foam technique created by Foote, forming the foam-block technique. He found that the air-block technique was more effective if foam instead of air was injected into the veins because foam has a heightened viscosity and a slower passage rate through the veins than air. Sigg produced his foam by aspirating 1 ml of air into a glass syringe filled with liquid sclerosant with the opening pointed down, thus forming bubbles [17].

One year later, a study conducted by Orbach was published comparing the effectiveness of foam sclerosants with the effectiveness of liquid sclerosants. Orbach used the length of the sclerotherombus, resulting from the injection of a particular sclerosant, to determine the endpoint. He found that the effectiveness of a foam sclerosant formed by agitating the syringe or drug vial was increased 3.5- to 4-fold compared with that of a liquid sclerosant using the same amounts and concentrations of each. Orbach also found that vasospasm was more common and more visible after the use of foam sclerosants because foam can spread throughout venous segments farther than liquids can after vasospasm and are more potent. Orbach’s study proved that the foam sclerosants have a greater efficacy than liquid sclerosants [17].

Three years later, in 1953, Arve Ree introduced the new technique of injecting a “pure” foam sclerosant into the venous system to treat telangiectasias and varicose veins. He agitated a solution of detergent in a vial and aspirated the bubbles into the syringe. Ree’s technique consisted of injecting 2–7 ml of foam sclerosant, corresponding to an amount of air of up to 6.6 ml. The exact measurements varied depending of the diameter of the veins. Using this technique, Ree successfully treated a series of 50 patients [17].

In 1956, Peter Flückiger advocated the technique “retrograde sclerotherapy.” His technique consisted of elevating the leg followed by injection of the foam sclerosant into the saphenous vein proximal to distal so that the sclerosant could reach all insufficient collaterals as well as the saphenous vein via a single injection. Like Foote, Flückiger also used ethanolamine oleate. He found that foam sclerosants yielded much



better results than liquid sclerosants. Flückiger was the first to postulate and discuss the relevant properties of foam. He postulated foam has increased efficacy due to its ability to travel through the venous system further than liquid sclerosants and still maintain its potency. As a result of this increased efficacy, a lesser amount of sclerosant is needed. He determined that the smaller the bubble size, the greater the surface area of sclerosant exposed to the endothelium. He also postulated that the homogeneity of the foam is a very important factor in treatment success. He created a homogenous, fine-bubbled foam by simultaneously aspirating sclerosant and air through a fine-bore needle by submerging only two thirds of the opening of the bevel of the needle into the liquid when aspirating [17].

8 The following year Heinz Mayer and Hans Brücke introduced their double-piston syringe, a device designed specifically for the production of sclerosing foam. The invention of the double-piston syringe is considered a milestone in the ever-changing foam preparation process [17].

In 1962, Flückiger proposed another technique for the preparation of sclerosing foam. This technique involved pumping air and sclerosant forward and backward between a drug vial and the affixed syringe, forming bubbles and foam. His technique was later amended by Alessandro Frullini who added an adapter, making it possible to use disposable syringes. Then in 2001, Frullini added the option of using sterile air to generate the sclerosant [17].

Flückiger later recommended that following injection of a venous segment, a few minutes should be allowed for the foam to degrade before applying compression to avoid propulsion of foam into the deep venous system; this is still recommended today [17].

In 1963, the first sclerotherapy treatment with Aethoxysklerol (polidocanol) was recorded. This treatment was performed by Peter Lunkenheimer, who used 2 ml of the solution, which was not a known sclerosant at the time [17].

In 1969, Walter Gillesberger introduced the “low-pressure technique” based on generation of a negative pressure in a glass syringe, allow-

ing the air to enter through the space between the syringe piston and the plunger and thus forming bubbles. This technique was modified in 1997 by Alain Monfreux who proposed the idea of capping the glass syringe, yielding an “absolute” negative pressure. Then, in 1998, Symon Sadoun and Jean-Patric Benigni modified Monfreux’s technique by making it possible to use plastic syringes instead of glass. Also in 1998, Miguel Santos Gaston adopted and modified Monfreux’s technique. After preparing the foam according to Monfreux, Gaston emptied the foam into a glass container and aspirated the foam again. He repeated this several times, producing a finer and drier foam [17].

In 1984, Gerald Hauer introduced his foam preparation technique. He patented his twin-syringe technique, in which he used a twin-syringe set for preparation. The twin syringe consisted of two parallel syringes, one filled with air, and the other filled with sclerosant. Both syringes were simultaneously emptied into a “mixing chamber,” under pressure, thus forming a 1+1 ratio foam (sclerosant and air) [17].

Two years later, Michael Grigg introduced a new foam preparation technique (also referred to as the Irvine technique). His technique was based on the concept of creating a turbulent flow between two syringes connected by a plastic infusion tube. The liquid sclerosant and air were pumped back and forth, creating bubbles. The Irvine technique, named after the laboratory where it was developed, was later improved by G. Belcaro and coworkers who added small increments of a heavily foaming detergent to prolong the half-life of the foam. Grigg’s technique was a precursor to the Tessari technique and the double-syringe technique, a technical variation of the Tessari technique [17].

In 1995, Juan Cabrera Garrido used high volumes of foam to treat venous malformations and saphenous veins. However, he added a high-speed rotating brush (a modified dental burr) to agitate the foam, and CO<sub>2</sub> as a carrier gas. His objective was to completely fill the venous lumen. Later, however, he reported that the foam could travel from the greater saphenous vein into the deep venous system through the saphenofemoral junction or other connections, thus provoking thrombosis. This tech-

nique does require special safety precautions and is not recommended [17].

In 1999, Javier Garcia Mingo became the first to advocate the use of a device for preparing foam that could be sterilized and used again. This device involved mixing of various gases from a pressure-gas cylinder then passing the mixture through a fine nozzle. This technique is referred to as the “foam medical system.” Handling and cleaning the device is complicated and prevents wide usage [17].

In 2000, Lorenzo Tessari introduced the *tourbillon* technique, or Tessari technique that, along with the technically varied double-syringe system (DSS), is the most commonly used technique to date. Tessari prepared the foam sclerosant using two syringes conjoined by a three-way stopcock. By pumping the liquid sclerosant and air back and forth between the two syringes, bubbles are generated and transformed into foam. The three-way stopcock has an additional advantage of allowing regulation of turbulence, and therefore the size of the bubbles, by turning the stopcock. A narrow passage generates high turbulence and smaller bubbles. This procedure uses 2–2.5 ml of air and 0.5 ml of liquid sclerosant. The concentration of sclerosant varies depending on the diameter of the vessel; generally, 1% Aethoxysklerol for smaller and medium veins and 3% Aethoxysklerol for larger veins. The gas proportion is approximately 0.7–0.83, and the gas bubbles are very fine. The half-life varies with the concentration of the sclerosant and type of syringe (half-life decreases with the presence of silicone in the syringe). Because of the absence of the connecting tube used by Grigg (Irvine technique), much of the silicone is no longer present, resulting in a decrease in the destruction of the foam lamellae [17].

In 2001, Gilles Gachet introduced the “aspiration technique”; this technique was very similar to the 1956 foam preparation technique published by Flückiger [17].

Also in 2001, the DSS, a technical variation of the Tessari technique, was formulated by a group of doctors seeking a quick, sterile, reproducible technique for producing the most stable and fine-bubbled sclerosing foam. Their technique consisted of connecting a 10-ml In-

jekt syringe and a 10-ml Omnifix syringe (each with a Luer-Lock connection), with a Combidyn adapter (to connect the two syringes) and a 0.2- $\mu$ m filter for sterilization of air. After aspirating exactly 8 ml of air into the Omnifix syringe via the sterile filter, the filter is removed. Then, 2 ml of polidocanol 3% is drawn into the same syringe. The two syringes are connected to the Combidyn adapter, and pumping movements are first performed against resistance (five times) by applying thumb pressure on the opposite syringe piston until the two components are well mixed. The foam is then rapidly pumped back and forth between the two syringes seven times without resistance (like the Tessari technique), forming a homogenous foam, with a fixed sclerosant:air ratio of 1:5 (=1+4). The half-life of the foam is approximately 150 s, with an initial mean bubble size of 70  $\mu$ m [17]. Variations in foam stability can occur with divergent syringes, sclerosant concentrations, sclerosant:air ratios, or pumping procedures, making the foam less stable and less viscous.

### 8.8.2 Compression Foam Sclerotherapy

Compression foam sclerotherapy is not only a powerful device in the treatment of varicose veins, but it is also more effective than the use of the original liquid sclerosant [15]. The first prospective randomized study compared foam sclerotherapy using the DSS with conventional fluid sclerotherapy in 88 patients with long saphenous vein insufficiency. A single injection of 2–2.5 ml of foam or 3% polidocanol solution demonstrated a 2-year occlusion rate of 84% in the foam group versus 40% in the fluid group [17]. Although the results of foam sclerotherapy are clearly seen by the untrained eye, the components of the foam are not simplistic. Presently, there is no “foam sclerotherapy school” because the procedure itself is not sufficiently well established. Various techniques of preparation, treatment regimens, indications, etc., exist without a widely accepted “state of the art.” Sclerosing foam is defined as a nonequilibrium dispersion of gas bubbles in a sclerosing solu-

tion where the gas fraction is equal to or greater than 0.52 [liquid-to-gas ratio of 1:5 (1+4)] [15]. The foam is composed of a tensioactive sclerosing agent (usually a detergent sclerosant) and air and is considered more powerful than the original sclerosing solution because of the high concentration of sclerosing agent on the surface of the small air bubbles (micelles). The characterization of the sclerosing foam is dependent upon variables such as the type and concentration of the tensioactive sclerosing agent, type of gas, ratio of liquid to gas, method of preparation, time between processing and use, and bubble size [15, 18]. The characteristics and properties of sclerosing foams account for their action, efficacy, safety, and potency.

## 8

### 8.8.3 Methods for the Preparation of Sclerosing Foam

Using the Monfreux method, the outlet of a glass syringe that contains liquid sclerosing solution is sealed by a rubber or plastic cap. Pulling back the piston generates a negative pressure, which draws air into the syringe through the fine gap between the syringe body and the piston. The end result produces a fluid foam with relatively large bubbles. Monfreux foam properties vary with the concentration of the sclerosant, type of syringe, width of the capillary gap between the body of the syringe and the plunger, and the method and duration of pulling back the piston [17]. Therefore, a defined ratio of gas and sclerosant or defined bubble size cannot be determined with this technique [17]. The DSS, a technical variation of the Tessari technique, utilizes two disposable, latex-free, plastic syringes each with a Luer-Lock connection, a 10-ml Injekt syringe, and a 10-ml Omnifix syringe (with a rubber plunger). The Omnifix syringe is fitted with a 0.2- $\mu\text{m}$  filter for sterilization, and exactly 8 ml of air is drawn into the syringe. The filter is removed and 1 ampoule (2 ml) of polidocanol 3% is drawn into the Omnifix syringe. The two syringes are connected to the Combidyn adapter. Back-and-forth pumping movements are per-

formed five times against resistance by exerting thumb pressure against the piston of one of the syringes. The two components should then be well mixed. The foam is further mixed by quickly pumping back-and-forth seven times without resistance. The sclerosant-to-air ratio is fixed at 1:5 (1+4). The half-life is approximately 150 s, and the initial mean bubble size is 70  $\mu\text{m}$  [17]. The DSS procedure produces a small-bubbled, viscous foam [15] (Figs. 8.8 and 8.9).

The Tessari tourbillon technique utilizes two syringes (various sizes have been described), one containing 0.5 ml of Aethoxysklerol solution and the other containing 2–2.5 ml of air. Various concentrations of sclerosant have been used, but 1% and 3% concentrations are primarily used for large and very large vessels, re-

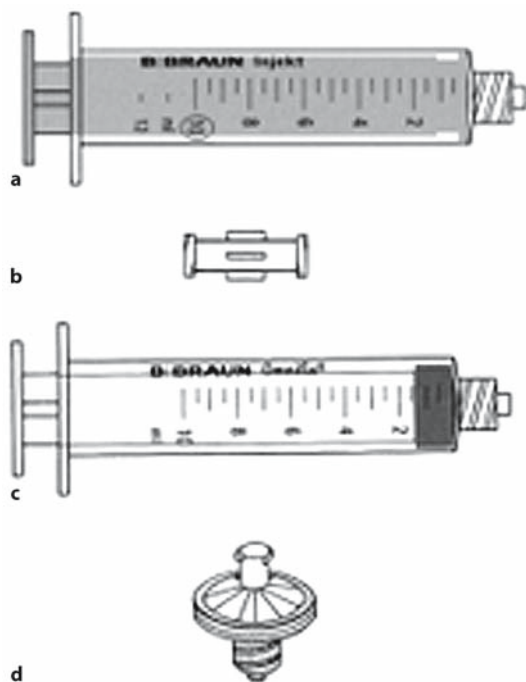

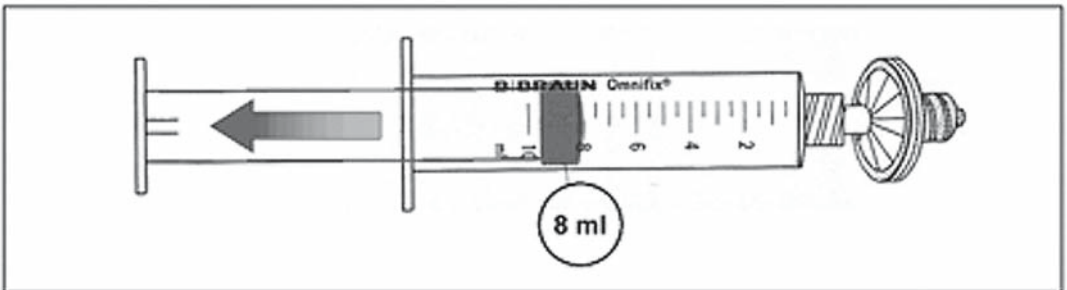


Fig. 8.8a–d. Materials for foam generation. a Injekt syringe with Luer-Lock 10 ml for foam generation, b Combidyn adapter, f/f, for the safe connection of the syringes during foam generation, c Omnifix syringe with Luer-Lock 10 ml, for foam generation, d Sterifix 0.2- $\mu\text{m}$  sterile filter (Personal communication from J-C.G.R. Wollmann M.D.)

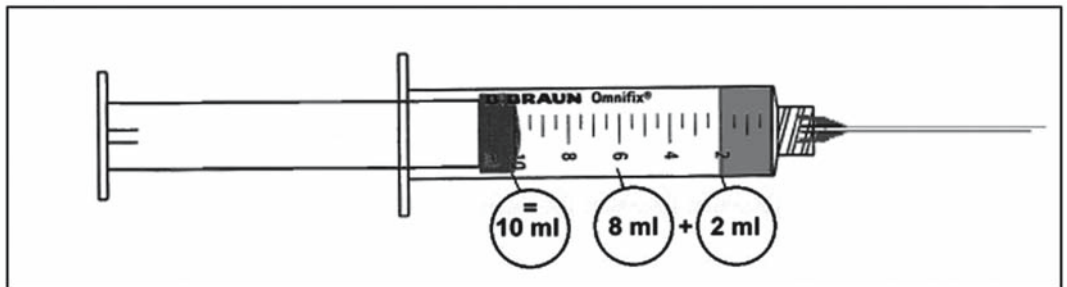
## Step 1A



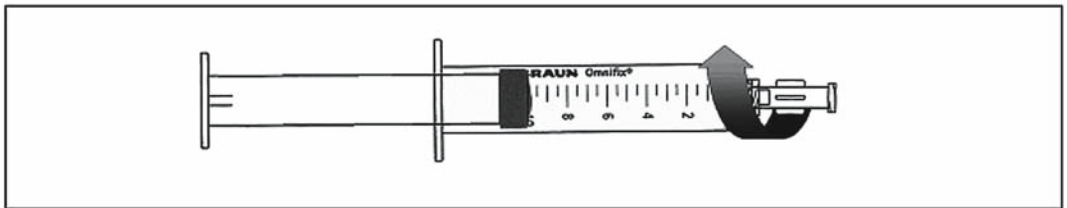
## Step 1B



## Step 1C



## Step 2A



## Step 2B

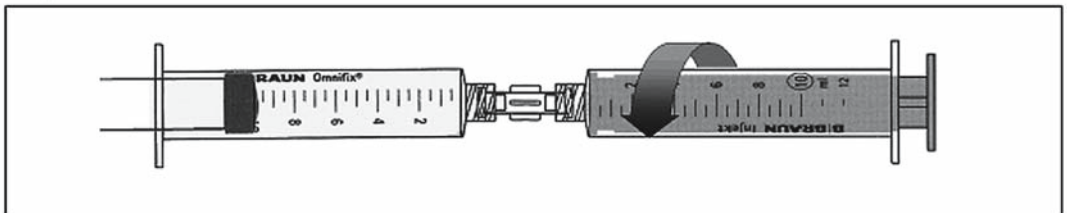
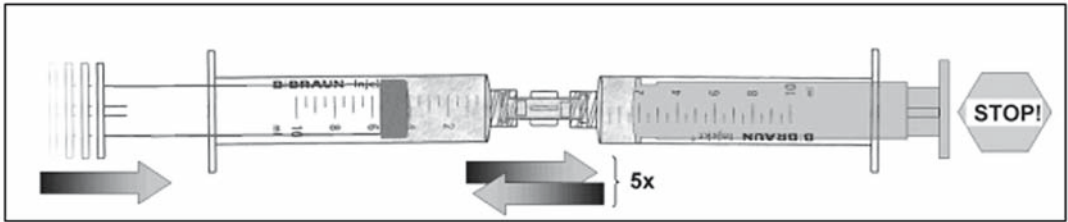
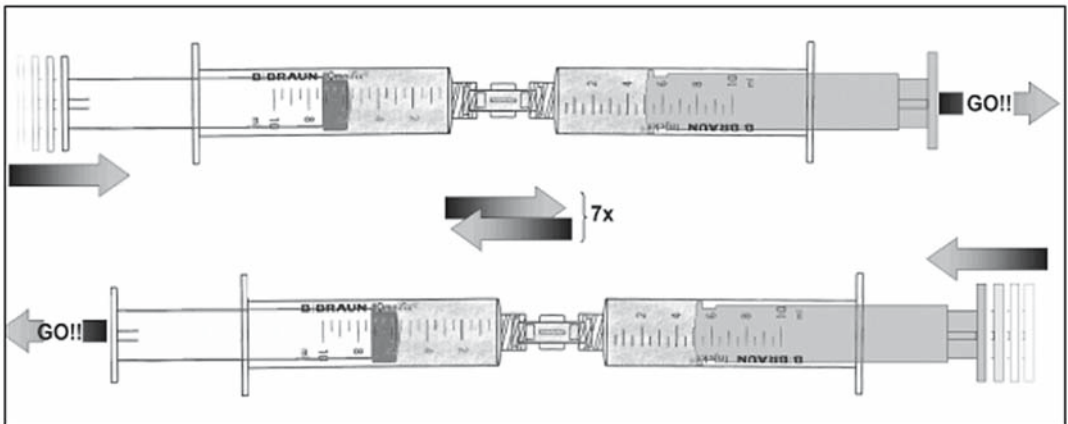


Fig. 8.9.

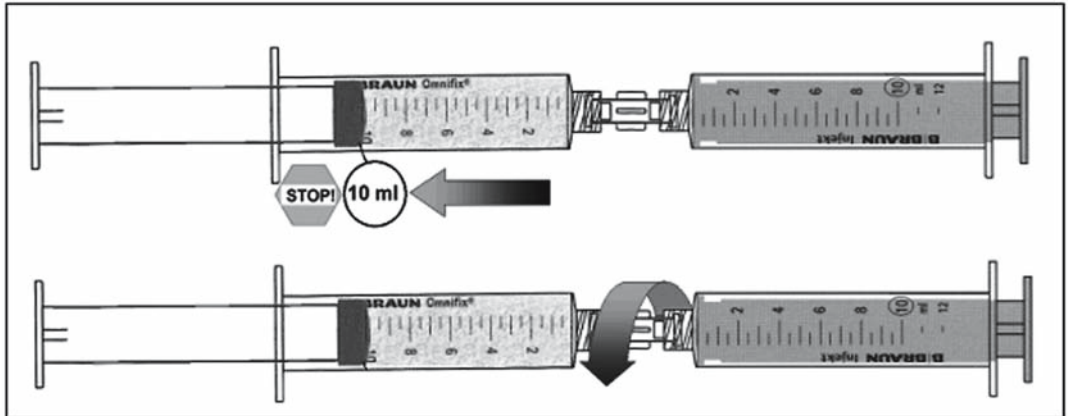
## Step 3



## Step 4



## Step 5



spectively. The outlets of the two syringes are connected to a three-way stopcock. Pumping the contents of the two syringes back and forth 20 times causes a turbulent flow that generates foam [15]. The three-way stopcock can vary the size of the bubbles by changing the size of the passageway. By turning the cock, a narrow passage can generate high turbulence and, conse-

quently, smaller bubbles. Conversely, a wider passage will generate less turbulence and therefore larger bubbles. Regardless of the concentration of the sclerosant, the gas proportion is approximately 0.7–0.83. Tessari's method yields a very fine, small-bubbled foam, which is fluid if low concentrations of sclerosant are used or viscous if high concentrations are used [15, 18,



**Fig. 8.9.** **a** Left: Omnifix syringe; right: (shaded) Injekt syringe. Preparation I: sterile filtration of air. The Sterifix 0.2- $\mu\text{m}$  sterile filter is first screwed onto the three-part, 10-ml Omnifix syringe for sterile filtration of ambient air (*step 1A*), and an exact amount of 8 ml ambient air is drawn up in accordance with the graduation of the syringe barrel (*step 1B*). A hygienically proper procedure is mandatory. Preparation II: drawing up of Aethoxysklerol. Afterward, the Sterifix 0.2- $\mu\text{m}$  sterile filter is removed and 1 ampoule of Aethoxysklerol 3% is drawn up completely (2 ml), as usual, into the same syringe using a sterile disposable cannula (*step 1C*). The inadvertent drawing up of additional sterile air is to be avoided. Preparation III: assembling the dual syringe system. The Combidyn adapter is first firmly connected to the filled Omnifix syringe (*step 2A*) then to the Injekt syringe (*step 2B*) by rotation in order to assemble the dual syringe system. (Personal communication from J-C.G.R. Wollmann M.D.). **b** Left: Omnifix syringe; right: (shaded) Injekt syringe. Foam generation I: mixing phase. The foam generation is performed in two phases: In the first mixing phase, Aethoxysklerol 3% and sterile air are mixed to obtain a dispersion. This is achieved by moving the plunger of the filled Omnifix syringe five times forward and backward with a short, firm, thumb pressure of one hand (*step 3*). The thumb of the other hand holds the plunger of the (shaded) Injekt syringe so

that pumping must be done against a resistance, and the Omnifix plunger returns to its starting position by passive pressure. The (shaded) Injekt syringe is held a bit lower. Foam generation II: homogenization phase. The homogenization phase follows immediately: The plunger of the Omnifix syringe is pressed quickly while the plunger of the (shaded) Injekt syringe is not fixed but can move freely so that no resistance is generated at that time. This forward and backward movement is followed by an opposite backward movement by exerting pressure on the plunger of the (shaded) Injekt syringe in the same manner. A total of seven quick forward and backward movements are performed (*step 4*). The plunger of the Omnifix syringe is drawn back to the 10-ml mark to make sure that no excess pressure remains in the double-syringe system (DSS) (*step 5*). The adapter and the (shaded) Injekt syringe are eventually removed and discarded. The mixing phase and the homogenization phase will take a total of 4–5 s for experienced users. A sterile, very fine, homogenous foam is obtained, which remains stable for a couple of minutes. The procedure ensures a high degree of reproducibility if performed correctly. A common injection cannula is then attached or screwed on to the Omnifix syringe, which now contains 10 ml Aethoxysklerol foam for immediate further use. (Personal communication from J-C.G.R. Wollmann M.D.)

19]. The half-life depends on the concentration and the type of syringe used (silicone content).

### 8.8.4 Indications for Foam Sclerotherapy

According to the 2003 European Consensus Meeting on Foam Sclerotherapy, most participants limit their use of foam sclerotherapy to very large veins and recurrent varicose veins while others limit their use to very small veins. Those who treated small veins were more likely to use the Monfreux method (less viscous foam), and those who treated the larger veins were more likely to use the Tessari method (more viscous foam) [15]. However, regardless of the decided method, it should be noted that veins that are larger in diameter require a more viscous foam and, inversely, veins that are smaller in diameter should be injected with a more liquid foam [15, 18, 19].

### 8.8.5 Body Position

While there are no strict rules regarding the position of the patient during treatment, there were participants who preferred slight leg elevation. Usually, the patient is in a supine position. Leg elevation is felt to allow the foam to reach more distal parts of the vein. Although most participants agreed that elevating the leg helps in the treatment of larger veins, there was no general consensus with regard to the position of the upper body during treatment.

### 8.8.6 Recommended Volume of Sclerosing Foam

There is some lack of agreement regarding the volume of foam that should be injected. However, a general consensus regarding recommended volume of foam and caliber of vessel is represented in Table 8.12

**Table 8.12.** Recommended volume of injection of microfoam sclerosant

Type of vein	Maximum amount per injection site	Maximum amount per session	Technique
C <sub>1</sub> telangiectasia, reticular veins	0.5 ml	4 ml <sup>a</sup> 6–8 ml <sup>a</sup>	Monfreux Tessari
C <sub>2</sub> –C <sub>6</sub> varicose veins	N/A	4 ml <sup>a</sup> 6–8 ml <sup>a</sup>	Monfreux Tessari

<sup>a</sup>3 ml or less for short saphenous veins

### 8.8.7 Injection Variables

Fewer numbers of injections per treatment session are required with compression foam sclerotherapy compared to liquid sclerotherapy [20]. The distance between injection sites can also be increased. One or two injections per session are usually sufficient for large varicose veins [15]. When choosing the optimal location for injecting telangiectatic and reticular veins, most phlebologists found no difference between the injection points for conventional liquid sclerotherapy and foam sclerotherapy. However, the injection points for long saphenous and short saphenous veins with the “open needle” (needle placement without the syringe being connected) and/or “direct puncture” techniques should be at the safest and most accessible location according to the pretreatment duplex examination. The distance to the saphenofemoral junction should be no less than 10 cm [15]. Most sclerotherapists treat varicose veins proximally to distally, starting with the largest veins (with reflux) before treating the smaller veins. After injection of the viscous foam into the vein, the foam column may be directed manually from the point of injection to other areas by repositioning the leg(s) or with manipulation of the duplex probe.

One of the greatest adjuncts for performing successful foam sclerotherapy is the use of DUS during the procedure. The recommended ultrasound frequencies should be between 7.5 and 13 MHz [15].

For the most part, the side effects of compression foam sclerotherapy are similar to

those of liquid sclerotherapy, but some occur slightly more frequently with foam sclerotherapy, particularly migraine headaches in those patients with a history of migraine headaches, and transient visual disturbances in patients with patent foramen ovale [21].

Postsclerotherapy compression is highly recommended to avoid thrombus formation. However, it is suggested that a period of approximately 5 min postinjection should elapse before applying manual compression, to avoid propelling foam into the deep venous system. Follow-up treatment regimens for foam sclerotherapy do not appreciably differ from the general recommendations for liquid sclerotherapy.

As previously stated, foam sclerotherapy is a powerful combatant of varicose veins. In the hands of a specialist, foam sclerotherapy is effective and offers relatively few and mild side effects. Although opinions vary in regard to the details of treatment, general consensus has established certain protocols for foam preparation and treatment regimens.

### 8.9 Complications and Risks

Sclerotherapy is effective and safe in destroying a desired venous segment when performed properly. Sclerotherapy carries a low incidence of complications that are worth mentioning (Tables 8.8, 8.11, and 8.13).

**Table 8.13.** Allergic reactions from sclerosing agents

Sclerosing agents	Reported reactions
Chromated glycerin (Scleremo)	Hypersensitivity Hematuria (with ureteral colic) Ocular manifestations Hypertension Visual disturbances
Ethanolamine oleate (Ethamolin)	Pleural effusion (infiltration) Anaphylactic shock Local inflammatory Coagulation in vitro Renal failure Hemolytic reaction Constitutional symptoms (with aching in the loins and passage of red-brown urine) Pyrexia and substernal chest pain
Hypertonic glucose/saline (Sclerodex)	Allergic reaction to the propylene glycol component in susceptible patients
Hypertonic saline	Hypertension Hematuria (painless)
Polidocanol (Aethoxysclerol)	Anaphylactic shock (very rare) Urticaria Dyspnea Cardiac toxicity
Polyiodinated iodine (Sclerodine, Variglobin)	Tissue necrosis Cutaneous reactions Varicophlebitis Bronchomucosal lesions
Sodium morrhuate	Erythema (with pruritus) Urticaria Gastrointestinal disturbances (abdominal pain and diarrhea) Anaphylaxis Edema Dysrhythmia-cardiac

### 8.9.1 Postsclerotherapy Hyperpigmentation

The incidence of pigmentation postsclerotherapy appears to be related to multiple factors, including (1) type and concentration of scleros-

ing solution, (2) technique, (3) gravitational and other intravascular pressures, (4) tendency toward cutaneous pigmentation, and (5) treatment postsclerotherapy. Three histologic studies on postsclerotherapy pigmentation demonstrated this complication to be caused by hemosiderin only [2]. The incidence of hyperpig-

mentation following sclerotherapy has been reported to occur at a rate of 0.3–10% and up to 30% [2]. Postsclerotherapy hyperpigmentation usually occurs 6–12 weeks after treatment [2]. The general rule is slow regression of the hyperpigmentation with a 1% incidence of pigmentation persisting after 1 year [2]. Georgiev recommends a single “trial” sclerotherapy session with chromated glycerin to select patients at risk of developing postsclerotherapy hyperpigmentation [22]. Those patients who develop hyperpigmentation from intravascular chromated glycerin should be treated with a milder sclerosant, he goes on to say. Duffy and Sadick have not found the addition of 100 U/ml of heparin to sodium tetradecyl sulfate sclerosant (which has the highest incidence of hyperpigmentation) to decrease the incidence of postsclerotherapy hyperpigmentation and may, in fact, promote angiogenesis [2]. Marley reported a decrease in postsclerotherapy hyperpigmentation when injecting veins proximally to distally [2]. Goldman et al. report a decrease in the incidence of postsclerotherapy pigmentation from 40.5% to 28.5% in patients wearing class II (30–40 mmHg) graduated compression stockings [1]. Chatard and Goldman both agree that the incidence of postsclerotherapy hyperpigmentation is not more pronounced in persons of color [2]. Treatment of postsclerotherapy pigmentation is often unsuccessful. Hydroquinone bleaching agents are ineffective in reducing this form of hemosiderin-deposited pigment. I have utilized the Q-switch Nd:YAG laser in selected patients with some improvement.

### 8.9.2 Edema

Edema is most common among patients with treated telangiectasias and varicose veins below the ankles, due to gravitational pressure and diminished perivascular fascia in the area [2]. The extent of edema is also related to the strength of the sclerosant and release of histamine and other mediators that increase endothelial permeability. Edema also occurs when compression is not applied in a graduated manner [2, 6]. Recommendations for prevention of edema include limiting the quantity of sclero-

sant injected to 1 ml per ankle and application of a class II (30–40 mmHg) graduated stocking postinjection to be worn for at least 3 days after the treatment.

### 8.9.3 Telangiectatic Matting

The new appearance of a fine web of erythematous telangiectasias occurring after sclerotherapy or surgical ligation of varicose or telangiectatic veins is referred to as distal angioplasty or, more commonly, telangiectatic matting (TM) [2]. The reported incidence ranges from 5% to 75%, with an overwhelming female predominance. The etiology of matting is unknown but is felt to be related to either neoangiogenesis (a normal reparative process after “wounding” of injection), or dilation of existing subclinical blood vessels by promoting collateral flow through arteriovenous anastomoses [11]. Heparin has been demonstrated to produce angiogenesis in vivo [2]. Ouvry, Davy, and Mantse first described postsclerosis TM and have noticed a decreased incidence of matting when the pressure of injection is minimized and the sclerosant is dispersed not more than 1 cm beyond each injection site [2]. Davis and Duffy reported their findings identifying risk factors among 160 patients who developed TM. Significantly more patients with matting were overweight, on hormone therapy during treatment, had a family history of spider veins, and a longer duration of their spider veins prior to treatment. Additionally, the matting group noted the onset of their veins after excess hormonal states [23]. Age and excessive standing do not appear to play a role in the development of TM [2]. Therefore, any technique that may limit this occurrence should be employed, such as limiting the injection blanch to 1–2 cm, discontinuation of estrogen preparations prior to and during treatment, and avoidance of heparin in the sclerosant. Fortunately, TM usually resolves over a 3- to 12-month period. For the rare permanent TM, use of the newer vascular lasers may provide resolution of this condition.

### 8.9.4 Localized Urticaria

Localized urticaria, or hives, is likely to occur after sclerotherapy with any of the sclerosing solutions. The intensity level of the urticaria is dependent upon the concentration of the solutions used. The severity of the urticaria and the subsequent itching may be decreased if topical steroids are applied to the area immediately following the injection.

### 8.9.5 Tape Compression Blister Formation

This relatively uncommon cutaneous condition may occur when a tape dressing is applied to an area of tissue movement, such as the posterior calf, medial thigh, and popliteal fossae. The blister usually appears as a flaccid fluid-filled sack overlying normal-appearing skin. While these blisters can occur in response to the use of any tape, they occur more often when a 3M Microfoam tape is used. The tension with which this tape is typically applied increases the likelihood of blistering. Other variables that instigate blistering are hot weather conditions and thin and fragile skin.

It is important to take time and explain this reaction to the patient and to distinguish it from sclerotherapy-induced cutaneous necrosis or cutaneous infection. Early cutaneous necrosis may appear as a superficial blister. However, the underlying and adjacent tissue is usually indurated and erythematous. Bullous impetigo can have a similar appearance, but the underlying skin is usually warm and erythematous. The patient might also incorrectly assume that the blisters are an allergic reaction to the sclerosant. Fortunately, adhesive tape blisters resolve without any adverse sequelae within 1–2 weeks. The use of an occlusive hydroactive dressing, such as Duoderm, can aid in healing, prevent infection, and alleviate pain.

### 8.9.6 Tape-Induced Folliculitis

Occlusion of any hairy area can produce folliculitis. Men who are being treated for varicose veins are more prone to tape compression folliculitis. Tape dressings placed over foam or cotton-ball pads or under a graduated compression garment can produce follicular inflammation or infection. Folliculitis is also more likely to occur when sclerotherapy is performed during the summer months, as a result of increased activity and perspiration. Treatment involves topical treatment with an antibiotic gel or solution, such as 2% erythromycin or clindamycin phosphate.

### 8.9.7 Vessel Recurrence

Recurrence of treated vessels has been estimated to occur at a rate of 20% to nearly 100% of treated leg telangiectasias at the 5-year follow-up [2]. The larger the postsclerosis intravascular thrombosis, the greater is the likelihood of recanalization of thrombus [4, 14]. Therefore, the most important factor in preventing recurrence is limiting intravascular thrombosis. Compression decreases the extent of thrombus formation thereby decreasing the risk for recanalization. Three weeks of continuous compression with class II (30–40 mmHg) graduated compression stockings gives the best results, but even 3 days of compression is beneficial [12]. Additionally, the importance of draining postsclerotherapy thrombi has been emphasized by Sigg, Pratt, and Hobbs [2]. Recanalization through a sclerosed telangiectasia is not common; histologic studies have demonstrated only fibrosis [2].

### 8.9.8 Vasovagal Reactions

Vasovagal reflex is a common adverse sequelae of any surgical or invasive procedure. Usual symptoms include lightheadedness, nausea, and sweating. Vasovagal reactions are typically preceded by a painful injection but may occur when the patient sees the needle or smells the



sclerosing solution or alcohol skin prep or is injected while standing. Patients with a history of asthma or coronary artery disease are more susceptible to more serious stress-induced problems. A good medical history preoperatively can prepare the phlebologist for this potential reaction.

### 8.9.9 Cutaneous Necrosis

The incidence of cutaneous necrosis does not discriminate between sclerosing agents. Necrosis can result from extravasation of a sclerosing solution into the perivascular tissue, injection into a dermal arteriole or an arteriole feeding into a telangiectatic or varicose vein, a reactive vasospasm of the vessel, injection of a sclerosant in higher concentrations than required for the treatment vessel diameter or excessive cutaneous pressure created by compression techniques [2, 3, 24]. Due to the degree of possible human error, the injection technique is an important, but not foolproof, factor in avoiding this complication, even under optimal circumstances. Polidocanol appears to be the least toxic sclerosant to subcutaneous tissue (Tables 8.8 and 8.11). However, in sufficient concentrations, it has been reported to cause cutaneous necrosis (concentrations greater than 1%) [2, 25, 26]. Excessive compression of the skin overlying the treated vein may produce tissue anoxia with the development of localized cutaneous ulceration and may ultimately produce tissue ischemia. Therefore, it is recommended that patients not wear a graduated compression stocking of over 30–40 mmHg for long periods of time when the patient is recumbent [2]. Whatever the cause of the ulceration, institution of treatment at the time of occurrence is optimum. Fortunately, most ulcers that occur are small (24-mm diameter), and primary healing usually leaves an acceptable scar. For larger ulcers, hydrocolloid or saline wet-to-dry dressings result in a decreased healing time after proper wound debridement. Excision and closure of these lesions is also recommended, as this affords the patient the fastest healing and an acceptable scar.

### 8.9.10 Allergic Reactions

Because of the possibility of angioedema or bronchospasm, each patient with evidence of an allergic reaction should be examined for stridor and wheezing by auscultating over the neck and chest while the patient breathes normally. Minor reactions like urticaria can be treated with oral antihistamines; however, if stridor is present, an intramuscular injection of diphenhydramine and intravenous corticosteroids should be administered. Bronchospasm is estimated to occur postsclerotherapy in 0.001% of patients [2] and responds to inhaled bronchodilators or IV aminophylline. Four types of potentially serious systemic reactions specific to the type of sclerosing agent used have been noted: anaphylaxis, pulmonary toxicity, cardiac toxicity, and renal toxicity [2]. Anaphylaxis is usually IgE mediated, mast-cell derived, and occurs within minutes of exposure to the offending agent. Clinical manifestations include airway edema, bronchospasm, and vascular collapse. Since the risk of anaphylaxis increases with repeated exposures to the antigen, the phlebologist should always be prepared for this reaction in every patient. Initial signs and symptoms may be subtle and can include anxiety, itching, sneezing, coughing, urticaria and angioedema, wheezing, and vomiting, progressing to vascular collapse and cardiovascular failure. Recommended treatment at the onset of symptoms includes epinephrine 1:1,000 subcutaneously injected (0.2–0.5 ml) repeated three to four times at 5–15-min intervals. Emergency medical services should be immediately sought as well. Rarely has anaphylaxis resulted in fatality. There have been no reports of pleural effusion with injection into varicose veins of the legs.

### 8.9.11 Superficial Thrombophlebitis

Before the advent of modern-day sclerotherapy and the use of postsclerotherapy graduated compression, both superficial and deep thrombophlebitis occurred in a significant number of sclerotherapy patients [2, 11, 12]. Superficial

thrombophlebitis appears 1–4 weeks following sclerotherapy as a tender erythematous induration of the injected vein. Even when appropriate compression is used, thrombosis and perivascular inflammation may occur. Ascending phlebitis in the long saphenous vein or its tributaries can develop at the upper edge of the compression stocking. Creating a gradual transition of pressure from compressed to noncompressed vein(s) may mitigate this development. In addition to appropriate compression, drainage of thrombi after liquefaction of the clot has occurred (in approximately 2 weeks) will hasten resolution. If untreated, the inflammation and clot may spread to perforating veins and the deep venous system, leading to possible valvular damage and pulmonary embolic phenomena. Frequent ambulation and aspirin or other nonsteroidal anti-inflammatory agents may also be helpful.

#### 8.9.12 Arterial Injection

Intraarterial injection of a sclerosant is a very rare complication. The most commonly reported location for intraarterial injection is into the posterior tibial artery in the area of the posterior or medial malleolar regions of the ankle [2]. Immediate pain, cutaneous blanching in an arterial pattern, loss of pulse, and progressive cyanosis usually occur.

Another area where arterial and venous circulation are in close proximity is at the junction of the femoral and long saphenous veins [2, 3]. The external pudendal artery bifurcates and may surround the long saphenous vein just after its connection with the femoral vein. Because of anatomical variations of these collateral arteries, duplex scanning is important before injection of sclerosants in this area.

#### 8.9.13 Pulmonary Embolism/ Deep Venous Thrombosis

The occurrence of pulmonary emboli after sclerotherapy is very rare. Deep vein thrombosis and embolic episodes usually occur 4–28 days after sclerotherapy, and most cases have

been associated with injection of large volumes of sclerosant (12 ml) at a single site. With the use of duplex-guided foam sclerotherapy, the amount and concentration of sclerosing solution is reduced [15, 18]. The sclerosing foam displaces the intravascular blood with very little dilution of the sclerosant, and the active surface of the sclerosant is increased as a result of the preparation of the foam [15]. Sclerosing foam is highly echogenic, and safe intravascular injections can be controlled by an experienced phlebologist using duplex-guided foam sclerotherapy technique. Other techniques that will minimize damage to the deep venous system include leg elevation during the treatment of large varicose veins (impedes penetration into the deep venous system), postsclerotherapy compression of the treated vein with local compression, and a class II graduated compression stocking followed by immediate ambulation and frequent ambulation thereafter to dilute the sclerosant [6].

#### 8.9.14 Nerve Damage

The saphenous and sural nerves may be injected during sclerotherapy due to their close proximity to the long and short saphenous veins. Severe pain, anesthesia, and permanent nerve dysfunction can occur. Paraesthesias, as a result of perivascular inflammation of a sclerosed vein that is adjacent to superficial nerve(s), can also occur. This complication may take 3–6 months to resolve and may be helped with nonsteroidal anti-inflammatory medications and high-potency topical corticosteroids.

### 8.10 Conclusion

The permanent eradication of varicose veins with sclerotherapy continues to evolve as a result of the development of new, and improvement of old techniques. Advantages of sclerotherapy include the lack of anesthesia and avoidance of hospital stay, low morbidity rate, and no “down time” or loss of work. Standardization of treatment guidelines for the practice of sclerotherapy, however, remains elusive. Sev-

Table 8.14. Sclerosing solutions distributors

Sclerosing solutions	Brand names	Distributors
Chromated glycerin	Scleremo	Laboratories E. Bouteille 7, Rue des Belges 87100 Limoges, France Omega Montreal, QC, Canada H3M3A2
Ethanolamine oleate	Ethamolin	Block Drug Company 1 New England Avenue Piscataway, NJ 08855, USA
Hypertonic glucose/saline	Sclerodex	Omega Montreal, QC, Canada H3M3A2
Hypertonic saline 23.4%	N/A	American Regent Laboratories, Inc. Shirley, NY 11967, USA Henry Schein 135 Duryea Road Melville, NY 11747, USA Invenex Gibcol Inevex Division The Dexter Corporation Chagrin Falls, OH 44022, USA Omega Montreal, QC, Canada H3M3A2
Polidocanol	Aethoxysklerol	Kreussler & Co. GmbH Chemische Fabrik Rheingastr. 87 65203 Wiesbaden, Germany Globopharm AQ P.O. Box 1187 8700 Kusnacht, Switzerland Laboratoires Pharmaceutiques DEXO, S.A. 31 Rue D'Arras 92000 Nanterre, France
Polyiodinated iodine	Sclerodine, Variglobin	Sclerodine from: Omega Montreal, QC, Canada H3M3A2 Variglobin from: Globopharm AQ P.O. Box 1187 8700 Kusnacht, Switzerland
Sodium morrhuate	N/A	American Regent Laboratories, Inc. 219 Country Road Tenafly, NJ 07670, USA Palisades Pharmaceuticals, Inc. 219 Country Road Tenafly, NJ 07670, USA
Sodium tetradecyl sulfate	N/A	Eklins-Sinn, Inc. (A subsidiary of A.H. Robins Company) 2 Esterbrook Lane P.O. Box 5483 Cherry Hill, NJ 08034, USAS

eral sclerosing solutions are currently available for the treatment of varicose and telangiectatic vessels (Table 8.14). The “ideal” sclerosant, concentrations, or appropriate volumes have yet to be determined. Compression sclerotherapy for the treatment of varicose veins has been widely used for many years. However, there is still no uniform agreement regarding duration of compression, type of compression, caliber of vessel requiring compression and type or use of adjunctive compression padding. A great deal of variable data exists regarding the duration and effectiveness of compression. Should patients avoid hot showers or baths during the period of postsclerotherapy compression in order to eliminate unwanted vasodilatation? Likewise, parameters for pre- and post-treatment protocols, retreatment and follow-up intervals are presently not established. These are questions that both the practitioner and patient need to have answered.

Introduction of the use of diagnostic tests, such as continuous-wave Doppler ultrasound, DUS, and color-duplex sonography as aids in the treatment of incompetent varicose and perforating veins, have certainly allowed for improvement in diagnosis, treatment technique, outcome, and reduction in postsclerotherapy complications. At the moment, uniform guidelines for the use of diagnostic tests pretreatment, during treatment, and postsclerotherapy have not been established.

Foam sclerotherapy represents a major therapeutic advancement in the treatment of varicose veins, but there is no “foam sclerotherapy school.” Standardized procedures and instrumentation for transforming sclerosing solutions into sclerosing foam, as well as the type and concentration of sclerosing agents used, are currently lacking. The types of vessels treated with foam sclerotherapy range from spider veins only to exclusively large, incompetent varicose veins [15]. The benefit of foam sclerotherapy for smaller vessels and spider veins needs to be further demonstrated in randomized controlled studies.

Standard guidelines for treatment of complications such as perivenous extravasation and ulcer formation, postsclerosis pigmentation and TM (telangiectatic matting) currently do

not exist. There is no controlled data regarding sclerotherapy when performed on patients taking certain medications, in particular, anticoagulants and Antabuse. This, too, should be studied. Clearly, attempts to unify medical opinion and to standardize the practice of sclerotherapy are worthy of ongoing consideration, research and discussion.

## References

1. Goldman MP, Duffy DM, Sadick MD, Weiss RA (1996) Guidelines of care for sclerotherapy treatment of varicose and telangiectatic leg veins. *J Am Acad Dermatol* 34:523–528
2. Goldman MP (1991) Sclerotherapy: Treatment of varicose and telangiectatic leg veins. Mosby, St. Louis, pp 56
3. Green D (1998) Sclerotherapy for permanent eradication of varicose veins: theoretical and practical considerations. *J Am Acad Dermatol* 38:461–475
4. Goldman MP, Weiss R, Bergen J (1994) Diagnosis and treatment of varicose veins: a review. *J Am Acad Dermatol* 31:393–413
5. Fronek HR (1989) Noninvasive examination of the venous system in the leg: presclerotherapy evaluation. *J Dermatol Surg Oncol* 15:170–173
6. Rabe E et al (2004) Guidelines for sclerotherapy of varicose veins. *Dermatol Surg* 30:686–693
7. Kanter A (1998) Clinical determinants of ultrasound-guided sclerotherapy outcome part I: The effects of age, gender, and vein size. *Dermatol Surg* 24:131–135
8. Kanter A (1998) Clinical determinants of ultrasound-guided sclerotherapy part II: In search of the ideal injected volume. *Dermatol Surg* 24:136–140
9. Thibault PK (1995) Duplex examination. *Dermatol Surg* 21:77–82
10. Goldman MP, Bennett RG (1987) Treatment of telangiectasias: A review. *J Am Acad Dermatol* 17:167–182
11. Goldman MP et al (1990) Compression in the treatment of leg telangiectasia: a preliminary report. *J Dermatol Surg Oncol* 16:322–325
12. Weiss RA, Sadick NS, Goldman MP, Weiss MA (1999) Postsclerotherapy compression: controlled comparative study of duration of compression and its effect of clinical outcome. *Dermatol Surg* 25:105–108
13. Scurr JH, Coleridge-Smith P, Cutting P (1985) Varicose Veins: optimum compression following sclerotherapy. *Ann R Coll Surg Engl* 67(2):109–111
14. Tezelaar DJ, Neumann HAM, De Roos KP (1999) Long cotton wool rolls as compression enhancers in macrosclerotherapy for varicose veins. *Dermatol Surg* 25:38–40
15. Breu FX, Guggenbichler S (2004) European consensus meeting of foam sclerotherapy. *Dermatol Surg* 30:709–717

16. Goldman MP et al (1996) Guidelines of care for sclerotherapy treatment of telangiectatic leg veins. *J Am Acad Dermatol* 34: 523–8
17. Wollmann J-CGR (2004) The history of sclerosing foams. *Dermatol Surg* 30: 694–703
18. Frullini A, Cavezzi A (2002) Sclerosing foam in the treatment of varicose veins and telangiectases: history and analysis of safety and complications. *Dermatol Surg* 28: 11–15
19. Tessari L, Cavezzi A, Frullini A (2001) Preliminary experience with a new sclerosing foam in the treatment of varicose veins. *Dermatol Surg* 27: 58–60
20. Yamaki T, Nozaki M, Iwasaka S (2004) Comparative study of duplex-guided foam sclerotherapy and duplex-guided liquid sclerotherapy for the treatment of superficial venous insufficiency. *Dermatol Surg* 30: 718–722
21. Kern P et al (2004) Single-blind randomized study comparing chromated glycerin, polidocanol solution and polidocanol foam for treatment of telangiectatic leg veins. *Dermatol Surg* 30: 367–372
22. Georgiev M (1993) Postsclerotherapy hyperpigmentations. *J Dermatol Surg Oncol* 19: 649–652
23. Davis LT, Duffy DM (1990) Determination of incidence and risk factors for postsclerotherapy telangiectatic matting of the lower extremity: A retrospective analysis. *J Dermatol Surg Oncol* 16: 327–330
24. Bergon JJ, Weiss RA, Goldman MP (2000) Extensive tissue necrosis following high concentration sclerotherapy for varicose veins. *Dermatol Surg* 26: 535–542
25. Sadick NS (1994) Hyperosmolar versus detergent sclerosing agents in sclerotherapy. *J Dermatol Surg Oncol* 20: 313–316
26. Sadick NS (1990) Treatment of varicose and telangiectatic leg veins with hypertonic saline: a comparative study of heparin and saline. *J Dermatol Surg Oncol* 16: 24–28



# Subject Index

## A

abdominoplasty 97  
abnormal veins, classification 133  
acellular allogeneic dermis 98  
acetyl hexapeptide-3 25  
acromegaly 9  
ACTH (adrenocorticotrophic hormone) 2  
actinic  
– damage 71  
– lentiginos 39  
adapalene 46  
adrenocorticotrophic hormone (ACTH) 2  
adrenopause 4, 5  
aethoxysklerol 152, 153  
African American skin 36  
aging  
– genetic factors 31  
– intrinsic aging 33  
– of the skin 2, 4  
AHA (alpha-hydroxy acid) 23, 58  
air plethysmography 149  
alpha-hydroxy acid (AHA) 23  
aluminium oxide crystal particle 76  
anaphylaxis 162  
andropause 5  
angiogenesis 160  
anti-aging medicine 2  
antioxidant 3, 19, 44  
– nutrients 10  
apoptosis 2  
argirelene 26  
argon laser 111  
arteriovenous anastomosis 160  
ascorbic acid 3, 21, 45  
ascorbyl palmitate 20  
Asian skin 34  
*Aspergillus* 58  
atrophic  
– acne scars 116, 121  
– scar 71, 113  
atrophy 42  
autologous  
– filler 98  
– implant 97  
– injection 97

## B

bacterial infection 118  
Baker-Gordon  
– peel 67  
– phenol formula 73  
– solution 74  
baker's yeast 25  
beta-glucan 24  
beta-hydroxy acid (BHA) 24, 61  
blister 161  
blue peel 65, 67  
Botox 89  
– Cosmetic 88, 90  
– Medical 88  
botulinum toxin 83–91  
– adverse effects 91  
– anatomic considerations 87  
– medical applications 85  
– outcome 91  
bovine collagen 100, 102  
Boyd's perforating vein 131  
breast  
– lift 97  
– reduction 97  
Brodie-Trendelenburg test 135, 136  
bronchospasm 162

## C

calcium hydroxylapatite 104  
carbohydrate food 14  
carbon dioxide (CO<sub>2</sub>) laser 111, 117  
cardiovascular system 128  
carotene 12  
– α-carotene 12  
– β-carotene 12  
carotenodermia 13  
carotenoid (see also carotene) 12, 22  
Caucasian skin 37  
cell senescence 31  
chemexfoliation 53–80  
chemical peeling 48, 54  
– adverse effects 59  
– classification 55

– deep chemical peel 72  
– glycolic acid 60  
– indications 55  
– patient's skin type 59  
– treatment 57  
chemical resurfacing 54  
chemoexfoliant 73  
chromophore 112  
citric acid 23  
*Clostridium botulinum* 84  
Cockett's perforating vein 131  
coenzyme Q10 (CoQ10) 21  
cold ablation 122  
collagen 42, 95, 96, 99  
– animal-based 100  
– bovine 100, 102  
– injectable  
color-duplex sonography 165  
comedonal acne 64  
communicating vein 131  
compression  
– foam sclerotherapy 153  
– stockings 148  
continuous wave (CW)  
– Doppler ultrasound 165  
– laser 112  
copper 25  
Cordran tape 75  
corundum crystals 76  
cosmetic denervation 88  
cosmolecular 19  
cough test 134  
croton oil 73  
cryogen 123  
– spray 122  
cryotherapy 47  
β-cryptoxanthin 12  
cultured human fibroblast 97  
cutaneous  
– infection 161  
– necrosis 161, 162  
cytokines 43

## D

deep  
– chemical peel 72  
– – adverse effects 75

- vein thrombosis 137
- venous insufficiency 138
- venous system 128, 129
- venous thrombosis 134, 138
- dermabrasion 77
- dermatochalasis 113
- dermatosis papulosa nigra (DPN) 36, 39
- diet 3, 4
- dietary reference intake (DRI) 10
- dimethylsiloxanes 105
- discrete hyperpigmentation 39, 40
- DNA helicase 31
- double-syringe system (DSS) 153
- dual porosity expanded polytetrafluoroethylene 107
- duplex
  - ultrasound examination 137
  - venous scanning 138
- dyschromia 68
- dyspigmentation 38
- Dysport 88

**E**

- edema 63, 160
- elastin 42
- elastosis 43
- endocrine system 4
- energy density 112
- epidermal
  - atrophy 41
  - exfoliation 65, 67
  - growth factor receptor (EGF-R) 44
- epigallocatechin-3-gallate (EGCG) 21
- epinephrine 162
- erbium-yttrium-aluminium-garnet (Er-YAG) laser 114, 117
- erythema 117
- erythropoietic photoporphyria 13
- estimated average requirement (EAR) 10
- estrogen 4, 5
- ethanolamine oleate 151
- ethnic skin consideration 72
- expanded polytetrafluoroethylene 107

**F**

- facelift 97
- fat
  - compartment 7
  - hypertrophy 6
  - transfer 97

- fat autograft muscle injection (FAMI) 96, 97
- femoral vein 129, 150
- Fitzpatrick's classification 56
- flat wart 75
- 5-fluorouracil (5-FU) 60, 61, 64
- foam
  - sclerosant 151
  - sclerotherapy 158, 165
- follicle stimulating hormone (FSH) 2
- folliculitis 161
- free radical 32
- frosting 69

**G**

- gastrocnemius vein 138
- genistein 44
- GH (growth hormone) 2, 6
  - secretagogue 8
  - therapy 9
  - - side effects 9
- GHD (growth hormone deficiency) 6
  - syndrome 7
- glabellar folds 86
- Glogau's classification 56, 57, 67
- glutaraldehyde 103
- glutathione (GSH) 3
  - peroxidase 13
- glycemic index (GI) 14
- glycolic acid 60, 61, 68, 69, 79
- good manufacturing practice (GMP) 78
- Gore-Tex implant 107
- grapeseed polyphenol 22
- green tea polyphenol 21
- growth factor 43
- growth hormone (GH) 2, 6
  - deficiency (GHD) 6
  - releasing hormone (GHRH) 6
  - releasing peptides (GHRPs) 8

**H**

- hemagglutinin 84
- hemoglobin 118
- hemostasis 115
- herpes simplex infection 70, 73, 118
- human fibroblast cell 102
- Hunterian/Dodd's perforating vein 131
- hyaluronic
  - acid 97, 103
  - viscoelastic gel 103
- hydroquinone 47, 57, 58, 60, 68

- 4-hydroxyanisole 47
- hyperglycemia 9
- hyperhidrosis 84
- hyperkeratotic skin disorders 64
- hyperkinetic muscles 83
- hypermelanosis 30
- hyperpigmentation 5, 34, 36, 46, 63, 117, 160
  - discrete 39, 40
  - mottled 39, 40
- hypertrophic scarring 59, 70, 75
- hypomelanosis 30, 36, 41
- hyposomatomedinemia 7

**I**

- idebenone 21
- IGF-1 8, 9
- implant 106
- inflammatory acne 64
- injectable
  - autologous collagen 96
  - fillers 96
  - - cadaver-derived 96
- insulin 14
  - tolerance test (ITT) 7
- intense pulse light (IPL) 48
  - source 118
- intrinsic aging 33
- isotretinoin 12, 23, 77
- ITT (insulin tolerance test) 7

**J**

- Jessner's peel 64
- JNK phosphorylation 45

**K**

- keratinocytes 42
- keratokoagulation 69
- Kligman's formula 58
- kojic acid 58

**L**

- lactic acid 23, 68
- laser
  - argon 111
  - chromophore 112
  - CO<sub>2</sub> 111
  - continuous wave (CW) 112
  - energy density 112
  - pulse duration 112
  - skin resurfacing 111-124
    - - adverse effects 117

- therapy 47
- wavelength 112
- leptin 6
- LH (luteinizing hormone) 2
- lidocaine 74
- light-reflection rheography (LRR) 149
- lipoatrophy 95, 97
- lipoic acid 21
- liquid
  - nitrogen 47
  - sclerotherapy 158
- low-density lipoprotein cholesterol (LDL-C) 10
- Luer-Lock connection 153, 154
- luteinizing hormone (LH) 2
- lyophilized human particulate fascia lata 98

## M

- MAP (mitogen-activated protein) kinase 32
  - pathway 44
- matrix-metalloproteinase-1 (MMP-1) 18
- Matrixyl 26
- medium-depth peel 66
  - adverse effects 70
  - outcome 71
- melanin 36, 118
- melanocytes 33, 42, 43
- melanophages 42
- melanosomes 39
- melasma 47, 54, 64
- menopause 5
- micelle 154
- microdermabrasion 48, 76
  - adverse effects 78
- microfoam
  - sclerosant 158
  - tape 161
- microimplants 106
- midinfrared laser 119
- mitogen-activated protein (MAP) kinase 32
- MMP-1 (matrix metalloproteinase-1) 18
- Monfreux method 154, 157
- mottled hyperpigmentation 39, 40
- Myobloc 88, 89, 91

## N

- N-acetyl cystein (NAC) 44
- natural
  - fats 4

- moisturizing factor (NMF) 18
- Nd:YAG 532 laser 48
- neocollagenesis 113, 122
- nerve damage 163
- neuromuscular junction (NMJ) 84
- neuropeptide Y (NPY) 6
- niacinamide 23
- nicotinamide 23
- nonablative
  - laser skin resurfacing 118
  - radiofrequency 122
- nutrition 3, 4

## O

- Omnifix syringe 153, 154, 157
- open needle 158
- oxidation 3

## P

- palmitoyl pentapeptide 25
- panthenol 23
- paraesthesia 163
- PDGF (platelet-derived growth factor) 26
- Penicillium* 58
- peptide 25
- percussion test 135
- perforating vein 131
- permanent filler 105
- Perthes' test 135
- phenol 73
  - peeling 67
- phenyl-butyl nitron (PBN) 19
- phlebitis 148
- photoaging 29-49
- photodamage 30, 41, 79
- photoplethysmography (PPR) 149
- photoprotection 20
- phytoestrogen 4
- pigmentary
  - changes 29-49, 59
  - dyschromia 71
- pigmented seborrheic keratoses 34
- pink sign 67
- pituitary lesion 7
- platelet-derived growth factor (PDGF) 26
- polidocanol 152, 162
- polyhydroxy acid (PHA) 24
- poly-L-lactic acid (PLA) 97, 103
- polymethylmethacrylate (PMMA) microsphere 104
- polyphenol 21

- grapeseed 22
- green tea 21
- polytetrafluoroethylene (PTFE) 107
  - expanded (ePTFE) 107
- polyunsaturated fatty acid 11
- popliteal vein 129, 137
- postinflammatory hyperpigmentation (PIH) 54
- postpeel
  - hypopigmentation 70
  - management 69
- postsclerosis hyperpigmentation 147
- postsclerotherapy 159, 162
  - compression 150
- prepeel rejuvenation 58
- procyanidin 22
- progeria 31
- prolactin 6
- prostate-specific antigen (PSA) 5
- provitamin B<sub>5</sub> 23
- Pseudomonas aeruginosa* 75
- pulmonary emboli 163
- pulse duration 112
- pulsed dye laser 118
- pyruvic acid 67

## Q

- Q-switched laser 48

## R

- recommended dietary allowance (RDA) 10
- residual thermal necrosis 113
- Restylane 94
- retinoic
  - acid receptor (RAR) 23
  - X receptor (RXR) 23
- retinoid 45
  - acid 68
- retinol 23
- retinyl palmitate 23
- retrograde sclerotherapy 151

## S

- Saccharomyces cerevisiae* 24
- salicylic acid 60-62
- saphenous vein 128, 137
  - accessory 130
- scarring 118
- Schwartz test 135
- sclerosing
  - agent 146

- - tensioactive 154
  - foam 150
  - sclerosis 136
  - sclerotherapy 127-164
    - allergic reactions 159, 162
    - compression foam 153
    - foam sclerotherapy 158
    - indications 132
    - intraarterial injection 163
    - liquid sclerotherapy 158
    - nerve damage 163
    - sclerosing agents 146
    - telangiectasia 143
    - ultrasound-guided 149
    - varicose veins 148
  - Sculptra 95
  - seborrheic keratosis 35
  - selenium 13, 22
  - selenomethionine 22
  - selenosis 14
  - semipermanent filler 104
  - septisol 73
  - silicone oil 97, 106
    - viscosity 105
  - skin
    - aging 2, 4
    - color 42
    - polishing 77
    - respiratory factor (SRF) 24
    - type 56
    - - Fitzpatrick's classification 56
    - - Glogau's classification 56, 57
  - SNAP-25 protein 84
  - sodium tetradecyl sulfate (STS) 149
  - soft tissue augmentation 93-108
  - solar lentigines 34, 36, 39, 40, 44
  - solid carbon dioxide 66
  - somatopause 4, 6
  - somatostatin 6
  - soy protein 4
  - spin traps 19
  - spot peel 72
  - Staphylococcus* 75
  - stratum
    - corneum (SC) 18, 41
    - granulosum 42
    - lucidum 41, 42
  - Streptococcus* 75, 103
  - striated muscle relaxation 84
  - sun exposure 35, 70
  - superficial
    - skin resurfacing 53-80
    - varicose vein 134
    - venous insufficiency 138
    - venous system 129
  - superoxide dismutase 25
- T**
- tartaric acid 23
  - tazarotene 46
  - TCA (trichloroacetic acid) 48, 65, 66
  - telangiectasia 140
  - telangiectatic
    - matting (TM) 147, 160
    - vein 128
  - telomerase 32
  - telomeres 2, 31, 32
  - temporary fillers 100
  - tensioactive sclerosing agent 154
  - Tessari technique 153, 157
  - testosterone supplementation 5
  - thrombophlebitis 162
  - tissue
    - anoxia 162
    - respiratory factor (TRF) 24
  - tocopherol 19
    - $\alpha$ -tocopherol 11, 45
    - - acetate 20
  - total body peel 69
  - transepidermal moisture loss (TEWL) 18
  - tretinoin 23, 46, 47, 60
  - trichloroacetic acid (TCA) 48, 65, 66
  - twin syringe 152
- U**
- upper
    - facial muscles 87
    - intake level (UL) 10
  - urticaria 161
  - UV damage 32
  - UVA/UVB radiation 36
- V**
- Valsalva maneuver 137
  - varicose vein 128, 140, 148, 160
    - development 133
  - varicosity 134
  - vasovagal reflex 161
  - venipuncture 151
  - venous
    - claudication 134
    - Doppler ultrasound 136
    - system 128
    - - of the lower leg 128
    - valvular system 131
  - vessel recurrence 161
  - vitamin
    - A 3, 12
    - - retinoid 22
    - C 10-12, 20, 45
    - E 11, 19
- W**
- Werner's syndrome 31
  - Wood's lamp 65