



AYURVEDIC MANAGEMENT OF RETAINED PRODUCT OF CONCEPTION: A CASE REPORT

Sonam jangid¹, Sonu², Hetal H. Dave³, Vipin Kumar⁴

1. PG Scholar, 2nd Year, Department of Prasuti Tantra Evam Stri Roga, National Institute of Ayurveda, DU, Jaipur-302002
2. Assistant Professor, Department of Prasuti Tantra Evam Stri Roga, National Institute of Ayurveda, DU, Jaipur-302002
3. Associate Professor, Department of Prasuti Tantra Evam Stri Roga, National Institute of Ayurveda, DU, Jaipur-302002
4. Assistant Professor, Department of Panchkarma, National Institute of Ayurveda, DU, Jaipur-302002

Corresponding Author: drsonamjangidnia@gmail.com

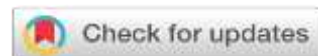
<https://doi.org/10.46607/iamj3711022023>

(Published Online: February 2023)

Open Access

© International Ayurvedic Medical Journal, India 2023

Article Received: 08/01/2023 - Peer Reviewed: 22/01/2023 - Accepted for Publication: 29/01/2023.



ABSTRACT

Introduction: Retained products of conception (RPOC) is defined as the retention of trophoblastic tissue inside the uterine cavity that persists after medical and surgical pregnancy termination, miscarriage, and vaginal and caesarean delivery. In Ayurveda, it can be correlated with *Garbha-Srava*(RPOC). The expulsion of the foetus up to the fourth month of pregnancy is termed *garbha-srava*¹. In this case study, Ayurvedic management successfully treated the RPOC. **Main clinical finding:** A married Hindu female patient of age 25 years, visited Prasutitantra and Striroga OPD at NIA, Jaipur on 29/9/21 with complain of continuous bleeding per vagina with foul smell and itching in the vulval region for the last 2 months. So, UPT was done, and it was found weakly positive. She had also associated complaints of numbness in her lower extremities for the last 2 months. **Diagnosis:** Ultrasonographic report reveal a Heterogenous mass occupying the endometrial cavity. Intracavity fibroid?? Retained product of conception. **Interventions:** The treatment given was *Nagkeshar churna* and *Chandraprabha Vati* and for vaginal wash, *Triphala Churna* and *Sphatik bhasma* were used. **Outcome:** She got relief from the Retained product of conception after taking 2 months of oral Ayurvedic treatment. **Conclusion:** After taking Ayurvedic

treatment for 2 months she got relief from RPOC, and bleeding p/v stopped. So, an Ayurvedic regimen is effective in this type of RPOC case as it prevented surgery. Surgery may lead to intrauterine adhesions and Asherman's syndrome – clinically manifested by menstrual abnormalities, infertility, and recurrent pregnancy loss.

Keywords: Retained products of conception (RPOC), *Garbha-Srava*, *Nagkeshar churna*, *Chandraprabha Vati*, *Triphala Churna*, Asherman's syndrome.

INTRODUCTION

Retained product of conception refers to the persistence of placental and/or foetal tissue in the uterus following delivery, termination of pregnancy, or a miscarriage. RPOC was present in after a third-trimester delivery in around 2.7% of women, whereas it was diagnosed in pregnancies ending during the second and first trimesters in 40% and 17% respectively.² It occurs with greater frequency in medical termination of pregnancy, second-trimester miscarriage, and placenta accreta. Common symptoms include vaginal bleeding and abdominal or pelvic pain, similar to patients with the gestational trophoblastic disease. Some patients may have a fever. Ultrasound is typically the first -line investigation of a suspected retained product of conception. USG may reveal a variable amount of echogenic or heterogenous material within the endometrial cavity, in some instances, this may present like an endometrial or intrauterine mass, presence of vascularity within the echogenic material supports the diagnosis but the absence of colour doppler flow has a low negative predictive value because retained products of conception may be avascular, or calcification may be present. Retained products of conception can be suspected on ultrasound if the endometrial thickness is >10 mm following dilatation and curettage or spontaneous abortion (80% sensitive). Three vascularity patterns have been established on Doppler ultrasound -Type 1: minimal endometrial vascularity less than the myometrium-Type 2: moderate vascularity with nearly equal endometrial and myometrial vascularity-Type 3: marked endometrial vascularity more than adjacent

myometrium, arterial flow velocities >100 cm/sec can occur with low-resistance spectral waveform and large vessels present, potentially mimicking a uterine arteriovenous malformation. In *Ayurveda*, the expulsion of the foetus up to the fourth month of pregnancy is *Garbha-srava* as the conception products are in liquid form, after the fifth and sixth months it is *Garbha-pata* as conception products have attained stability and have become solid³. According to *Acharya Bhela* the expulsion of *Ama Garbha* is due to *Garbha vyaapti* i.e., due to disorders of the foetus⁴. As *Acharya Bhoja* described the period of *Garbha-srava* is up to three months as the complete formation of the placenta, amniotic membrane, and its fluids, the expulsion of the product of conception occurs in pieces while after this period due to the complete formation of the amniotic bag, the mechanism of abortion resembles miniature labour.⁵ In this case, reporting the clinical condition of the patient can be better correlated to *Ama Garbha Shesh (Garbha-Srava)*.

CASE REPORT: A married Hindu female patient of age 25 years, visited Prasutitantra and Stiroga OPD at NIA, Jaipur complaining of continuous bleeding per vagina with a foul smell and itching in the vulval region for the last 2 months. So, UPT was done, and it was found weakly positive, and she had also associated complaints of numbness in her lower extremities for the last 2 months.

Menstrual History-Patient attained her menarche at 14 years of age.

LMP- 3 months back?

M/H- 5 days/30 days

Pattern	Regular
Pain	Painful +++
Clots	Present
Flow	Moderate
Colour	Dark Red
Pad History	D1-D2=2-3 pad/day

	D3-D4=2 Pads/day D5=1Pads/day
Smell	Normal

Obstetric history: G2P1L1A0

G1: Full-term normal delivery, a Male child, 1.5 years back.

Contraception history: NIL

Past Medical History: NIL

Past surgical history: NIL

Personal History:

- Diet - Vegetarian

- Appetite - Decreased
- Sleep – Sound
- Bowel – Constipated
- Bladder: Clear
- Allergy History – None
- Addiction - One cup of tea twice a day.

Examinations-

Physical examination:

G.C	Fair
Built	Moderate
Weight	50kg
Height	5feet 2 inch
BMI	20.3
BP	120/80mm Hg
Pulse Rate	86/min
Pallor	Absent
Pedal Oedema	Absent

Systemic Examination:

Respiratory System	Inspection: B/L symmetrical chest Auscultation: AEBE
Central Nervous System	Orientation: The patient was conscious and well oriented
Cardiovascular System	Auscultation: Normal Heart Sounds

Diagnostic Assessment: -

Laboratory Investigations:

(10-11-2021)

HIV I and II	Non-reactive	HB	9.8g/dl
HBSAG	Non-reactive	Platelet count	298*10 ³ / μL
Bleeding time	3min 03 sec	HCT	30.1%
Clotting time	6min 14 sec	Lymphocytes	48.5%
Prothrombin time	14.2 sec		
INR	1.05		

USG: (29-9-2021)

A heterogenous mass of 50*20mm with blood supply from the posterior wall is seen occupying the endometrial cavity. Intracavity fibroid?? Retained product of conception. Thickened endometrium (ET: 25mm).

USG: (29-10-2021)

Retained product of conception. mixed echogenic area of 25*23mm is seen in the upper uterine cavity with mild internal vascularity on colour doppler.

USG: (18-11-2021)

Normal ultrasonic examination of uterus and adnexa.

Normal ET:6mm.

Treatment Protocol: -

She came in NIA OPD on 29-9-2021 & oral Ayurvedic formulation; *Ojaswani Churna* (3gm twice daily in the morning and evening with milk, before food) was given for the maintenance of pregnancy i.e., for *Garbhasthapana*. As UPT was weakly positive. After that ultrasonography was advised for foetal well-being but the result was RPOC in USG. So, further treatment for RPOC was given.

The following treatment was given to the patient:

S.No.	Medicine (23/10/21)	Dose	Time	Anupana
1.	Nagkeshar churna -2gm	3.5gm BD	Before meal	Lukewarm water
2.	Tab Chandraprabha vati	2-tab BD	After meal	water
S.No.	Medicine	Procedure		
1.	Triphala churna-5gm + Sphatik bhasma-1gm	Yoni Prakshalan		

DISCUSSION

As in *Garbha-srava*, the fetus has an association of *Ama* and bleeding starts, so for stopping the bleeding and retaining the fetus, *stambhana Chikitsa* is prescribed i.e., *Sita*, *mridu*, and *Madhura* drugs are used.⁶

Nagkeshar churna- Bleeding disorders occur due to an imbalance in *Pitta Dosha*. Nagkeshar has some effects on the management of bleeding disorders. As it may help in decreasing inflammation, reducing pain, and arresting bleeding. Nagkesar drug has predominance of *Kashaya Rasa*, less *Tikta Rasa*, *Laghu*, *Ruksha Guna*; *Ushna Virya*; *Katu Vipaka* and *Kapha Pitta Prashamana* action. *Acharya Charak* mentioned Nagkesar in *Raktarsha*.

Chandraprabha Vati – In Ayurveda, Chandraprabha Vati has *Rasayana* (rejuvenator), *Balya* (strengthen), and *Vrushya* (aphrodisiac) properties which revenue the property of stabilizing tissues and preventing cell damage.⁷ The antioxidant properties also stabilize tissues and lead to prevent cell damage.

CONCLUSION

- Patient was administered the treatment for 2 months.
- USG was again done on 18/11/2021 and it was the normal ultrasonic examination of the uterus and adnexa.

REFERENCES

1. Sushruta, Sushruta Samhita with Nibandha Samgraha Commentary of Shri Dalhanacharya edited by Vaidya Jadav ji Trikam Acharya, Nidan Sthana 8/10, Chaukhamba Subharati Prakashan, Edition 2018.
2. Radswiki, T., Baba, Y. Retained products of conception. Reference article, Radiopaedia.org. (Accessed on 14 May 2022) <https://doi.org/10.53347/rID-12524>
3. Sushruta, Sushruta Samhita with Nibandha Samgraha Commentary of Shri Dalhanacharya edited by Vaidya Jadav ji Trikam Acharya, Śārira Sthana 2/18, Chaukhamba Subharati Prakashan, Edition 2018.
4. Premvati tewari, Ayurvediya Prasutitantra evam Striroga part1, prasuti tantra, second edition:1999, page no. 320.
5. Premvati tewari, Ayurvediya Prasutitantra evam Striroga part1, prasuti tantra, second edition:1999, page no. 321.
6. Agnivesh, Charaka Samhita with Vidhyotini Hindi Commentary of Kaasinath Paandey, Chikitsa Sharir cakrapaani tika 30/209, Chaukamba Bharati Prakashan, Edition 2019.
7. Sharma, P.V. (1956). Dravya Guna Vignana (Sanskrit). The Chawkhamba Vidya Bhavan, Benaras, India.

Source of Support: Nil

Conflict of Interest: None Declared

How to cite this URL: Sonam jangid et al: Ayurvedic Management of Retained Product of Conception: A Case Report. International Ayurvedic Medical Journal {online} 2023 {cited February 2023} Available from: http://www.iamj.in/posts/images/upload/440_443.pdf