

## CRITICAL REVIEW OF PHANA MARMA WITH SPECIAL REFERENCE TO ANOSMIA

**Channamallikarjun A Davergaon**

Professor, Dpartment of Rachana Sharir, G J Patel Ayurveda College, New V V Nagar, ANAND 388121, Gujarat, India

**Email:** [mdavergaon@gmail.com](mailto:mdavergaon@gmail.com)

### ABSTRACT

*Marma Sharira* is an ancient traumatological anatomy presented by both *Sushruta* and *Vagabhata*. Though the presentations are grossly similar, whereas *Charaka* given *Trimarma*. *Phana Marma* is considered as *Vaikalyakara Marma*, injury to this area leads to loss of sense of smell, which is located in head region plays a important role in clinical aspect during the head injuries, the head injuries are considered serious part due to the brain involvement, where in most of the head injury occurs during the road accidents, person dies or gets the serious deformities. Here in *Phana Marma* the underlying structures like olfactory nerve, olfactory bulb which helps for sense of smell if injury to these structures leads to *gandha agnan* (loss of sense of smell). Anosmia is the inability to perceive odor or a lack of functioning olfaction—the loss of the sense of smell. Anosmia may be a temporary issue, but some forms such as from an accident, can be permanent. Anosmia is due to a number of factors, including an inflammation of the nasal mucosa, blockage of nasal passages or a destruction of one temporal lobe. Inflammation is due to chronic mucosa changes in the para nasal sinus lining and the middle and superior turbinates. In *Ayurveda* also head region is considered the *Uthamanga* compare to other body part. We need the detail anatomical structures of *Phana Marma* to diagnose and treat the diseases especially in surgical aspect. In our routine work specially in driving the vehicles, in sport injuries we can prevent from head injuries.

**Keywords:** *Ayurveda, Marma, Phana Marma, Anosmia, Vaikalyakara Marma*

### INTRODUCTION

*Ayurveda*, the ancient science, deals with maintaining the good health and treatment of diseases. The *Marma sharir* is the part it deals with vital parts of body, the person should prevent these areas from injuries. In *Ayurveda*

it is included because in olden days during war injuries each person should have the knowledge of *Marma* to prevent vital parts from all type of injuries. *Acharya Sushrut* and *Vagbhata* mentioned 107 *Marmas* in all over body,

during different classifications of *Marma* both *Acharya Sushruta* and *Vagbhata* consider *Phana Marma* under *Vaikalyakara Marma* and *sira marma* (leads to loss of sense of smell) in *shaarirasthan*, located in *shiras pradesh* injury to this area leads to anosmia. During sport injuries especially in boxing, there is a chance to have injury to it, if injury occurs the person may have serious deformities. The *Phana* denotes snake hood, *Phana* part looks that of snake hood. Which is present inside the nasal cavity it opens from the both nostrils, these nostrils are the passage for *Phana marma*, which overcomes from the *Ghranasangnavaha srotas*. Loss of smell can be partial (hyposmia) or complete (anosmia), and may be temporary or permanent, depending on the cause. Although loss of smell is rarely a symptom of a serious condition, even a partial loss of smell could cause you to lose interest in eating, which could possibly lead to weight loss, malnutrition or even depression.

### Phana Marma:

According to *Sushruta* it is *sira marma* included in *Vaikalyakara marma*. Its *pramana* is *ardhanguli*, these are two in number.

*Ghranamargamubhayataha srotomarga pratibadhe abhyantarataha phane nama, tatra gandhaagnanam su sha 6/37*

As *Sushruta* told the *Phana marma* is present over inner side of the nasal cavity. According to *Astanga Hridaya*, on either side of the nostrils, adjoining the opening of the ears, inside the throat are the two *Phana marmas*. According to *Astanga Sangraha*, inner to throat, on either side of the *Ghranamarga* and in relation to part of *karna* is *Phana marma*. *Arunadatta*

*teekakara* told that the orifice of the auditory canal is present, by this it is known that the *Phana marma* is inner to *nasa* and above the *srotomarga*, this place is known as *nasaguha*. Above *nasaguha gandhanadi* (olfactory nerve) branches are present by this only sense of smell occurs.

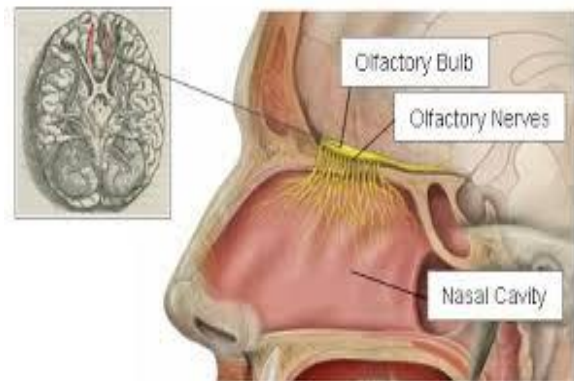
### UNDERLYING STRUCTURES:

Cribriform plate

Olfactory bulb

Olfactory nerve

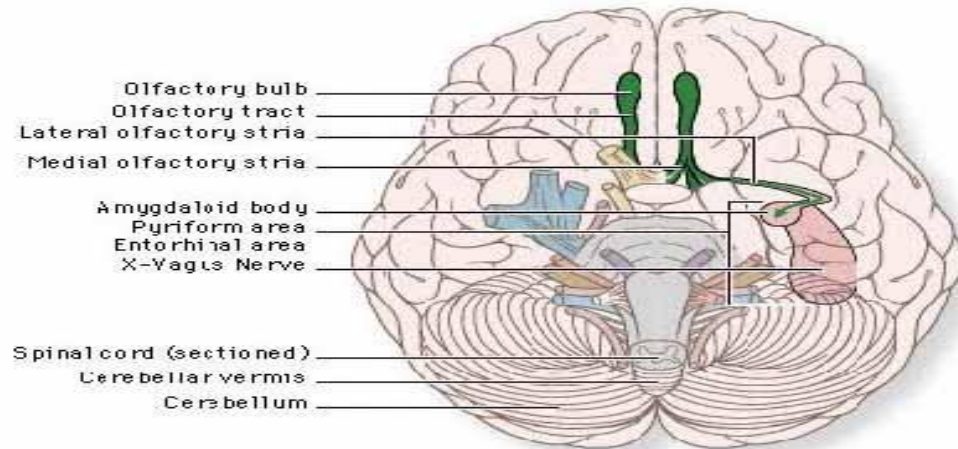
Spheno palatine branch of maxillary artery which is major blood supply to nasal olfactory mucosa in addition to anterior and posterior ethmoidal arteries.



**Figure 1:** Sagittal section of Nasal cavity showing olfactory bulb and nerve

### MATERIALS AND METHODOLOGY:

Literature of *Ayurvedic* and modern science available from *vedic* era to present era. Cadaver, dissection set, study conducted at department of *Rachana Sharir*, G J Patel *Ayurveda* College and Research center New Vallabha Vidya Nagar, Anand, Gujarat.



**Figure 2:** Basal aspect of the brain to show olfactory bulb

### OBSERVATION

*Phana marma* is located in the very interior of the nasal passes, specially on both sides of the nasal passes and attached with the nose as *Bahirsrotas*. *Srotomarga* cannot be considered as a term applied for auditory tube because it connects between the nasopharynx and the middle ear and has no relation with anosmia. *Srotomarga* also cannot lye internally. Thus *srotomarga* has been used by *Sushruta* for cribriform plate (naso cranial communications). *Sushruta* is of the opinion that the *Phana marma* is *sira* type of *marma*. Though nasal cavity is a prominent seat of hemorrhage yet it cannot be accepted as *sira marma* because olfactory nerve is the predominant structure in the formation of *marma*. Loss of smell can be partial (hyposmia) or complete (anosmia), and may be temporary or permanent, depending on the cause. Although loss of smell is rarely a symptom of a serious condition, even a partial loss of smell could cause you to lose interest in eating, which could possibly lead to weight loss, malnutrition or even depression. The un-

derlying structures are Cribriform plate, Olfactory bulb, Olfactory nerve, Spheno palatine

branch of maxillary artery which is major blood supply to nasal olfactory mucosa in addition to anterior and posterior ethmoidal arteries. In head injuries or sport injuries there will be involvement of olfactory nerve with this there may be involvement of ethmoidal arteries.

### DISCUSSION & CONCLUSION

*Phana Marma* is considered by both *Sushruta* and *Vagbhata* where it is classified under *Vaikalyakara marma* and *sira marma*. It is located in the very interior of the nasal passes, specially on both sides of the nasal passes and attached with the nose as *Bahirsrotas*. Injury at this *marma* leads to the disability referred as *gandha agyan* (Anosmia). Anatomically, study of this *marma* displays the fallowing facts:

1) Though the *Phana marma* is *sira marma*, regarding symptomatology *sira* has nothing to do with Anosmia

2) Anosmia is always because of involvement of olfactory nerve, better to consider *Phana marma* as *snayu marma* rather than *sira marma*.

3) Anatomical structures underlying this *marma* are credibly cribriform plate, olfactory nerve, and olfactory bulb.

4) *Srotomarga* is *bahirsrotomarga* related with the nose dealing with the sensation of smell.

In this heading “*Nasa hi siraso dwaram*” is also a quotable fact. If it is examined, it is found that cribriform plate may be referred for ‘*siraso dwara*’ as well as ‘*srotomarga*’. Olfactory nerve take origin from the mucous membrane of nasal cavity and they pass through the small openings in the cribriform plate and end in the olfactory bulb. Any injury inflicted on the anatomy of cribriform plate may damage the olfactory bulb or the olfactory nerve fibres resulting into loss of smell or anosmia (*gandha agyan*). This anatomy is also very internal anatomy which supplies the features of *abhyantara*. Olfactory bulb also resembles to the shape of snake hood (*Phana*). This may be the basis of the nomenclature of *marma*. Finally, the features of *Phana marma* as presented by *Sushruta* can be found relevant to the anatomical structures of described above.

## REFERENCES

1. B G Ghanekar (editor), *Sushrut Samhita Sharir sthana*, Chapter 6, verse no.37, page no. 198, Meharchand Lachhmandas Publications, New Delhi, 2007.
2. Bramhanand Tripathi (editor), *Astanga Hridaya, Sharirasthana* chapter 4, verse no.32, page no. 393, Chaukambha Sanskrit Pratisthan, New Delhi, 2011.
3. Elaine N. Marieb, Human Anatomy and Physiology, 6th edition, Dorling Kindersley India Pvt Ltd
4. Neeta V Kulkarni, Clinical anatomy, 2nd edition, Jaypee brothers medical publishers Pvt Ltd.
5. Anne Waugh, Editor. Ross and Wilson, Anatomy and Physiology in Health and illness, 10th edition, Churchill Livingstone publisher.
6. Susan Standring, Editor. Gray’s Anatomy, 48th edition, 2008, Churchill Livingstone, Elsevier publisher.

**Source of Support: Nil**  
**Conflict Of Interest: None Declared**

How to cite this URL: Channamallikarjun A Davergaon: Critical Review Of Phana Marma With Special Reference To Anosmia. International Ayurvedic Medical Journal {online} 2017 {cited October, 2017} Available from:  
[http://www.iamj.in/posts/images/upload/3953\\_3956.pdf](http://www.iamj.in/posts/images/upload/3953_3956.pdf)