

UNDERSTANDING OF URDHWA SHAKHAGAT "AVEDHYA" SIRI

Kadam Rupaji J¹, Pandit S.V²

M.D. Ph. D. (RachanaSharir), Associate professor,
M.D. Professor and H.O.D. (Rachana Sharir), B.V.D.U. College of Ayurved, Pune, Maharashtra,
India

Email: rupajik@gmail.com

ABSTRACT

Ayurved learners face number of controversial concepts in *Sharir* like *Srotas*, *Snayu*, *Sira*, *Kala* etc. which needs to be resolved. Among these, *Sira* is one of the important but controversial concepts. *Vedhan* of *Sira* (puncturing of veins) i.e. *Siravedhan* is one of the modalities in practice in the management of various diseases. *Sushruta* has mentioned specific sites for *Siravedhan* and sites for *Avedhya Sira*. *Vedhan* of *Avedhya Sira* leads to either grievous deformity or death. So as to avoid complications due to puncture of *Avedhya Sira*, their complete knowledge is essential. From conceptual study, it is observed that *Sira* can be correlated with the blood vessels and lymphatics. The sites of *Avedhya Sira* in *Urdhwa shakha* are identified by two methods, first with the help of information of *Marma* site and second by the meaning of specific name of the *Sira*. Then the identified site is correlated with the underlying structures at the particular location in terms of modern anatomy. Either the arteries, big veins or terminal part of specific superficial veins (with many tributaries) at that particular location are identified as underlying structures of particular *Sira* site. The present conceptual study confirms that, the *Urdhwa Shakhagat Sira* i.e. brachial artery and profunda brachi artery (arteries), axillary vein (larger veins) and terminal part of cephalic vein (terminal part of some specific veins having many tributaries) has to be considered as *Avedhya Sira* namely *Bahavi*, *Lohitaksha* and *Jaldhara* respectively.

Key words: *Avedhya Sira*, *Raktamokshana*, *Sira*, *Siravedhan*, *Urdhvasakha*.

INTRODUCTION

Ayurved learners face number of controversial concepts in *Sharir* like *Srotas*, *Snayu*, *Sira*, *Kala* etc. which needs to be resolved. Among

these, *Sira* is one of the important but controversial concepts. *Siravedhan* is one of the important modalities in practice in the

management of various diseases like *Grudhrasi*, *Unmad*, *Apasmar* etc¹. *Sushruta* has stated *Siravedhan* as a half (prime) the *Chikitsa* in *Shalyatantra* like *Basti* in *Kayachikitsa*².

However, nowadays, *Siravedhan* is rarely used in practice, may be due to lack of first hand information as well as inexperienced *Vaidyas* or due to lack of confidence. *Sushruta* has mentioned specific sites for *Siravedhan*³ as well as sites for *Avedhya Sira*⁴. *Vedhan* of *Avedhya Sira* leads to either grievous deformity or death.⁵ For the desired outcome in treatment and to avoid complications due to puncture of *Avedhya Sira*, complete and comprehensive knowledge of *Siravedhan* becomes prerequisite.

So, it becomes essential for *Siravedhan* knowledge to find out the anatomical structures to which one can label as an *Avedhya Sira*.

Hence, considering its importance a conceptual study was carried out to know underlying structure of sites of *Avedhya Sira* from *Urdhwa Shakha*.

Aim: To confirm anatomical structure of *Avedhya Sira* from *Urdhwa Shakha*

Table 1:

S.N.	AYURVEDA	MODERN
1	<i>Aruna (Vatavani)</i> Convey <i>Vata dosha</i> . Blackish red in colour. Minute, if pressed suddenly get emptied and after removing pressure suddenly fill.	Capillary Convey deoxygenated blood. Blackish red in appearance. Minute, if pressed instantaneously emptied and after removing pressure fills up.
2	<i>Neela (Pittavahi)</i> Convey <i>Pitta dosha</i> . Blue in appearance and are warm.	Vein Convey deoxygenated blood. Blue in appearance.
3	<i>Gauri (Kaphavahi)</i> Convey <i>Kapha dosha</i> . White in colour. Steady,	Lymph vessel Convey lymph. White or colourless. They are nutritive,

Objectives:

1. To confirm exact sites of *Urdhwa Shakhagat Avedhya Sira* in the light of modern anatomy
2. To correlate sites of *Urdhwa Shakhagat Avedhya Sira* with underlying anatomical structures

Materials:-

- 1) Literature: *Bhrihadtrayee*, Previous Research work
- 2) Modern Literature: Gray's Anatomy, B.D. Chaurasia's Human Anatomy etc.

Methodology:-

Literature study

- A. Correlation of *Sushrutokta Sira* with anatomical structure.
- B. Findings of anatomical location for *Urdhwa Shakhagat* sites of *Avedhya Sira* and their interpretation with underlying structure.

A. Correlation of *Sushrutokta Sira* with anatomical structure.

According to *Ayurveda*, *Sira* nourishes the body⁶ and as per the modern science, body is nourished by vessels.⁷

It can be observed easily from following table of comparison between *Sira* and vessels on the basis of their colour and types .^{8,9,10}

	sheet and nutritive.	cold and beaded.
4	Rohini (Raktavahi)	Artery
	Convey Suddha Rakta. Red in colour. Neither warm nor cold.	Convey oxygenated blood and nutritive. Red in appearance.

Hence we can correlate the *Sira* with the blood vessels and Lymphatics as follows:

1. *Aruna Sira* can be correlated with capillaries.
2. *Neela Sira* can be correlated with veins.
3. *Gauri Sira* can be correlated with lymph vessels.
4. *Rohini Sira* can be correlated with arteries.

B. Findings of anatomical location for *Urdhwa Shakhagat* sites of *Avedhya Sira* and their understanding with underlying structure.

The *Avedhya Sira in Urdhwa Shakha* is explained with following points.

- a. Sutra
- b. Translation in English
- c. Site with justification
- d. Structures at considered site
- e. Interpretation

i) **Sutra:** *Tatra sirashatmekasmin sakthi bhavati; tasam jaladhara tweka, tisrachyabhyantara: tatrourvisadnye dwe, lohitaakshasadya chaika, tastu avyadhyas; yetenetarsakthi bahu ch vyakhyatau; avamshstraakritya; shodash shakhasu*** Su. Sha. 7/22

ii) **Translation:** One hundred *Sira* are present in lower extremity; out of them, 1 *Jaladhara* and 3 located *Abhyantar* (deep) i.e. two *Urvi* and one *Lohitaksha* and the same scenario is seen in upper extremity. Thus total sixteen

Avedhya Sira are present in extremities which should not be punctured.¹¹

▪ **Jaladhara¹¹:** The meaning of word *Jala* is a net; as this *Sira* forms a network i.e. *Jala* so it is called as *Jaladhara*; which has been considered *Bahya* (superficial).

iv) **Structures at considered site:** The cephalic vein is found in form of network with its tributaries¹² which looks like *Jaladhara*.

When you puncture upper (terminal) part of cephalic vein, bleeding occurs more than puncturing at its lower part. It is obvious because terminal part of cephalic vein carries more blood than the distal part (upper part is broader than lower part). So it is harmful to puncture terminal part (just before the deltopectoral groove).

v) **Interpretation:** So terminal part (i.e. course of upper one third of cephalic vein before joining of axillary vein) in the arm can be considered as an *Avedhya Sira* i.e. *Jaladhara Sira*.

▪ **Urvi (Bahavi) Sira¹¹:**

Urvi is a *Sira Marma* present in lower extremity and its counterpart in upper extremity is named as *Bahavi*. An injury to this *Marma* causes bleeding³⁷. The blood loss leads to *Bahushosh* (deformity) and the uncontrolled bleeding leads to death.

iii) **Considered Site:** As *Bahavi* is *Sira Marma*, site of *Bahavi Marma* can be considered as site for *Bahavi Sira*. So as per modern anatomy, the centre of the line joining

head of humerus to the condyles of the humerus¹³ is considered as site of *Bahavi Marma* and that site is considered as the site of *Bahavi Sira*.

iv) Structures at considered site: *Sushruta* told that *Urvi (Bahavi) Sira* are 2 in numbers. If you see this site here we found two structures which are similar in function and structure and they are arteries which one is brachial artery¹⁴ and another is profunda brachi artery¹⁴.

v) Interpretation: So, here, we can consider brachial artery and profunda brachi arteries are two *Urvi (Bahavi) Sira* which are *Avedhya Sira*.

▪ **Lohitaksha Sira¹¹:**

Lohitaksha is a *Sira Marma* and injury to this *Marma* causes bleeding¹³. The blood loss leads to *Pakshaghat* (deformity) and the uncontrolled bleeding leads to death.

iii) Considered Site: As *Lohitaksha* is *Sira Marma*, hence site of *Lohitaksha Marma* can be considered as site of *Lohitaksha Sira* i.e. just below the *Kaksha Sandhi*.¹³ So, as per

modern anatomy, the centre of axilla which is just below the shoulder joint is considered site of *Lohitaksha Marma* and that site is considered as the site of *Lohitaksha Sira*.

iv) Structures at considered site: As per *Sushruta*, *Lohitaksha Sira* is 1 in number in each *Shakha*. Here (site of *Lohitaksha Marma*) we found axillary artery and axillary vein. Here we considered axillary vein¹⁵ as *Avedhya Sira* (we considered femoral vein in lower extremities as *Avedhya Sira* and *Sushruta* told its counterpart is same in upper extremities.)

v) Interpretation: So, here we can consider axillary vein is *Lohitaksha Sira* as an *Avedhya Sira*.

Observations:

The name and site of *Urdhwa shakhagat Avedya Sira* can be interpreted with the following anatomical structures listed in tables. Here, we have considered arteries, larger veins and terminal part of specific superficial veins having many tributaries as *Avedhya Sira*.

Table 2: *Urdvashakha - Avedhya Sira:*

<i>Sthan¹¹</i>	Name of <i>Sira¹¹</i>	<i>Sankhya¹¹</i>	Modern structure and Number
<i>Urdhwashakha</i> (8)	<i>Jaladhara</i>	1 (in each <i>Shakha</i>) x 2 = 2	Terminal part (near delto pectoral groove) of Cephalic vein ¹² (1+1)=2 See. Fig. No.-1
	<i>Urvi</i>	2 (in each <i>Shakha</i>) x 2 = 4	Brachial artery ¹⁴ (1+1) =2 + Profunda brachi artery ¹⁴ (1+1)=2 total= 4 See. Fig. No.-2
	<i>Lohitaksha</i>	1 (in each <i>Shakha</i>) x 2 = 2	Axillary vein ¹⁵ (1+1)=2 See. Fig. No.-1
		Total =8	Total =8

DISCUSSION

In this conceptual study, discussion regarding general interpretation of *Avedhya Sira* is

essential to know the underlying structure for *Urdhwa Shakhagat Avedhya Sira*.

➤ **Interpretation of Avedhya Sira:**

While *Siravedha*, *Sushruta* might have observed that puncture of some specific structures cause deformity or death. Such structures were categorized under *Avedhya Sira*. Because of this, *Sushruta* has given more importance to the *Avedhya Sira* than the *Vedhya Sira*. So *Sushruta* might have mentioned exact number of *Avedhya Sira* only with its name and site.

Avedhya Sira means the vessels which are not to be punctured or cut. As after puncturing these vessels it may lead to either deformity or death. Some of the causes of deformity or death are -

- Since, the arterial pressure is more than venous pressure;¹⁶ there is risk of heavy and profuse bleeding in puncturing artery which may lead to deformity or death.
- Nutrition of the body is carried out by arterial supply. If artery is damaged then the part supplied by it will not be nourished well and deformity may occur¹⁷.
- When terminal part of some specific veins (great saphenous and cephalic vein) with many tributaries and larger veins are punctured, there is possibility of profuse bleeding which may leads to either deformity or death.

Thus we have considered *Avedhya Sira* as arteries, larger veins (e.g. femoral vein and axillary vein) and terminal part of some specific veins (great saphenous and cephalic vein) having many tributaries.

Above understanding is also supported by one of the previous studies of Dr. D.S. Shelake.¹⁸ He considered arteries (femoral, axillary and brachial arteries) and larger veins (femoral and axillary veins) as *Avedhya Sira*. But there is

difference in opinion about consideration of great saphenous and cephalic vein as *Avedhya Sira*. In our study, only terminal part of these veins is considered as an *Avedhya Sira* but Dr. Shelake considered entire vein as an *Avedhya Sira*.

4. Role of *Marma sthan* in confirmation of sites of *Avedhya Sira*:

Most of the names of *Avedhya Sira* are as per the names of *Marma* present at particular site and vice versa most of the sites of *Avedhya Sira* are at *Marma sthan*. E.g. *Lohitaksha*, *Urvi*, *Neela*, *Manya*, *Bruhati* etc.¹⁹

In this study, *sthana* of various *Marma* are considered for confirmation of exact site of *Avedhya Sira*.

CONCLUSION

This conceptual study confirms that, the *Avedhya Sira* of *Urdhwa Shakha* are the arteries, larger veins and terminal part of specific superficial veins having many tributaries at that particular sites, as follows-

- 1) *Bahavi Sira* is brachial artery and profunda brachi artery (arteries).
- 2) *Lohitaksha Sira* is axillary vein (larger veins).
- 3) *Jaladhara Sira* is a terminal part of cephalic vein (terminal parts of some specific superficial veins having many tributaries)

Acknowledgement: We are thankful to Bharati Vidyapeeth Deemed University, Principal- B.V.D.U. College of Ayurved, Pune.for their support to promote us.

Fig 1: Veins of Right Upper Extremity

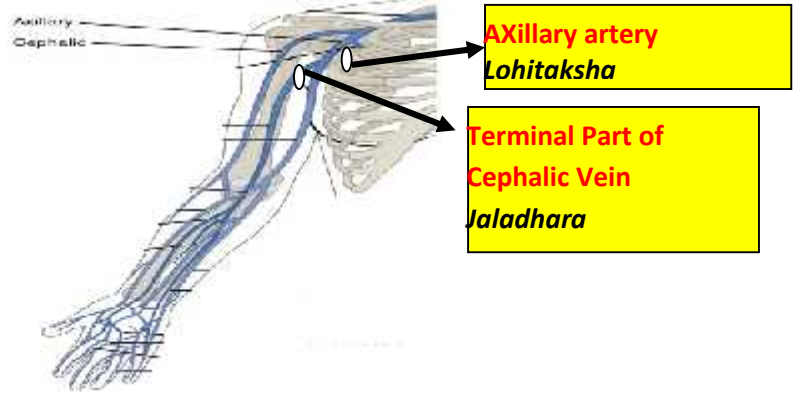
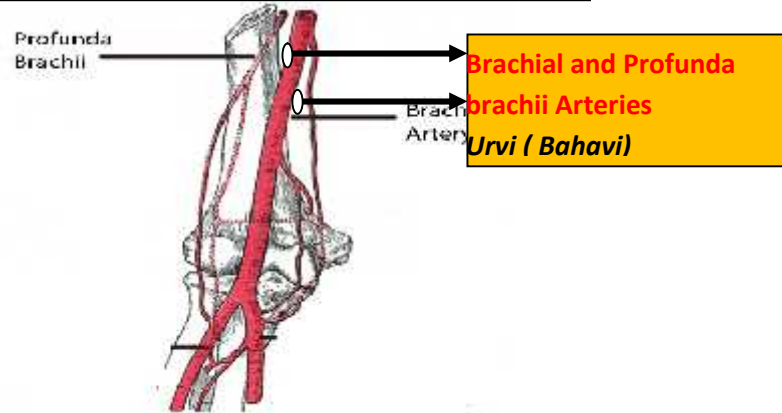


Fig. 2. Right Upper Extremity (Brachial artery)



REFERENCES

1. Yadavaji Trikamji Acharya, (reprint, 2013) Sushruta Samhita 'commentary of Shri Dalhanacharya, Chowkhamba Sanskrit Sansthan, Varanasi, Sharir Sthan chapter-8, verse-17. Pg.381
2. Yadavaji Trikamji Acharya, (reprint, 2013) Sushruta Samhita 'commentary of Shri Dalhanacharya, 'Chokhamba Sanskrit Sansthan, Varanasi, Sharir Sthan chapter-8, verse- 23. Pg.383.
3. Yadavaji Trikamji Acharya, (reprint, 2013) Sushruta Samhita 'commentary of Shri Dalhanacharya, Chowkhamba Sanskrit Sansthan, Varanasi, Sharir Sthan chapter-8, verse-17. Pg.381.
4. Yadavaji Trikamji Acharya, (reprint, 2013) Sushruta Samhita 'commentary of Shri Dalhanacharya, Chowkhamba Sanskrit Sansthan, Varanasi, Sharir Sthan chapter-7, verse-22. Pg.378.
5. Yadavaji Trikamji Acharya, (reprint, 2013) Sushruta Samhita 'commentary of Shri

- Dalhanacharya, Chowkhamba Sanskrit Sansthan, Varanasi, Sharir Sthan chapter-7, verse-19. Pg.377.
6. Yadavaji Trikamji Acharya, (reprint, 2013) Sushruta Samhita 'commentary of Shri Dalhanacharya, Chowkhamba Sanskrit Sansthan, Varanasi, Sharir Sthan chapter-7, verse-3. Pg.376.
 7. Susan Standring, (40th edition, 2008), Gray's Anatomy, Churchill Livingstone Elsevier- London, chapter- 6, Pg-130
 8. <http://scienceline.ucsb.edu/getkey.php?key=2927>
 9. http://www.answers.com/Q/What_color_are_capillaries (Visited on 15/3/2016)
 10. Susan Standring, (40th edition, 2008), Gray's Anatomy, Churchill Livingstone Elsevier- London, chapter- 6, Pg-139
 11. Yadavaji Trikamji Acharya, (reprint, 2013) Sushruta Samhita 'commentary of Shri Dalhanacharya, Chowkhamba Sanskrit Sansthan, Varanasi, Sharir Sthan chapter-7, verse-22. Pg.378.
 12. B.D.Chourasia, (4th edition 2004, reprinted 2005), Human Anatomy vol.1, CBS Publishers & distributors New Delhi, chapter 6 Pg- 70-71.
 13. Yadavaji Trikamji Acharya, (reprint, 2013) Sushruta Samhita 'commentary of Shri Dalhanacharya, Chowkhamba Sanskrit Sansthan, Varanasi, Sharir Sthan chapter-6, verse-24. Pg.372, 373.
 14. Susan Standring, (40th edition, 2008), Gray's Anatomy, Churchill Livingstone Elsevier- London, chapter- 80, Pg- 1381.
 15. Susan Standring, (40th edition, 2008), Gray's Anatomy, Churchill Livingstone Elsevier- London, chapter- 46, Pg- 817.
 16. Gerardi Tortora and Sandra Reynolds Grabowski, (edition- 8th), Principles of Anatomy and Physiology, House- Harper Collins College, chapter- 21, Pg- 616
 17. Gerardi Tortora and Sandra Reynolds Grabowski, (edition- 8th), Principles of Anatomy and Physiology, House- Harper Collins College, chapter- 21, Pg- 614
 18. Shelake D.S., (1994), "Anatomical location of Shakhasthita Avedhya Siras with special reference to Lohitaksha & Aurvi Sira", M.D Dissertation, Marathwada University, Pg.45
 19. Yadavaji Trikamji Acharya, (reprint, 2013) Sushruta Samhita 'commentary of Shri Dalhanacharya, Chowkhamba Sanskrit Sansthan, Varanasi, Sharirsthan chapter- 7, verse-22. Pg.378.

Source of Support: Nil

Conflict Of Interest: None Declared

How to cite this URL: Kadam Rupaji J & Pandit S.V: Understanding Of Urdhwa Shakhagat "Avedhya" Sira. International Ayurvedic Medical Journal {online} 2017 {cited June, 2017} Available from: http://www.iamj.in/posts/images/upload/2035_2041.pdf